

# The University of New Mexico Orthopaedics Research Journal 2017



# The University of New Mexico Orthopaedics Research Journal 2017



**Volume VI**

Published by the Regents of The University of New Mexico  
All rights revert to author(s) upon publication  
ISSN 2167-4760

Department of Orthopaedics & Rehabilitation  
The University of New Mexico  
MSC10 5600  
1 University of New Mexico  
Albuquerque, NM 87131  
505.272.4107

Printed by Starline Printing  
7111 Pan American West Freeway N.E.  
Albuquerque, NM 87109  
505.345.8900  
[www.starlineprinting.com](http://www.starlineprinting.com)

### Co-Editors

Deana Mercer MD  
Christina Salas PhD

### Managing Editor

Joni Roberts BBA C-TAGME

### Copy Editor

Sahar Freedman BA

### Layout Editor

Melanie DeLorenzo BA

### With thanks to

Gail Case  
Amy Dunlap  
Lauren Long  
Joy Van Meter

Sandia Orthopaedic Alumni Society (SOAS) provides services that enhance and enrich the educational experience of current residents and fellows in orthopaedics training at UNM. With more than 40 years of alumni to call on, SOAS is a vital and dynamic contributor to the program. We thank them for their generous support of *The University of New Mexico Orthopaedics Research Journal*.

The Co-Editors and editorial team of *The University of New Mexico Orthopaedics Research Journal* express sincere thanks to the following reviewers, whose volunteered time and efforts made our first peer-reviewed volume transition from an idea into reality. We are excited to move forward in our path toward official indexing in PubMed.

Thank you all.

Adam Adler, MD	Moheb Moneim, MD
Eric Benson, MD	Patrick Mulkey, MD
Jenni Buckley, PhD	Jorge Orbay, MD
Shane Cass, DO	John Phillips, MD
Tahseen Cheema, MD	Jeffrey Racca, MD
James Clark, MD	Dustin Richter, MD
Thomas DeCoster, MD	John Ruth, MD
Rebecca Dutton, MD	Andrew Schannen, MD
Fabio Figueiredo, MD	Jordan Smith, MD
David Grow, PhD	Daniel Stewart, MD
Daniel Hoopes, MD	Mahmoud Reda Taha, PhD
Andrea Lese, MD	Ahmed Thabet-Hagag, MD
James Love, MS	Lauren Vernon, PhD
Christopher McGrew, MD	Jason Wild, MD

## CALL FOR SUBMISSIONS

*The University of New Mexico Orthopaedics Research Journal*

*2018; Volume 7*

**Deadline: Sunday, January 7th, 2018**

- Peer-reviewed, annual publication of The University of New Mexico Department of Orthopaedics & Rehabilitation
- Open-access; no submission or publication fees
- Goal of MEDLINE indexing
- Highlights articles relevant to orthopaedic-focused surgery and engineering: *clinical and basic-science original research, case reports, reviews, technical notes, new technology, pilot studies, brief reports education articles, and reflections*

Email your Title Page, Blinded Manuscript, Figures, Figure Legends,  
and Tables to [UNMORJ@salud.unm.edu](mailto:UNMORJ@salud.unm.edu)

ISSN 2167-4760



# INSTRUCTIONS FOR AUTHORS

## *The University of New Mexico Orthopaedics Research Journal*

*The University of New Mexico Orthopaedics Research Journal (UNMORJ)* is a peer-reviewed (double blinded) publication of UNM Department of Orthopaedics & Rehabilitation. *UNMORJ* highlights original research relevant to orthopaedic-focused surgery and engineering, with the goal of MEDLINE indexing.

Submit manuscripts for consideration in the 7th volume of *UNMORJ* to [UNMORJ@salud.unm.edu](mailto:UNMORJ@salud.unm.edu) by **Sunday, January 7, 2018**. Email questions to Sahar Freedman, Copy Editor ([SaharF@salud.unm.edu](mailto:SaharF@salud.unm.edu)).

Email the Title Page, Blinded Manuscript, each table, and each figure as separate files. Instructions below.

**General Formatting** Title Pages and Blinded Manuscripts must be submitted as Microsoft Word documents. *UNMORJ* follows the style and format of the *AMA Manual of Style* (10th ed). Use Times New Roman, 12-point typeface and 1-inch margins. Use continuous line numbering, continuous page numbering in the upper-right corner, and double spacing (including in the references list and tables). Spell out numbers <10 except measurement values (eg, “4 days”). Present measurements in SI metric units.

**Title Page** List the title, authors’ names in the desired order of appearance, highest academic degree, associated affiliations, and any changed affiliations. Designate the corresponding author and email address. Include statements of 1) funding, 2) conflict of interest, 3) informed patient consent, and 4) if applicable, the institutional review board approval and associated number.

**Blinded Manuscript** Excluding the references, abstract, tables, and figure legends, we will accept ≤3200 words for reviews; ≤2500 for scientific articles, pilot studies, and education articles; ≤1200 for case reports, technical notes, new technology, and brief reports; and ≤1000 for reflections. Headings of scientific articles: Abstract, Introduction, Methods, Results, Discussion, References, Figure Legends. For case reports, use Abstract, Introduction, Case Report, Discussion, References, and Figure Legends.

**Abstract** Total of 250 words for scientific articles and education articles, with four paragraphs: Background, Methods, Results, Conclusions. For case reports, technical notes, new technology, pilot studies, and brief reports, total of 150 words (250 for reviews) in an unstructured paragraph format.

**References** List in order of appearance (not alphabetically) and present in the text by superscript numbers. Format all references in *AMA Manual of Style* (10th ed). *All references must be cited in the text.*

**Tables/Figures** Place each table on a separate Word document. Create tables using only the Word table function. Number each table and include a title. Remove any images from the text, and save each one separately in 300 DPI as an EPS, TIFF, PPT, or JPEG file. Provide a brief legend for each figure in the last page of the Blinded Manuscript. When submitting an image that was published elsewhere, provide information about the obtained permission. *All figures and tables must be cited in the text.*

**Submission** Email all submission files to [UNMORJ@salud.unm.edu](mailto:UNMORJ@salud.unm.edu).

Manuscripts will be warmly received from faculty, fellows, residents, alumni, and colleagues. Thank you for considering *UNMORJ* as an avenue to feature your research.

# Table of Contents

xi	Faculty
xiv	Mid-level Providers
xv	Fellows and Chiefs
xvi	Residents
xviii	Physical Therapy Faculty
xix	Division of Research
1	Letter from the Chair
3	Letter from the Co-Editors
5	Letter from the Chief of the Division of Physical Therapy
6	Letter from the Residency Director
7	Chief Articles
7	Value-Based Bundled Repayment in Total Joint Arthroplasty <i>Michael M. Decker, MD</i>
12	Total Ankle Replacement, Then and Now: A Review <i>Katherine J. Gavin, MD</i>
18	Performance-Enhancing Drugs: A Review <i>G. Keith Gill, MD</i>
25	Elbow Injuries in the Throwing Athlete: A Review <i>Drew K. Newhoff, MD</i>
30	Current Issues in Treatment of Anterior Shoulder Instability: A Review <i>Ian Power, MD</i>
37	Review Article
37	Antegrade Nailing of Femur Shaft Fractures: A Review <i>Thomas A. DeCoster, MD; Shahram Bozorgnia, MD; Samer Kakish, MD, FRCS</i>





## 46 Scientific Articles

- 46 Radiographic and Clinical Evaluation of Syndesmotic Screws in Treating Injuries of the Distal Aspect of the Tibiofibular Syndesmosis  
*James A. Dollahite, MD; Paul J. Goodwyn, MD; Katherine J. Gavin, MD; Richard A. Miller, MD*
- 52 Lateral Versus Dorsal Plating for Treating Metacarpal and Phalanx Fractures: A Retrospective Cohort Study  
*Joshua W. Hustedt, MD, MHS; Collin C. Barber, MD; Michael Bonnelly, BS; Lloyd P. Champagne, MD*
- 58 Hierarchical Modeling Versus Regression Analysis for Evaluating Results of Orthopaedic Studies That Use the National Inpatient Sample  
*Joshua W. Hustedt, MD, MHS; Kade McQuivey, BS; John C. Hustedt, MPH*
- 71 Determining Frequency and Defining the Patient Profile of Sacral Insufficiency Fractures  
*Blake Obrock, DO; Jeremy Wearn, MD; Matthew L. DeHart, MD; Paxton Gehling, BM; Amer M. Mirza, MD*
- 77 Radiographic Prevalence of Osteoarthritis of the Scaphotrapezotrapezoid Joint in Patients With Carpometacarpal Osteoarthritis of the Thumb: A Retrospective Case Series  
*Charlotte E. Orr, MD; Robert Mercer, BS; Deana M. Mercer, MD; Drew K. Newhoff, MD; Matthew D. Martin, MD; Moheb S. Moneim, MD*
- 81 External Fixation for Treating Tibial Shaft Fractures Using a Triangular Two-Planar Frame: A Computational and Biomechanical Study  
*Christina Salas, PhD; Daniel Hoopes, MD; Mahmoud M. Reda Taha, PhD; Thomas A. DeCoster MD*

## 91 Education Articles

- 91 Evaluation of Content and Accessibility of Orthopaedic Trauma Fellowship Websites  
*Travis M. Hughes, BS; Bobby Dezfuli, MD; Kimberly J. Franke, MD; Jordan L. Smith MD; John T. Ruth, MD*
- 97 Suturing Workshop for Third-Year Medical Students: A Modern Educational Approach  
*Mary E. Logue, BS; Ryan D. Lurtsema, BS; Yuridia Leyva, BS; Tyler J. Hough, BS; Kelly M. Harrington, BS; Deana M. Mercer, MD*
- 102 Intradepartmental System of Allocating Operating Room Block Time and its Financial Impact at The University of New Mexico Department of Orthopaedics & Rehabilitation: A Preliminary Report  
*Dustin L. Richter, MD; Gail Case; Nicholas White; Mary A. Jacintha; Robert C. Schenck Jr, MD*

- 106 Understanding Radiocarpal Rotation Through In Vivo Pronation and Supination of the Hand: A Single Case Study  
*Jorge L. Orbay, MD; Joshua M. Romero, BS; Neal Wostbrock, BS; Deana M. Mercer, MD*

## 110 New Technology

- 110 3D Bioprinter + Electrospinner for Bone-Ligament Tissue Engineering  
*Sherif H. Aboubakr, MS; Steven Nery, BS; Lauren Long, BS; Christopher A. Buksa, BS; Chanju Fritch, BS; Christina Salas, PhD*
- 117 Automated Device to Enable Passive Pronation and Supination Activities of the Hand for Experimental Testing with Cadaveric Specimens: A Collaboration Between The University of New Mexico and New Mexico Institute of Mining and Technology  
*Jodie Gomez, BS; Jakub Mroczkowski, BS; Lauren Long, BS; Christopher A. Buksa, BS; Deana M. Mercer, MD; Christina Salas, PhD; David I. Grow, PhD*

## 124 Pilot Study

- 124 Pilot Study Investigating the Use of 3D Printing in Designing Upper-Extremity Prosthetics for Children: A Progress Report  
*Lauren Long, BS; Christina Salas, PhD; Deana M. Mercer, MD; Selina R. Silva, MD; Jared Knigge*

## 129 Case Reports

- 129 Missed Early Glenohumeral Septic Arthritis During Emergency Department Visit Owing to Low Virulence Streptococcus Mitis: A Case Report  
*Ashley A. Crum, MD; Christopher A. McGrew, MD; Matthew A. Tennison, MD*
- 133 Carpal Tunnel Release During Pregnancy: Report of Two Cases  
*Erica J. Gauger, MD; Deana M. Mercer, MD; Moheb S. Moneim, MD*
- 136 Posttraumatic Attenuation of the Lisfranc Ligament in a 14-Year-Old Athlete: A Case Report  
*Paul J. Johnson, MD; David M. Bennett, MD*
- 140 Capitate Stress Injuries of Both Wrists in an Adolescent Female Gymnast: A Case Report  
*Brynne R. W. Latterell, MPH; Deana M. Mercer, MD; Shane P. Cass, DO; Christopher A. McGrew, MD*
- 143 Transhumeral Amputation for Treating Necrotizing Fasciitis Infection of the Upper Extremity: Report of Two Cases  
*Drew K. Newhoff, MD; Amber L. Price, MD; Christina Salas, PhD; Deana M. Mercer, MD*

- 148 Sciatic Nerve Palsy After Operative Treatment of Subtrochanteric Femur Fracture Resulting from Postoperative Hematoma: A Case Report  
*Tony G. Pedri, MD; Gehron P. Treme, MD*
- 151 A New Diagnosis of Multiple Sclerosis in a 29-Year-Old Former Collegiate Basketball Player With Initial Symptoms of Recurrent Bell's Palsy: A Case Report  
*Eric R. Reynolds, MD, Andrew D. Ashbaugh, DO; Christopher A. McGrew, MD*
- 155 Lipoma of the Tendon Sheath Causing Symptoms of de Quervain's Tenosynovitis: A Case Report  
*James Rose, MD; Moheb S. Moneim, MD*
- 158 Diagnosing an Acute Quadratus Plantae Tear in a 37-Year-Old Athlete: A Case Report  
*James P. Toldi, DO; Shane P. Cass, DO; Richard A. Miller, MD; Christopher A. McGrew, MD*
- 162 Unsuccessful Metatarsophalangeal Joint Replacement for Treating Arthritis of the Great Toe: Report of Three Cases  
*Jory Wasserburger, MD; Paul J. Johnson, MD; Katherine J. Gavin, MD; Richard A. Miller, MD*
- 166 Rare Tumors Adjacent to the Achilles Tendon: Report of Two Cases  
*Jay J. Wojcik, MD; Aditi S. Majumdar, MD; Kathleen M. Madden, MD; Richard A. Miller, MD*

## 170 Reflections

- 170 Preparing Resident Physicians for Healthcare Reform  
*Michael M. Decker, MD*
- 172 Hosting the Perry Outreach Program and Medical Student Outreach Program in Albuquerque: Promoting Women Leaders in Engineering and Orthopaedic Surgery  
*Lauren Long, BS; Sahar Freedman, BA; Jodie Gomez, BS; Deana M. Mercer, MD; Christina Salas, PhD*
- 175 The Albuquerque Community Sports Medicine Experience: Four Decades and Counting  
*Christopher A. McGrew, MD; Thomas A. DeCoster, MD; Shane P. Cass, DO; Richard Gerrells, BS, ATC; Edward R. Sweetser, MD*
- 178 Remembrances: Orthopaedics Throughout the Years (1980s–Present)  
*Richard A. Miller, MD*
- 182 Novel Strategies for Time Efficiency in an Orthopaedic Clinic: A Satire  
*Christopher L. Shultz, MD; Richard A. Miller, MD*
- 185 Taking an Orthopaedic Sabbatical: *Mon Année en Lyon*  
*Daniel C. Wascher, MD*

## 188 Alumni Map



# Faculty



**Attlee Benally DPM**—Assistant Professor  
 Medical Degree: California College of Podiatric Medicine  
 Post Medical School: Jerry L Pettis Memorial Veterans Hospital; St Joseph’s Hospital  
 Fellowship: None  
 Clinical Expertise: Podiatry



**David Chafey MD**—Assistant Professor  
 Medical Degree: Ponce School of Medicine  
 Residency: Baylor College of Medicine  
 Fellowship: Orthopaedic Trauma, Sonoran Orthopaedic Trauma Surgeons; Musculoskeletal Oncology, The University of Texas at Houston  
 Clinical Expertise: Limb Salvage, Pelvic Reconstruction, Metastatic Disease to Bone



**David Bennett MD**—Assistant Professor  
 Medical Degree: Howard University  
 Residency: University of Arizona  
 Fellowships: Pediatric Orthopaedics, University of Utah  
 Clinical Expertise: Pediatric Spine, Deformity and Trauma



**Tahseen Cheema MD**—Professor  
 Medical Degree: Nishtar Medical College  
 Residency: The University of Medicine and Dentistry of New Jersey  
 Fellowship: Hand and Microsurgery, Rush University Medical Center  
 Clinical Expertise: Hand and Microsurgery



**Eric Benson MD**—Associate Professor  
 Medical Degree: Georgetown University  
 Residency: The University of New Mexico  
 Fellowship: Shoulder, Elbow and Hand, University of Western Ontario  
 Clinical Expertise: Shoulder and Elbow Arthroscopy, Reconstruction, and Trauma



**Haywan Chiu DPM**—Assistant Professor  
 Medical Degree: Temple University School of Podiatric Medicine  
 Residency: DVA Palo Alto  
 Fellowship: None  
 Clinical Expertise: Limb Salvage, Forefoot and Rearfoot Reconstruction



**Brandee Black MD**—Assistant Professor  
 Medical Degree: Michigan State University,  
 Residency: University of Missouri,  
 Fellowship: Sports Medicine, The University of New Mexico  
 Clinical Expertise: Sports Medicine, Arthroscopic Knee and Shoulder Surgery



**Thomas DeCoster MD**—Professor Emeritus;  
 Chief, Division of Orthopaedic Trauma, Assistant Team Physician, UNM Lobos;  
 Orthopaedic Trauma Fellowship Program Director  
 Medical Degree: University of Missouri  
 Residency: University of Vermont  
 Fellowship: Trauma and Sports Medicine, University of Iowa  
 Clinical Expertise: Musculoskeletal Trauma, Sports Medicine, Fractures



**Dustin Briggs MD**—Assistant Professor  
 Medical Degree: University of Iowa  
 Residency: The University of New Mexico  
 Fellowship: Lower Extremity Reconstruction, Scripps Clinic La Jolla  
 Clinical Expertise: Adult Reconstruction



**Rebecca Dutton MD**—Assistant Professor  
 Medical Degree: University of California-San Francisco  
 Residency: Stanford  
 Fellowship: Sports Medicine, Stanford  
 Clinical Expertise: Non-Operative Treatment Strategies for Musculoskeletal Injury, Musculoskeletal Ultrasound, Electrodiagnosis

# Faculty



**Paul Echols MD**—Professor Emeritus; Chief, Division of General Orthopaedic Surgery  
Medical Degree: University of Texas Medical Branch  
Residency: The University of New Mexico  
Fellowship: None  
Clinical Expertise: General Orthopaedic Surgery



**Christopher McGrew MD**—Professor; Program Director, Family Medicine Sports Medicine Fellowship  
Medical Degree: Louisiana State University  
Residency: Louisiana State University  
Fellowship: Primary Care Sports Medicine, Michigan State University  
Clinical Expertise: Primary Care Sports Medicine



**Rick Gehlert MD**—Professor  
Medical Degree: University of Maryland  
Residency: Ohio State University  
Fellowship: Orthopaedic Trauma, University of Pittsburgh  
Clinical Expertise: Orthopaedic Trauma



**Deana Mercer MD**—Associate Professor; Program Director, Hand Surgery Fellowship  
Medical Degree: The University of New Mexico  
Residency: The University of New Mexico  
Fellowship: Shoulder and Elbow Surgery, University of Washington; Hand Surgery, The University of New Mexico  
Clinical Expertise: Hand and Upper Extremity



**Christopher Hanosh MD**—Assistant Professor  
Medical Degree: Johns Hopkins University  
Residency: The University of New Mexico  
Fellowship: Reconstruction, Arizona Institute for Bone and Joint Disorders  
Clinical Expertise: Upper Extremity and Joints



**Elizabeth Mikola MD**—Professor; Chief, Division of Hand Surgery  
Medical Degree: University of Missouri-Kansas City  
Residency: University of Texas at Houston  
Fellowship: Hand Surgery, The University of New Mexico  
Clinical Expertise: Hand Surgery



**Antony Kallur MD**—Assistant Professor  
Medical Degree: University of Calicut  
Residency: Mahatma Gandhi University  
Fellowship: Spine, Hospital for Special Surgery; Orthopaedic Pediatric Surgery, Dupont Hospital for Children  
Clinical Expertise: Spine and Pediatric Trauma, Adult and Pediatric Spine Deformity



**Richard Miller MD**—Professor; Chief, Division of Foot and Ankle Surgery  
Medical Degree: University of California-Los Angeles  
Residency: The University of New Mexico  
Fellowship: Foot and Ankle, Oakland Bone & Joint Specialists  
Clinical Expertise: Injuries and Reconstructive Surgery of the Foot and Ankle



**Eric Lew DPM**—Assistant Professor  
Medical Degree: College of Podiatric Medicine and Surgery  
Residency: Cleveland Clinic-Kaiser Permanente  
Fellowship: Southern Arizona Limb Salvage Alliance, University of Arizona  
Clinical Expertise: Injuries and Reconstructive Surgery of the Foot and Ankle



**Urvij Modhia MD**—Assistant Professor  
Medical Degree: BJ Medical College  
Residency: Smt NHL Municipal Medical College  
Fellowship: Orthopaedic Spine Surgery, University of California-San Francisco; Orthopaedic Trauma, The University of New Mexico; Pediatric Orthopaedics, Johns Hopkins University  
Clinical Expertise: Spine and Trauma

# Faculty



**Moheb Moneim MD**—Professor;  
Chair Emeritus  
Medical Degree: Cairo University  
Residency: Duke University  
Fellowship: Hand Surgery, Hospital for  
Special Surgery, Cornell University  
Clinical Expertise: Hand Surgery



**Frederick Sherman MD**—Professor  
Emeritus  
Medical Degree: Yale University School of  
Medicine  
Residency: San Francisco Orthopaedics  
Residency Training Program  
Fellowship: Pediatric Orthopaedics, Shriners  
Hospital; Pediatric Orthopaedics, Children's  
Hospital Medical Center, Boston, MA  
Clinical Expertise: Pediatric Orthopaedics



**Andrew Paterson MD**—Associate Professor  
Medical Degree: University of Louisville  
Residency: University of New Mexico  
Fellowship: Orthopaedic Spine Surgery,  
Panorama Orthopaedics  
Clinical Expertise: Spine



**Selina Silva MD**—Assistant Professor;  
Interim Medical Director, Carrie Tingley  
Hospital  
Medical Degree: University of Colorado-  
Boulder  
Residency: The University of New Mexico  
Fellowship: Pediatric Orthopaedic Surgery,  
University of Michigan  
Clinical Expertise: Hip Dysplasia, Scoliosis,  
Limb Deformities



**Dustin Richter MD**—Assistant Professor  
Medical Degree: University of New Mexico  
Residency: University of New Mexico  
Fellowship: Orthopaedic Sports Medicine,  
University of Virginia  
Clinical Expertise: Knee, Hip, and Shoulder  
Arthroplasty



**Gehron Treme MD**—Associate Professor;  
Director, Orthopaedic Surgery Residency  
Program  
Medical Degree: Louisiana State University  
Residency: The University of New Mexico  
Fellowship: Sports Medicine, University of  
Virginia  
Clinical Expertise: Knee and Shoulder  
Arthroplasty



**Christina Salas PhD**—Assistant Professor  
Doctoral Degree: University of New Mexico  
Focus: Biomedical Engineering  
PhD Traineeship: University of California,  
San Francisco; Mayo Clinic, Rochester, MN  
Research Emphasis: Orthopaedic  
Biomechanics and Biomaterials



**Andrew Veitch MD**—Associate Professor;  
Chief of Sports Medicine Division; Team  
Physician, UNM Lobos  
Medical Degree: University of New Mexico  
School of Medicine  
Residency: University of New Mexico  
Fellowship: Sports Medicine, University of  
California-Los Angeles  
Clinical Expertise: Sports Medicine



**Robert Schenck Jr MD**—Professor;  
Chairman  
Medical Degree: Johns Hopkins University  
Residency: Johns Hopkins University  
Fellowship: Foot and Ankle Surgery, Boise,  
ID; Sports Medicine, Cincinnati Sports  
Medicine and Orthopaedic Center  
Clinical Expertise: Sports Medicine



**Daniel Wascher MD**—Professor;  
Orthopaedic Sports Medicine Fellowship  
Program Director  
Medical Degree: Saint Louis University  
Residency: University of Rochester  
Fellowship: Orthopaedic Sports Medicine,  
University of California-Los Angeles  
Clinical Expertise: Sports Medicine,  
Arthroscopy, Knee and Shoulder  
Reconstruction

# Mid-level Providers



Keri Clapper MSN ACNP-BC



Jamie Cloyes CPNP



Michelle Merrett PA-C



Suki Pierce PA-C



Amber West PA-C

## Fellows



**Erica Gauger MD**  
Medical School: University of Minnesota  
Residency: University of Minnesota  
Practice: Health Partners Medical Group/  
Regions Hospital



**Samer Kakish MD**  
Medical School: Jordan University of Science  
& Technology  
Residency: Royal College of Surgeons of  
Ireland  
Practice: The University of New Mexico



**Matthew Lilley MD**  
Medical School: University of Southern  
California  
Residency: University of California-San  
Francisco  
Practice: The Center Orthopedic &  
Neurosurgical Care & Research



**Blake Obrock DO**  
Medical School: Midwestern University  
Residency: Good Samaritan Medical Center  
Practice: Northwest Texas Healthcare



**James Rose MD**  
Medical School: University of Colorado-  
Denver  
Residency: Louisiana State University  
Practice: Western Orthopaedics and Sports  
Medicine

## Chiefs



**Michael Decker MD**  
Medical School: University of Illinois  
Fellowship: Adult Hip and Knee  
Reconstruction Surgery, Western University-  
Ontario



**Katherine Gavin MD**  
Medical School: Medical College of Wisconsin  
Fellowship: Foot and Ankle, Rush University



**G. Keith Gill MD**  
Medical School: Texas Tech University  
Fellowship: Sports Medicine, University of  
Virginia



**Drew Newhoff MD**  
Medical School: University of Iowa  
Fellowship: Hand Surgery, University of  
Colorado-Denver



**Ian Power MD**  
Medical School: The University of New  
Mexico  
Fellowship: Sports Medicine, University of  
Tennessee Campbell Clinic



## Residents: PGY One



**Scott Plaster MD**  
University of Oklahoma



**Jordan Polander MD**  
Louisiana State University-Shreveport



**Amber Price MD**  
Creighton University



**Jory Wasserburger MD**  
University of Washington



**Matthew Wharton MD**  
University of Arizona

## Residents: PGY Two



**Paul Goodwyn MD**  
SUNY Upstate Medical University



**Travis Hughes MD**  
University of Arizona



**Aditi Majumdar MD**  
The University of New Mexico



**Andrew Parsons MD**  
University of Oklahoma



**Christopher Shultz MD**  
University of Arizona

## Residents: PGY Three



**Christopher Bankhead MD**  
Louisiana State University-New Orleans



**J. Andy Dollahite MD**  
University of Southern California



**Patrick Gilligan MD**  
The University of New Mexico



**Paul Johnson MD**  
University of Pittsburgh



**Jay Wojcik MD**  
University of Colorado

## Residents: PGY Four



**Erika Garbrecht MD**  
University of Oklahoma



**Brett Mulawka MD**  
University of Minnesota



**Brielle Payne MD**  
University of Texas Southwestern Medical Center



**Tony Pedri MD**  
University of Washington



**Alex Telis MD**  
George Washington University

# Physical Therapy Faculty



**Ron Andrews** PT PhD OCS—Associate Professor  
Degrees: PT, University of Wisconsin-Madison; PhD, The University of New Mexico  
Teaching Expertise: Kinesiology, Orthopaedic Evaluation and Treatment



**Tiffany Enache** PT DPT—Assistant Professor; Director, Clinical Education  
Degrees: PT, University of New England; DPT, AT Still University  
Teaching Expertise: Orthopaedics, Clinical Decision Making



**Marybeth Barkocy** PT DPT PCS—Assistant Professor  
Degrees: PT, The University of New Mexico, DPT, AT Still University  
Teaching Expertise: Pediatrics; Health, Wellness and Fitness



**Burke Gurney** PT PhD OCS—Professor  
Degrees: PT, University of Texas-Galveston; PhD, The University of New Mexico  
Teaching Expertise: Physical Agents, Exercise Physiology, Orthopaedic Evaluation and Treatment



**Fred Carey** PT PhD—Associate Professor  
Degrees: PT, The University of New Mexico; PhD, University of Michigan  
Teaching Expertise: Neuroanatomy, Acute Care and Cardiopulmonary, Gross Anatomy



**Beth Moody Jones** PT DPT MS OCS—Associate Professor  
Degrees: PT, University of Vermont; DPT, AT Still University  
Teaching Expertise: Gross Anatomy, Evidence-Based Physical Therapy, Advanced Spinal Manipulation



**Kathy Dieruf** PT PhD NCS—Associate Professor  
Degrees: PT, The University of New Mexico; PhD, The University of New Mexico  
Teaching Expertise: Adult Neuro Evaluation and Treatment, Psychosocial Issues, Women's Health, Ethics, Ethical Decision Making, Quality of Life



**Jodi Schilz** MS PhD—Assistant Professor  
Degrees: MS, Colorado State University; PhD, University of Wyoming  
Teaching Expertise: Epilepsy, Environmental Toxicology and STEM, Pharmacology, Evidence-Based Practice, Differential Diagnosis



**Deborah Doerfler** PT DPT PhD OCS—Assistant Professor  
Degrees: PT, The University of New Mexico; DPT, Rocky Mountain University; PhD, Rocky Mountain University  
Teaching Expertise: Gerontology Physical Therapy, Evidence-Based Practice, and Orthopaedic Treatment



**Yuri Yoshida** PT PhD—Assistant Professor  
Degrees: PT, Showa University; PhD, University of Delaware  
Teaching Expertise: Electromyography, Motion Analysis, Orthopaedics, Evidence-Based Practice, Gerontology, Prosthetics

# Division of Research




**Thomas DeCoster MD**  
Professor



**David Grow PhD**  
Adjunct Assistant  
Professor



**Deana Mercer MD**  
Research Director  
Associate Professor




**Dustin Richter MD**  
Assistant Professor



**Christina Salas PhD**  
Assistant Professor



**Julia Bowers**  
In loving memory



**Melanie DeLorenzo**  
BA English



**Sahar Freedman**  
BA English  
MA in progress



**Sherif Aboubakr**  
BS Civil Engineering  
PhD Civil Engineering  
in progress



**Christopher Buksa**  
BS Mechanical  
Engineering  
MS in progress



**Jodie Gomez**  
BS Bioengineering  
MS Mechanical  
Engineering in progress



**Alexander Hamilton**  
BS Computer  
Engineering



**Lauren Long**  
BS Mechanical  
Engineering  
MS in progress



**Farid Manuchehrfar**  
BS Mechanical Engineering  
PhD Biomedical Engineering  
in progress



**Therese Martinez**  
BS Mechanical Engineering  
MS in progress



**Steven Nery**  
BS Electrical  
Engineering,  
MS in progress



# Letter from the Chair

Robert C. Schenck Jr, MD



I am pleased to present the sixth volume of *The University of New Mexico Orthopaedics Research Journal (UNMORJ)*. As the premier academic orthopaedic training program in the state, The University of New Mexico (UNM) Department of Orthopaedics & Rehabilitation provides services and information to benefit the people of New

Mexico and orthopaedic practitioners who care for them—something we have done with distinction for almost 50 years. The popularity of the program extends beyond UNM and into national recognition for resident education. Our entire group functions as a supportive community and team, thanks to the efforts of our residents, fellows, faculty members, nurse practitioners, physician assistants, medical assistants, orthopaedic technicians, staff members, and research collaborators. We all share the same purpose and mission: to enhance the quality of care for our patients.

*UNMORJ* is quite special, and we are excited to announce the first inclusion of an official peer-review process. This is the first step toward nationally and internationally expanding *UNMORJ* audiences, with eventual indexing in MEDLINE and PubMed—the primary database listings for scholarly biomedical articles. Research in general continues to prosper under the leadership of UNM faculty and financial support of the Sandia Orthopaedic Alumni Society (SOAS), allowing us to share state-of-the-art orthopaedic information with our many partners in New Mexico and the Southwest. I am proud to reveal several of our accomplishments during the past year.

As evidenced by this journal, research productivity at our department continues to develop. The total number of publications increased from 12 in 2009 to 94 in 2017! We are very grateful for the leadership provided by Drs. Deana M. Mercer, Christina Salas, and Thomas A. DeCoster, with Dr. Mercer as the director of research. Furthermore, we express sincere gratitude to Dr. Gehron P. Treme, Residency Program Director, for his initiative in helping residents complete requirements of the Accreditation Council for Graduate Medical Education (commonly known as the ACGME). This allows our

residents to become experienced in research activities as an equal part of becoming outstanding orthopaedic physicians.

Lastly, my thanks to the many attending physicians, residents, and medical students who create such excellent publications, presentations, and grants. The development of a research-incentive program, along with the invaluable dedication from Drs. Mercer and Salas, has fueled scholarly pursuits in the department. *UNMORJ* was the dream of many, and we are excited to have materialized that dream into a peer-reviewed publication thanks to the efforts of our journal team, the contribution of UNM staff and faculty, and—of course—the time and dedication of our esteemed peer reviewers.

Our faculty continuously grows and reflects the great culture of an orthopaedic family. We are excited to welcome back Dr. Dustin Richter after his sports medicine fellowship, who will be both clinically active and be one of our first faculty to have protected research time weekly. Dustin will lead our robust sports medicine research program, having shown great expertise in mentoring and producing cutting-edge research. We are also very excited to bring in Dr. Haywan Chiu to help work with Drs. Eric Lew and John Marek in the CHILE (Center for Healing in the Lower Extremity) patient services. Drs. Chiu, Lew, Marek and others are excited for the great research opportunities to help our patients with diabetes. We are also thrilled to welcome Dr. Rebecca Dutton to our new PM&R (physical medicine and rehabilitation) program, which is expanding at UNM under Dr. Evan Rivers in neurosurgery. Dr. Dutton will round us out in the nonoperative care of athletes, education of residents, and excellence of research and patient care. Furthermore, the addition of Dr. Brandee Black (who also performed her fellowship here) to our faculty team has helped solidify our efforts at Sandoval Regional Medical Center (SRMC). I would like to thank UNM and SRMC faculties for helping our practice become even more robust.

We hope all the best for our five senior residents as they end this phase of their careers (as “Junior-Junior” faculty at UNM) and begin new ones. Dr. Katherine Gavin will begin her foot and ankle fellowship at Rush University in Chicago, IL. Meanwhile, at the University of Tennessee-Campbell Clinic in Memphis, TN, Dr. Ian Power will perform his sports medicine fellowship. Dr. Keith Gill will similarly leave for a sports medicine fellowship, although at the University of Virginia in Charlottesville, VA. A hand

fellowship will be undertaken by Dr. Drew Newhoff at the University of Colorado in Denver. Finally, Michael Decker will complete his fellowship in adult hip and knee reconstruction at Western University in London, Ontario, Canada. We are so proud of this year's resident class, and I am grateful for the support of their families and friends. These five orthopaedic surgeons are extremely talented and will be missed here in Albuquerque. Katherine, Ian, Keith, Drew, and Michael, we are most proud of your accomplishments. I, along with the entire department, thank Dr. Treme for his outstanding leadership in the overarching education of UNM orthopaedic residents. I would also like to thank Joni Roberts for all of her work and dedication in the process of educating UNM orthopaedic residents.

I am pleased to add that our division of physical therapy, under the direction of Dr. Burke Gurney, celebrated the anniversary of the 40th graduating class, with more than 150 alumni. The division now has 11 full-time faculty members with expertise in orthopaedics, adult neurology, pediatrics, acute care, geriatrics, cardiopulmonary physical therapy, and comprehensive motion analysis (with the welcome of Dr. Yuri Yoshida). Furthermore, I wish to congratulate Drs. Ronald Andrews and Marybeth Barckocyc, who recently earned board certification in orthopaedics and pediatrics, respectively (with subsequent professional travels to Saudi Arabia and Russia). The educators, practitioners, and researchers oversee three cohorts of 30 students who, after successfully completing the 3-year program, obtain a Doctor of Physical Therapy. Speaking of students—the Service Learning Student Physical Therapy Clinic just completed an excellent first year, during which student-faculty collaboration provided countless pro bono services to our numerous patients.

I want to thank our loyal alumni of SOAS for their enormous dedication and support, which includes hosting three annual events. The Eric Thomas Memorial Golf Tournament is held every year in honor of Dr. Eric A. Thomas (Class of 2004), in which we see alumni from all over the country enjoying Albuquerque's great fall weather at the UNM Championship Golf Course. Additionally, the Joel Lubin Visiting Professorship lecture series occurs every spring to pay respects to Dr. Joel W. Lubin (Class of 2001). Dr. Lubin's mother, Linda Lubin, kindly spoke at this year's talk, inviting us all to reflect on the importance of early interventions as medical practitioners. Additionally, the event was moderated by our fantastic guest speakers, Drs. Brian Robinson (Class of 1998) and Patrick Hudson (Class of 1978; hand fellow). Dr. Robinson led an invaluable, honest discussion on his perspectives gained—professionally and personally—after a near-death experience; Dr. Hudson provided illuminating advice on

ways to maintain work-life balance as a practicing surgeon, which I know will become a valuable resource for faculty and residents. And, thirdly, we always look forward to visiting with alumni at the SOAS-sponsored reception during the annual meeting of the American Academy of Orthopaedic Surgeons.

Each year, the assistance of alumni becomes more important to the department. SOAS, created exclusively for graduates of our program, has a new lifetime membership available for a pledge of \$25,000 to the Sandia Circle (\$5000 every year for 5 years). I am a proud funder and lifetime member of SOAS and invite you to join me in becoming one, too. This is an exciting time to participate in the growth and success of our department. In addition to supporting the publication of this journal, you at SOAS support our outstanding resident surgeons. We are grateful to the following alumni and faculty for pledges of \$25,000 in helping the SOAS support resident-related activities: Drs. John M. Veitch, Gehron P. Treme, Deana M. Mercer, Kevin M. McGee, Sanagaram S. Shantharam, Joseph K. Newcomer, Brian J. Robinson, Dean W. Smith, John C. Franco, and Jennifer L. Fitzpatrick.

It has been another great year at The University of New Mexico Department of Orthopaedics & Rehabilitation. We express our sincerest gratitude to you—the alumni, faculty, staff, and general community—for your continued support.

Thank you.



Robert C. Schenck Jr, MD  
Professor and Chair

# Letter from the Co-Editors

Deana M. Mercer, MD; Christina Salas, PhD



Greetings! We welcome you to the sixth volume of *The University of New Mexico Orthopaedics Research Journal (UNMORJ)*, featuring research and educational efforts of faculty, alumni, fellows, residents, and students from The University of New Mexico Department of Orthopaedics & Rehabilitation and beyond.



We are excited to announce that this volume features the first peer-review process for *UNMORJ*. We aim to nationally and internationally expand *UNMORJ* audiences, with eventual indexing in MEDLINE and PubMed—the primary database listings for

scholarly biomedical articles.

We would like to express the utmost gratitude for our reviewers who lent their expertise, efforts, and time to make our journal a successful, peer-reviewed publication. We sincerely thank all the contributors to this production—as well as Gail Case, Department Administrator, and *UNMORJ* Team members Melanie DeLorenzo, Layout Editor; Sahar Freeman, Copy Editor; and Joni Roberts, Managing Editor—whose work and dedication were instrumental in bringing the journal to fruition.

Finally, we invite you to explore our recent department publications, listed below. We hope that the articles inspire thought, discussion, and future research ideas and contributions. (Bolded names indicate current or past faculty members, residents, fellows, and graduate students of the department.)

- Agel J, **DeCoster TA**, Swiontkowski MF, Roberts CS. How many orthopaedic surgeons does it take to write a manuscript? A vignette-based discussion of authorship in orthopaedic surgery. *J Bone Joint Surg Am* 2016;98(21):e96.
- Ashbaugh A, **McGrew C**. Kinesio tape for sub-acute musculoskeletal pain and disability: is it helpful [editorial]? *Sports Rev J* 2016;2(1):17.
- **Brantley J, Majumdar A, Jobe T, Kallur A, Salas C**. A biomechanical comparison of pin configurations used for percutaneous pinning of distal tibia fractures in children. *Iowa Orthop J* 2016;36:133-7.
- **DeCoster TA**. Intraoperative injection significantly reduces postoperative pain in trauma patients too [commentary on Koehler D, Marsh JL, Karam M, Fruehling C, Willey ML. Efficacy of surgical-site, multimodal drug injection following operative management of femoral fractures: a randomized controlled trial. *JBJS* 2017;99(6):512-9]. *JBJS* 2017;99(6):e29. doi: 10.2106/JBJS.16.01392.
- **Godfrey J, Choi PD, Shabtai L, Nosssov SB, Sarah B, Williams A, Lindberg AW, Silva S, Caird MS, Schur MD, Arkader A**. Management of pediatric type I open fractures in the Emergency Department or operating room: a multi-center perspective [Epub ahead of print March 10, 2017]. *J Pediatr Orthop* 2017.
- Grossman LS, **Price AL**, Rush ET, Goodwin JL, Wallace MJ, Esposito PW. Initial experience with percutaneous IM rodding of the humeri in children with osteogenesis imperfecta [Epub ahead of print September 22, 2016]. *J Pediatr Orthop* 2017. doi: 10.1097/BPO.0000000000000856.
- Hanlon FM, **McGrew CA**, Mayer AR. Does a unique neuropsychiatric profile currently exist for chronic traumatic encephalopathy? *Curr Sports Med Rep* 2017;16(1):30-35. doi: 10.1249/JSR.0000000000000324.
- **Johnson P, Ocksrider J, Silva SR**. Update and review of acute compartment syndrome and necrotizing fasciitis. *Intern Med Rev February* 2017;3(2). <http://internalmedicinereview.org/index.php/imr/article/view/356/pdf>. Accessed March 16, 2017.
- Lansdaal JR, Mouton T, **Wascher DC**, Demey G, Lustig S, Neyret P, Servien E. Early weight bearing versus delayed weight bearing in medial opening wedge high tibial osteotomy: a randomized controlled trial [Epub ahead of print July 1 2016]. *Knee Surg Sports Traumatol Arthrosc* 2016. doi: 10.1007/s00167-016-4225-8.
- Lewiecki EM, Boyle JF, Arora S, Bouchonville MF 2nd, **Chafey DH**. Telementoring: a novel approach to reducing the osteoporosis treatment gap [Epub ahead of print Jul 20 2016]. *Osteoporos Int* 2016.

- Lucas RM, Hsu JE, Whitney IJ, **Wasserburger J**, Matsen FA 3rd. Loose glenoid components in revision shoulder arthroplasty: is there an association with positive cultures? *J Shoulder Elbow Surg* 2016;25(8):1371-5. doi:10.1016/j.jse.2015.12.026.
- **McGrew, CA**. National Collegiate Athletic Association football and conditioning deaths: a positive progress report. *Curr Sports Med Rep* 2016;15(5):313-4.
- **McGrew CA**. No evidence for femoral pulse evaluation in normotensive college athletes during sports preparticipation examinations. *J Am Coll Cardiol* 2016;68(20):2242. doi:10.1016/j.jacc.2016.07.784.
- Murphy MV, Du DT, Hua W, Cortez KJ, Butler MG, Davis RL, **DeCoster TA**, Johnson L, Li L, Nakasato C, Nordin JD, Ramesh M, Schum M, Von Worley A, Zinderman C, Platt R, Klompas M. Risk factors for surgical site infections following anterior cruciate ligament reconstruction. *Infect Control Hosp Epidemiol* 2016;37(7):827-33.
- Pourkand A, **Salas C**, Regalado J, Bhakta K, **Tufaro R**, **Mercer D**, **Grow D**. Objective Evaluation of Motor Skills for Orthopaedic Residents Using a Motion Tracking Drill System. *Iowa Orthop J* 2016;36:13-9.
- Rahnemai-Azar AA, Abebe ES, **Johnson P**, Labrum J, Fu FH, Irrgang JJ, Samuelsson K, Musahl V. Increased lateral tibial slope predicts high-grade rotatory knee laxity pre-operatively in ACL reconstruction [Epub ahead of print May 6, 2016]. *Knee Surg Sports Traumatol Arthrosc* 2016.

*UNMORJ* is proud of its past and current accomplishments in highlighting original research relevant to orthopaedic surgery and engineering. We look forward to continue spreading knowledge to help improve care for patients on local, regional, national, and international levels.

Sincerely,



Deana M. Mercer, MD  
Associate Professor



Christina Salas, PhD  
Assistant Professor



# Letter from the Chief of the Division of Physical Therapy

Burke Gurney, PT, PhD, OCS



The University of New Mexico (UNM) Physical Therapy Program celebrated the anniversary of our 40th graduating class this summer. The faculty and staff joined with more than 150 alumni at the Rio Grande Zoo to celebrate with food, drink, and much nostalgia.

All 30 students from the Class of 2016 passed the

National Physical Therapy Exam on their first attempt. As a point of reference, the national average for first-time failure is almost 10%. That brings our 5-year accumulative passage rate to 99%. Our program continues to exceed national averages in both initial and overall pass rates.

Yuri Yoshida, PT, PhD, an expert in biomechanics, has taken over the duties as director for the Fred Rutan Motion Analysis Laboratory. She has already started collaborations with the Department of Orthopaedics & Rehabilitation as well as in the Exercise Science and Athletic Training Programs. Recently, the UNM Clinical & Translational Science Center awarded Dr. Yoshida with a \$25,000 grant to support her study, “Cross Cultural Adaptation of the Stand-Up Test in American Adults.”

Ronald Andrews, PT, PhD, and Marybeth Barkocy, PT, DPT, PCS, recently earned their board certifications in orthopaedics and pediatrics, respectively. Board certification in physical therapy is optional, and successful completion is an important professional accomplishment. Furthermore, Dr. Andrews recently returned from Saudi Arabia, where he was asked to review the Jazan University Physical Therapy Program. Dr. Barkocy traveled last spring to Russia to join John Phillips, MD, in helping establish a strong presence of pediatric rehabilitation (Russia recently recognized physical therapists as healthcare providers).

The Service Learning Student Physical Therapy Clinic just completed its first year of services. In the clinic, two first-year students join a second-year student and faculty member to provide pro bono physical therapy for our many patients. Since its conception, the service has expanded from twice a month to weekly clinics; additionally, the provided care has progressed from

treating exclusively orthopaedic-based injuries to adult neurologic and pediatric problems. The clinic is currently open on Thursday evenings at the UNM Casa de Salud Family Medical Office in the South Valley.

Finally, at the new Domenici Fitness Center (opened in April 2016), we are conducting fitness screening examinations. First- and second-year students will pair with faculty members to perform basic strength and flexibility screens on faculty, staff and students, helping them develop optimal fitness programs using the Health Sciences Center facilities.

## *The Future*

Later this year, we will move our classrooms into the newly constructed Domenici III building. The increased size of the classrooms will allow us to increase enrollment from 30 students to 36. We are currently investigating the potential use of the classrooms to house The Service Learning Student Physical Therapy Clinic.

I am excited to announce that I will be traveling to Ethiopia soon to develop another study-abroad opportunity for students, which will be similar to the one initiated in Guatemala in 2010. If successful, students will accompany me next year and participate in physical therapy co-treatment with Ethiopian physical therapists at Black Lion Hospital in Addis Ababa, as well as volunteer for humanitarian work at the Sr. Adelaide Missionaries of Charity.

The UNM Division of Physical Therapy is proud of the many accomplishments of our students, faculty members, and collaborators. Every year, we improve the ways in which we serve our institution, students, profession, and state—with the shared goal of providing high-quality care to the patients of New Mexico and beyond.

Sincerely,

*Burke Gurney, PT, PhD, OCS*

Burke Gurney, PT, PhD, OCS  
Professor and Chief

# Letter from the Residency Director

Gehron P. Treme, MD



Congratulations are in order as we approach the end of another academic year and witness the graduation of our current group of chief residents. We thank the faculty and staff members of the department who have fostered the growth of this group over the last 5 years. We acknowledge the families and friends who have supported

them throughout long hours, successes, and setbacks that residency training inevitably entails. Finally, of course, congratulations to Drs. Keith Gill, Michael Decker, Katherine Gavin, Ian Power, and Drew Newhoff for not only completing this mental and physical obstacle course—but for doing it with the class and good humor that reflects their quality as both physicians and individuals.

During this time of year, we also welcomed our intern class that joined us in June 2017: Christopher Kurnik (Nevada), Kathryn Helmig (Oklahoma), Benjamin Albertson (Vermont), Nathan Huff (New Mexico), and Benjamin Packard (Arizona). We look forward to participating in their growth over the next 5 years.

As a father, husband, physician, and program director, I often wonder who it is that I work for. Do I work for my family to provide the stability that allows for the growth of my children as they move into adulthood? Or is it my patients, who look to me for advice and treatment so that they may pursue the important activities in their lives? Or do I work for our residents—of the past, present, and future—to help offer the kind of training expected from our program and thereby provide fruitful, memorable, and enjoyable experiences? The obvious answer is yes to all, but the execution is far more complex. How do we balance the demands of our various “employers” to make a meaningful contribution to each one? That is the real trick. Although I do not have the answer, I know that the whole process requires attention and a real, concerted effort to achieve any level of success.

For our graduating residents who moved into the next phase of surgical practice—I hope that you identify the specific and unique “employers” to whom you answer every day. I hope that you will be able to align your values with your professional and personal aspirations, so that

you can maximize the enjoyment that you get from every facet of your life. I hope that you are able to discard those things that do not align lest they prevent the clarity needed to achieve those goals dear to you. We are a privileged lot, and a healthy respect and appreciation for that privilege is always in order. I know that the five of you will make us very proud, and we are better for the 5 years you spent with us here. We welcome and encourage you to come back to support our endeavors and to continue to improve on the program that you have helped to build and maintain. Thank you for all that you have done, and all the best to you and yours.

Sincerely,

A handwritten signature in black ink, appearing to read 'G. Treme', written over a horizontal line.

Gehron P. Treme, MD

Associate Professor and Residency Program Director

# Value-Based Bundled Repayment in Total Joint Arthroplasty

Michael M. Decker, MD

Department of Orthopaedics & Rehabilitation, The University of New Mexico Health Sciences Center, Albuquerque, New Mexico

## Abstract

The United States continues to spend an unprecedented amount of annual money on healthcare. However, the costs of providing care may not appropriately reflect the quality of care patients are receiving. This is particularly concerning when examining the projected increase in total joint arthroplasty (TJA) procedures over the next few decades, which are expected to increase to nearly 4 million procedures annually. The Center for Medicare and Medicaid Services (CMS) has responded by increasingly shifting reimbursements from the less efficient fee-for-service repayment model to value-based repayment. The Comprehensive Care for Joint Replacement (CJR) bundle payment model has recently been implemented as part of this shift towards value-based care delivery. The CJR repayment model, developed based on the success of the elective Bundled Payments for Care Improvement (BPCI) initiative, is an episodic bundled payment for TJA procedures, putting more financial responsibility on hospitals with the aim of improving quality of care, reducing costs, and decreasing local and regional cost and quality variability amongst providers and hospitals. I reviewed current studies on the BPCI and CJR model, including benefits associated with reducing patient readmissions to the hospital; limited costs and postoperative complications associated with post-acute care facilities and patient length of stay; and instituting evidence-based protocols for preoperative, perioperative, and postoperative care. Promising data exists that suggests these programs may help incentivize reducing costs and improving the quality of care provided to patients undergoing TJA procedures.

## Introduction

Healthcare spending in the United States (US) has risen to unprecedented levels. The US designates roughly \$3.2 trillion annually to healthcare, which accounts for 17.8% of the gross domestic product and equates to approximately \$9990 per person.<sup>1</sup> Furthermore, costs of Medicare and

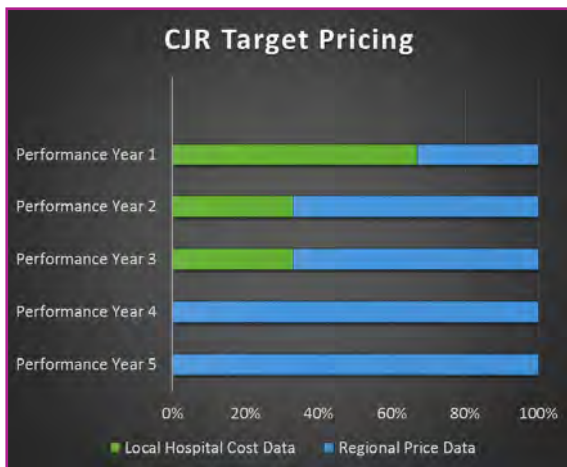Medicaid constitute about \$1.2 trillion (37%) of total healthcare spending in the US.<sup>1</sup> Although we spend a notable amount of money, the quality of care delivered has not kept pace. According to Davis et al,<sup>2</sup> the US ranks last amongst 11 industrialized countries in overall healthcare quality, efficiency, and equity in 2014. The soaring costs yet middling quality of the US healthcare system suggest a pressing value issue. Subsequently, there has been an appeal to transition away from the traditional fee-for-service repayment model to help improve efficiency in healthcare services through a more value and quality-based repayment model

In particular, hip and knee arthroplasty make up a large portion of the Center for Medicare & Medicaid Services (CMS) spending. In 2014, Medicare spending on total joint arthroplasty (TJA) hospitalizations alone was \$7 billion for 400,000 procedures,<sup>3</sup> which accounted for 5.7% of all yearly Medicare expenditures.<sup>4</sup> By 2030, the number of total knee arthroplasty (TKA) and total hip arthroplasty (THA) procedures, respectively, in the US annually are projected to increase to approximately 3,500,000 (673% increase) and more than 500,000 (174% increase).<sup>5</sup> As a payer for many of these procedures, CMS will experience a considerable cost burden. Additionally, costs associated with TJA vary substantially between geographical and local markets.<sup>3,6</sup> These increasing volumes and varying prices have resulted in the development and implementation of an alternative value-based repayment model from CMS, called the Comprehensive Care for Joint Replacement (CJR) model, which took effect in April 2016.<sup>7,8</sup>

The CJR model aims to hold hospitals accountable for the quality and cost of care while incentivizing improved coordination among providers involved in hip and knee replacement surgery.<sup>3</sup> The CJR is modeled on the success of the voluntary Bundled Payments for Care Improvement (BPCI). The general payment model is best described as an episodic bundled payment for a TJA procedure<sup>3</sup> where payers reimburse a contracted price for various services within a specific episode of care.<sup>7</sup> In the CJR model, this episode is defined as the index admission and 90-day postoperative period. In the CJR, each involved

care provider bills Medicare for appropriately provided services during the episode of care. CMS then reconciles all qualifying payments and compares the total costs to the target (or contracted) price. Should the hospital spend less than the target price, the difference is provided to the hospital as a payment. Hospitals and providers can share in that payment. As the model becomes more established, any excessive costs by hospitals above the target price will be penalized the difference. Nearly all medical and rehabilitation care in that 90-day period are included in the total costs, with few exceptions.<sup>8</sup> The target price in the first year is based on historical costs for the hospital; however, during the initial 5-year period, this transitions to a regional-based target price (Figure 1).

As a whole, using the CJR model may push hospitals and providers to identify and eliminate inefficiencies in caring for TJA patients, which can reduce affiliated costs and improve care quality. Because of the rapid transition in target pricing, hospitals will need to act swiftly to remain financially solvent. Experience with the BPCI has allowed the orthopaedic community to objectively identify cost-saving and quality-improving opportunities for TJA procedures in preparation for CJR.



**Figure 1.** Comprehensive Care for Joint Replacement (known as CJR) target price calculation. Multiple price modifiers such as Medicare savings discounts and capped losses are not represented here. Further information on targeting pricing can be found at <https://innovation.cms.gov/initiatives/cjr>.

## Reducing Readmissions

Readmission during an episode of care can be extremely costly to a hospital system in a bundled payment model. Although not all readmissions can be eliminated, reducing the complications that lead to readmissions can decrease costs and improve patient-care quality. Clair et al<sup>9</sup> found that overall 90-day readmission rates for primary TJA procedures were 10%. Surgical complications added costs

of \$36,038 for THA readmissions and \$38,953 for TKA readmissions, whereas medical complications added costs of \$22,775 for THA readmissions and \$24,183 for TKA readmissions. Bosco et al<sup>10</sup> quantified the cost burden of unplanned readmissions during the first 30 days after TJA and TJA in the Medicare population. Cost burden represents the necessary profit margin of each procedure in order to account for readmissions and remain financially solvent. Unplanned readmissions during this time for THA and TKA were both 2.4%, with a cost burden of 4.3% and 2.8%, respectively. Unplanned readmissions after revision THA and revision TKA were significantly more common and costly, with readmission rates of 9.5% and 11.9% and cost burdens of 8.3% and 11.9%, respectively.

In an effort to identify patients at risk for readmission, Kurtz et al<sup>11,12</sup> reviewed Medicare claims data on more than 950,000 TKA and 440,000 THA procedures. These studies found that readmission rates for THA and TKA during the 90-day postoperative period were 10.5% and 8.6%, respectively. Patients requiring a perioperative blood transfusion were at increased risk of readmission, whereas patients discharged to home or had hospital stays less than 5 days had significantly decreased risk of readmission. As surgeon procedural volume increased, patient risk for readmission was decreased.

Boraiah et al<sup>13</sup> developed a readmission risk assessment tool (RRAT) and analyzed the relationship between cumulative RRAT scores and readmission risk. This tool assessed numerous modifiable and non-modifiable risk factors including tobacco use, Staphylococcus Aureus colonization, obesity, cardiovascular disease, history or risk factors for venous thromboembolism, neurocognitive or psychological problems, physical conditioning, and diabetes. Of the modifiable risk factors assessed with this tool, diabetes, history of venous thromboembolic disease, and smoking were significantly associated with readmission regardless of patient age. Using this tool, patients with a cumulative RRAT score of 3 or greater were significantly associated with higher odds of readmission. Importantly, infection continues to be a leading cause for readmission.<sup>9,11-13</sup> This tool may help guide surgeons towards modifying certain risk factors to reduce the patient's odds of sustaining a complication or readmission before they undergo elective TJA.

Hospital readmissions are costly for hospitals and can be morbid for patients. Identifying high-risk patients, managing modifiable risk factors preoperatively, and focusing on high-quality perioperative care may significantly reduce the risk of readmission, improving overall patient health and quality of care while reducing hospital costs.

## Post-Acute Care Facility Discharges and Length of Stay

The 90-day period after discharge can be a considerable source of cost in a bundle-payment model, starting with the early post-discharge period. Patient discharge to a post-acute care (PAC) facility, such as a skilled nursing facility or inpatient rehabilitation facility, can lead to a significant increase in cost in a bundle-payment model. Patients discharged to PAC facilities instead of home can incur 30% to 40% higher costs during an episode of care.<sup>14,15</sup> In 2015, a total of \$10.8 billion was spent on discharges to PAC facilities after TJA.<sup>15</sup> PAC spending is the single largest contributor to variation in Medicare spending in the US, accounting for 73% of regional-spending variations.<sup>16</sup> Reducing patient discharges to PAC facilities is clearly an opportunity at cost reduction.

Multiple strategies have been proposed to reduce PAC discharges after TJA. Snow et al<sup>16</sup> evaluated the impact of a “prehabilitation” program on use of PAC services after TJA. Patients who underwent preoperative physical therapy had an overall 29% reduced usage of PAC services at an average adjusted cost reduction of \$1215, predominantly through reduced skilled nursing facility and home health agency payments. The average cost of preoperative physical therapy was \$100, limited to one or two sessions. The author suggested that the value of this therapy was predominantly in the patient’s planning for recovery and training in assistive walking devices as opposed to intensive range of motion and strength regimens. In another study, Slover et al<sup>17</sup> used decision analysis to assess the impact of extending inpatient hospital stays to avoid PAC facility discharge in a 90-day episode of care. Results showed that an inpatient stay can be extended to a total of 8.2 days after surgery if a patient is discharged to home and remain more cost-effective than discharge to a PAC facility. The authors suggested that savings that could be realized with such a strategy are primarily the result of relatively low costs of additional days in the acute care facility, compared to a more expensive stay at a PAC facility.

However, length of stay has been identified as a significant risk factor for readmission.<sup>11,12,18</sup> Williams et al<sup>18</sup> found that length of stay greater than 4 days after TJA is a significant risk factor for readmission within 90 days after surgery. Patients with higher American Society of Anesthesiologists (ASA) physical-status scores who had a length of stay greater than 4 days had higher readmission risk during the 31- to 90-day postoperative period than those with lower ASA scores. Longer hospital admissions increase the risk of complications such as hospital-acquired infections and venous thromboembolism.<sup>18</sup> Interestingly, the study also identified discharge to a facility other than

home as an independent risk factor for readmission. The risk of readmission for patients who required prolonged hospital stays is significant and can remain so even through the later period of the episode of care.

Although discharging to home may be more cost-effective than a PAC-facility discharge, it does not come without risk. Yao et al<sup>15</sup> assessed numerous risk factors for severe adverse events or readmission for patients discharged to home after TJA. Patients who experienced severe complications or readmission were older, smoked, obese, or functionally dependent, and the odds of a severe adverse event or readmission increased with each additional risk factor. About 70% of unplanned readmissions occurred within the first 2 weeks after discharge. The author concluded that patients discharged to home should be risk-stratified, and home healthcare surveillance should be more aggressively used in high-risk patients during the early post-discharge period to reduce complications and readmissions.

Ultimately, there is a balance between discharge location, length of stay, and patient risk factors that optimizes cost and improves the quality of care. The optimal post-discharge pathway for each patient will require accurate risk stratification and subsequent allocation of resources. Further investigation needs to be performed to identify these risk factors and determine effective ways to modify care accordingly.

## Standardized Care Pathways

Developing an efficient, streamlined care pathway for TJA patients has been proposed as an opportunity to improve value in an episodic bundle payment model by using cost-reduction techniques and providing improved quality of perioperative care. As a method to reduce inefficiency or use of duplicative services, hospitals have adopted standardized care pathways for TJA practices. These pathways create customary, evidence-based protocols for patient care in the preoperative, perioperative, and postoperative periods.<sup>19</sup>

Froemke et al<sup>7</sup> evaluated the impact of implementing a standardized care pathway, with a bundled payment and gainshare model, on patient care and costs. The study found several areas of improvement after implementation of this pilot initiative. Compared to the pre-pilot cohort, the pilot cohort had significantly reduced length of stay, greater discharge to home with self-care, decreased in discharge to skilled nursing facilities and home with healthcare, and a reduction of total-allowed claims by 6% per case. Concomitantly, quality measures including Surgical Care Improvement Project compliance, Press Ganey hospital scores, and 3-month postoperative Western

Ontario and McMaster Universities Arthritis Index scores were favorable compared to national benchmarks. Tessier et al<sup>19</sup> assessed cost differences and readmission rates of more than 77,000 Medicare TJA patients from 68 different orthopaedic groups within the US with and without defined clinical-care pathways. The study noted that these cohorts had similar readmission rates; however, groups with a defined clinical-care pathway averaged \$3189 less costs for THA and \$2466 less cost per case compared to those without defined clinical-care pathways.

Standardized care pathways for TJA patients have the potential to reduce inefficiency by streamlining common services, create clearly defined roles for each care provider, and align the interests of all providers with the patient to assure an excellent, cost-effective outcome.

## Conclusion

TJA is a major contributor to increasing costs seen by CMS, and this will only continue to grow. Procedural volume is increasing rapidly, and costs have been highly variable. With the implantation of the CJR model, there is increased incentive for providers to improve efficiency, decrease costs, and improve the quality of patient care. However, because of increasing influence of regional prices in the early stages of implementation and annually adjusted target prices, the available opportunities to reduce inefficiencies in care delivery and improve patient outcomes must be clearly delineated to help providers adjust to a rapidly changing landscape and remain solvent. Reducing hospital length of stay, decreasing use of PAC facilities and resources, reducing hospital readmissions, and implementing standardized care pathways have all been shown to have a positive impact on cost reduction and patient care quality.

Avenues need to be explored that help improve the overall patient-care experience by reducing complications and enhancing objective patient-outcome measures in order to continue to improve the overall value of total joint replacement surgery. It is essential that all the stakeholders in a patient's episode of care are incentivized to develop methods to improve patient outcomes within their scope of practice. Gainsharing is a financial relationship between a hospital and care providers involved in a TJA episode of care where costs savings realized as a payment to the hospital can be shared with these providers. The CJR model allows gainsharing opportunities, which may provide incentives for improved care coordination and quality. Strategies to reduce potentially unnecessary readmissions can decrease costs, but more importantly reduce unnecessary burden on TJA patients and their families. Some potential strategies that may reduce these readmission events include developing defined emergency

room care pathways for TJA patients, post-discharge patient monitoring by clinical staff, and preoperative planning sessions with individual patients where procedures are established for patients to navigate potential complications.

As spending decreases with downward pressure on payments and increasing risk being absorbed by hospitals, a possible consequence may be the withholding of a potentially beneficial TJA procedure from patients with increased risks. As the current CJR model does not account for preoperative medical care in their target price, there is significant opportunity to improve and even eliminate patient risk factors before surgery, such as poor glycemic control, smoking, or obesity, while keeping costs controlled. However, a major concern with this model will be the financial impact it will have on institutions currently providing TJA procedures to higher risk patients and whether or not this will lead to decrease in access to care for this population. We must critically assess the impact of this program and others like it to assure that patients are receiving the care they require.

## Funding

The author received no financial support for the research, authorship, and publication of this article.

## Conflict of Interest

The author reports no conflicts of interest.

## References

1. Centers for Medicare & Medicaid Services. NHE Fact Sheet. <https://www.cms.gov/research-statistics-data-and-systems/statistics-trends-and-reports/nationalhealthexpenddata/nhe-fact-sheet.html>. Modified December 2, 2016. Accessed January 1, 2017.
2. Davis K, Stremikis K, Squires D, Mirror CS. Mirror, mirror on the wall, 2014 update: how the US health care system compares internationally. The Commonwealth Fund. Published June 16, 2014. <http://www.commonwealthfund.org/publications/fund-reports/2014/jun/mirror-mirror>. Accessed January 1, 2017.
3. Center for Medicare & Medicaid Innovation. Comprehensive care for joint replacement model. <https://innovation.cms.gov/initiatives/cjr>. Updated December 27, 2016. Accessed January 1, 2017.
4. Cutler DM, Ghosh K. The potential for cost savings through bundled episode payments. *N Engl J Med* 2012;366(12):1075-7. doi: 10.1056/NEJMp1113361.

5. Kurtz S, Mowat F, Ong K, Chan N, Lau E, Halpern M. Prevalence of primary and revision total hip and knee arthroplasty in the United States from 1990 through 2002. *J Bone Joint Surg Am* 2005;87(7):1487-97.
6. Blue Cross Blue Shield. A study of cost variations for knee and hip replacement surgeries in the US. Published January 21, 2015. <https://www.bcbs.com/about-us/capabilities-initiatives/health-america/health-of-america-report/study-cost-variations>. Accessed January 1, 2017.
7. Froemke CC, Wang L, DeHart ML, Williamson RK, Ko LM, Duwelius PJ. Standardizing care and improving quality under a bundled payment initiative for total joint arthroplasty. *J Arthroplasty* 2015;30(10):1676-82. doi: 10.1016/j.arth.2015.04.028.
8. Centers for Medicare & Medicaid Services. Medicare program; comprehensive care for joint replacement payment model for acute care hospitals furnishing lower extremity joint replacement services; final rule. *Fed Regist* 2015;80(226):73274-554. Codified at 42 CFR §510. <https://www.federalregister.gov/documents/2015/11/24/2015-29438/medicare-program-comprehensive-care-for-joint-replacement-payment-model-for-acute-care-hospitals>. Accessed January 1, 2017.
9. Clair AJ, Evangelista PJ, Lajam CM, Slover JD, Bosco JA, Iorio R. Cost analysis of total joint arthroplasty readmissions in a bundled payment care improvement initiative. *J Arthroplasty* 2016;31(9):1862-5. doi: 10.1016/j.arth.2016.02.029.
10. Bosco JA 3rd, Karkenny AJ, Hutzler LH, Slover JD, Iorio R. Cost burden of 30-day readmissions following Medicare total hip and knee arthroplasty. *J Arthroplasty* 2014;29(5):903-5. doi: 10.1016/j.arth.2013.11.006.
11. Kurtz SM, Lau EC, Ong KL, Adler EM, Kolisek FR, Manley MT. Which hospital and clinical factors drive 30- and 90-day readmission after TKA? *J Arthroplasty* 2016;31(10):2099-107. doi: 10.1016/j.arth.2016.03.045.
12. Kurtz SM, Lau EC, Ong KL, Adler EM, Kolisek FR, Manley MT. Hospital, patient, and clinical factors influence 30- and 90-day readmission after primary total hip arthroplasty. *J Arthroplasty* 2016;31(10):2130-8. doi: 10.1016/j.arth.2016.03.041.
13. Boraiah S, Joo L, Inneh IA, et al. Management of modifiable risk factors prior to primary hip and knee arthroplasty: a readmission risk assessment tool. *J Bone Joint Surg Am* 2015;97(23):1921-8. doi: 10.2106/JBJS.N.01196.
14. Slover JD. You want a successful bundle: what about post-discharge care? *J Arthroplasty* 2016;31(5):936-7. doi: 10.1016/j.arth.2016.01.056.
15. Yao DH, Keswani A, Shah CK, Sher A, Koenig KM, Moucha CS. Home discharge after primary elective total joint arthroplasty: postdischarge complication timing and risk factor analysis [Epub ahead of print August 27, 2016]. *J Arthroplasty* 2016;S0883-5403(16)30478-8. doi: 10.1016/j.arth.2016.08.004.
16. Snow R, Granata J, Ruhil AV, Vogel K, McShane M, Wasielewski R. Associations between preoperative physical therapy and post-acute care utilization patterns and cost in total joint replacement. *J Bone Joint Surg Am* 2014;96(19):e165. doi: 10.2106/JBJS.M.01285.
17. Slover JD, Mullaly KA, Payne A, Iorio R, Bosco J. What is the best strategy to minimize after-care costs for total joint arthroplasty in a bundled payment environment? *J Arthroplasty* 2016;31(12):2710-3. doi: 10.1016/j.arth.2016.05.024.
18. Williams J, Kester BS, Bosco JA, Slover JD, Iorio R, Schwarzkopf R. The association between hospital length of stay and 90-day readmission risk within a total joint arthroplasty bundled payment initiative [Epub ahead of print September 28, 2016]. *J Arthroplasty* 2016;S0883-5403(16)30645-3. doi: 10.1016/j.arth.2016.09.005.
19. Tessier JE, Rupp G, Gera JT, DeHart ML, Kowalik TD, Duwelius PJ. Physicians with defined clear care pathways have better discharge disposition and lower cost. *J Arthroplasty* 2016;31(suppl 9):54-8. doi: 10.1016/j.arth.2016.05.001.

# Total Ankle Replacement, Then and Now: A Review

Katherine J. Gavin, MD

Department of Orthopaedics & Rehabilitation, The University of New Mexico Health Sciences Center, Albuquerque, New Mexico

## Abstract

Total ankle replacement (TAR) for treating end-stage osteoarthritis of the ankle joint has been evolving since the early 1960s. Increased understanding of the biomechanics and kinematics of the foot and ankle, postoperative results of implant use, and advances in technology have led to improved implant designs and treatment outcomes. The current study reviews associated historical perspectives, kinematics, biomechanics, patient selection, imaging procedures, modern surgical techniques, postoperative complications, and comparison studies with arthrodesis to help evaluate TAR in successfully treating osteoarthritis of the ankle joint. Although arthrodesis remains the gold standard for treatment, findings of new studies have suggested that TAR may be comparable in outcomes, gait mechanics, and complications.

## Introduction

Dr. Carrol Larson performed the first TAR in 1962 at the University of Iowa.<sup>1</sup> The patient was a painter, physically active, and worked at a John Deere factory. Findings of radiographs were used to create and guide implantation of a vitallium mold of the surface of his talus. Follow-up of the patient was not reported until 33 years later, which noted an American Orthopedic Foot and Ankle Score of 85 of 100, moderate range of motion, slight limp, and rare pain.<sup>1</sup> Although TAR was being performed as early as the 1960s, the designs of associated implants and treatment outcomes were not fully documented until the later part of the 20th century.

Several studies published between the 1970s and 1980s investigated the effectiveness of TAR in treating ankle osteoarthritis.<sup>2-5</sup> In 1973, Lord and Marotte<sup>2</sup> reported an average 5-year follow-up of 25 patients who underwent TAR, in which twelve TAR were unsuccessful and seven patients (3%) were satisfied with the treatment. During this period, most first-generation implants involved 2-component, cemented, and constrained or unconstrained designs (Table 1).<sup>3,4</sup> The tibia implant was

usually polyethylene and concave, and the talus implant was a metal alloy with a convex shape. Complications were frequently reported and included aseptic loosening, osteolysis with cyst development, subsidence in mechanically unstable bone after larger bone resections to allow for cementing, and low intrinsic stability resulting in mechanical failure.<sup>3,4</sup> Contraindications to TAR were soon defined by Newton<sup>5</sup> and included history of infection, varus or valgus deformity greater than 20°, ligamentous instability, avascular necrosis of the talus, nonunion of prior fusion, and rheumatoid arthritis with long-term steroid use.

**Table 1.** Creators of implants used in the first generation of total ankle replacements<sup>a,b</sup>

Years of total ankle replacement	Creator of used implants
1970s-1980s	Mayo Clinic
1970s-1980s	Imperial College of London Hospital Prosthesis
1976	Thompson-Richard
1975	Richard Smith
1970s	Newton Ankle Implant
1970s	Irine Ankle TAR (Howmedica)
1973	St Georg-Bucholtz
1973	Conaxial (Beck-Steffee) Ankle Prosthesis

<sup>a</sup> Kirkup<sup>3</sup>

<sup>b</sup> Wynn and Wilde<sup>4</sup>

In the late 1970s and middle 1980s, treatment results of arthrodesis appeared more promising than those of TAR.<sup>6,7</sup> Demottaz et al<sup>6</sup> compared TAR treatment outcomes at the Mayo Clinic between use of six different implants, including an in-house design, with an average follow-up of 15 months. Most of the implants (88%) showed progressively increased loosening. The study concluded that arthrodesis was the procedure of choice in treating





osteoarthritis of the ankle. Additionally, an editorial<sup>7</sup> published in 1985 within *The Journal of Bone and Joint Surgery (British Volume)* noted that, “clearly the answer to the question of replacing the ankle joint using current techniques must be ‘no.’”

To help understand the effectiveness of TAR in treating osteoarthritis of the ankle, the current review highlights kinematics, biomechanics, patient selection, imaging, surgical procedure, modern techniques, complications, and comparison studies with arthrodesis.

## Kinematics and Biomechanics

Since the early 1980s, technological advances in biomechanics have allowed researchers to better reproduce the physiological function and kinematics of the ankle, thus improving TAR implant design and positively affecting clinical outcomes.

In the ankle, the bony and ligament structures create a dynamic & highly congruent joint.<sup>8</sup> The average cartilage thickness is 1.6 mm, whereas that of the knee is 6 mm to 8 mm thick. Removal of the subchondral plate decreases compressive resistance by 30% to 90%. There is a changing instant center of rotation owing to the shape of the talar trochlea, known as being polycentric and poly-radial, which combines rolling and sliding motions.<sup>9</sup> The tibiotalar articulating surface contributes 70% anterior-posterior stability, 50% inversion-eversion stability, and 30% internal-external rotation stability. The ankle has a load-bearing surface of 11 cm<sup>2</sup> to 13 cm<sup>2</sup>, with a vertical load of about 5 times and 10 times the body weight during gait and running, respectively.

An important key for successful TAR is allowing for rotational forces while maintaining the stability of the joint and its components. Yamaguchi et al<sup>10,11</sup> examined a 2-component implant and found no difference in weight-bearing and non-weight-bearing kinematics concerning ankle range of motion. The kinematic patterns observed (eg, internal rotation during plantar flexion) were the same as those in naturally positioned ankles, although an overall decrease in range of motion was noted. Surface incongruity and hinging note on 2D and 3D imaging were not observed on static radiographs more than 40% of the time. Reproduced kinematics, in which the joint surface was replaced with a non-anatomic shape, suggested ankle motion may also be guided by extraarticular structures. Success of the arthroplasty depends on how successful designs can dissipate these rotational forces while maintaining the stability of the joint. The kinematics may seem normal, but the stress across the implant is not.

TAR reproduces muscle torque across the joint, which never equals that of an uninjured leg.<sup>12</sup> There is about

83% and 86% dorsiflexion and plantarflexion recovery, respectively. The percentage noted may be promising for rehabilitation, function, and short-term outcomes but potentially misleading for implant survival (with current designs).

Pedobarography is the study of pressure fields acting between the plantar surface of the foot and a supporting surface. Common measurements include maximum force, contact time, peak pressure, contact area, and center of pressure index. Hintermann and Valderrabano<sup>13</sup> examined the use of 148 Hintegra implants with pedobarographic measurements and found a normal plantar pressure distribution and normal line of center of pressure in 78.1%. Using similar measurements, Valderrabano and Hintermann<sup>14</sup> used the STAR prosthesis in treating 65 patients and noted that, at an average 3.5-year follow-up, about 53% of patients had normal plantar pressure distribution while walking. Although the studies did not assess the clinical ramifications of the findings, the long-term altered mechanics across an implant could affect loosening and adjacent joint pathological features. Pedobarographic measurements are useful for preoperative planning in treating complex deformities and evaluating for TAR.

## Patient Selection

In the experience of the author, patients who successfully undergo TAR are typically associated with the following descriptions:

- Aged 60 years or older
- Participate in low-demand physical activities (hiking, biking, swimming, golfing)
- No considerable medical comorbidities
- Do not smoke
- Normal body mass index
- Healthy bones
- Well aligned and stable hindfoot
- Healthy soft tissue (no previous operative procedure)
- Well preserved preoperative ankle range of motion
- Reasonable expectations; should not expect notable improvements in range of motion

## Imaging

Radiographs should include anteroposterior views with weight and lateral views of the foot and ankle. Clinicians should identify co-existing degenerative joint diseases and other deformities (eg, flat foot). The supramalleolar and inframalleolar ankle alignment should be assessed using the hindfoot alignment view, which accurately assesses

heel position in relation to long axis of the leg.<sup>15</sup> The beam is angled at 20° toward the floor, with the medial border of the foot parallel to the beam. A computed tomography scan can help assess bony defects and joint congruency.

## Surgical Approach

The traditional approach is anterior, between the tibialis anterior and extensor digitorum tendons. An alternative lateral approach has been described for specific implants, which involved an oblique osteotomy of the distal fibula and is repaired at the end of the operation.<sup>16</sup> If varus and valgus deformities can be surgically corrected with realignment procedures, then TAR is not contraindicated for treatment.

## Modern Designs

In the last few decades, implant designs for TAR have evolved (Table 2). Implants have more conservative and bone-sparing cuts, elimination of bone cement to reduce aseptic loosening, biologic interfaces, and increased surface area of metallic components to decrease subsidence.<sup>17,18</sup> The FDA approved five 2-component designs in the US: Agility (DePuy Synthes, Warsaw, IN),

Salto (Tornier, Bloomington, MN), INBONE (Wright Medical Group, Memphis, TN), Eclipse (Kinetikos Medical, Carlsbad, California), and Zimmer (Zimmer Trabecular Metal, Zimmer, Warsaw, IN). The STAR implant (Stryker, Mahwah, New Jersey) is the only 3-component design approved for use in the US.

In 2005, Stengel et al<sup>19</sup> published a systematic review meta-analysis of the efficacy of TAR using meniscal (mobile) bearing implants with 3-component designs. Eighteen studies were reviewed, totaling 1086 patients. The results indicated a significant functional improvement and slight increase in ankle range of motion compared with preoperative reports. There was an overall 5-year survival of 91%, with 1.6% deep infection, 14.7% impingement, and 6.3% ankle fusion. Of those patients with impingement, only a small fraction had it revised.

## Complications

Studies have shown that TAR can be a technically challenging procedure for surgeons.<sup>20</sup> Performing at least 21 TAR between 2003 and 2009 was considered “high volume.” These surgeons have reported considerable decreases for patients in postoperative complications, medial malleolus fractures, length of hospital stay, and hospital charges.<sup>20</sup>

**Table 2.** Modern designs of implants used in total ankle replacement and results of related studies

Implant name: details	Study (year)	Study variables	Study results
Agility: 2-component; most used implant US	Knecht et al <sup>21</sup> (2004)	126 patients, 132 ankles, 2-13.5 year FO	33 patients died at mean 9-year FO; > 90% of 67 patients with clinical FO satisfied; 89 of 117 ankles with radiograph FO had radiolucency around components
	Kopp et al <sup>22</sup> (2006)	41 patients, 43 ankles, 4-year FO	97% of 38 patients with clinical FO satisfied and would undergo again; 98 29 of 40 ankles with clinical FO had radiolucency
Beuchel-Pappas: 3-component; none US	Buechel et al <sup>23</sup> (2014)	Group one: 38 patients, 40 ankles, 2-20 year FO. Group two: 74 patients, 75 ankles, 2-12 year FO	Group one (shallow-sulcus design): 74% survivorship at 20-year FO; Group two (deep-sulcus design): 92% survivorship at 12-year FO
STAR: 3-component; only FDA-approved mobile-bearing ankle prosthesis in US	Kerkhoff et al <sup>24</sup> (2016)	124 patients 134 ankles 7.5-10 year FO	78% survivorship at 10-year FO; 15% of ankles unsuccessfully treated; 10.4% had multiple fractures; 60% had benign osteolytic cyst; > 50% had benign heterotopic ossification
Zimmer: 2-component, semi-constrained, new	Tan et al <sup>17</sup> (2016)	19 patients 20 ankles 12-22 month FO	No fibular complications, but had 2 plates removed for symptomatic hardware; no complications at 12-month FO.

FO, follow-up; US, United States; FDA, Food and Drug Administration.



Progressive designs have some of the same problems as noted with first-generation implants; however, improvements are considerable. For example, although osteolysis and radiolucencies have been common problems,<sup>21-24</sup> the following design changes to adjust these issues include coated metals, smaller bone cuts, congruent components, and attention to detail of alignment and orientation of components. One should have a low threshold to surgically revise the ankle. Medial and lateral malleolar fractures and tendon lacerations have also been reoccurring concerns.<sup>21-24</sup>

Accurate component position is difficult to obtain, yet failure to do so may severely affect treatment outcomes.<sup>25</sup> Low-volume centers have shown lower survival of components.<sup>26</sup> The talus is the most difficult to position because of its constantly changing center of rotation. One study showed that talus malrotation lead to significantly increased peak pressure, decreased contact area, and increased rotational torque; all of which were contributors to component failure, loosening, and polyethylene fracture.<sup>27</sup> Malposition also affects ligament balance and tension, which can have harmful effects.

Wound-healing complications and infection pose a notable threat to successful TAR. Studies have reported such complications up to 20%.<sup>28</sup> Proper patient selection is important to avoiding these problems. Assets include meticulous and skilled techniques for handling soft tissue, hemostasis, and multi-layered closure. Postoperatively, oblique elevation can be essential for successful treatment. If a patient experiences a large dehiscence, surgeons have typically created a local skin graft using the extensor digitorum brevis.<sup>29</sup>

Preoperative malalignment ( $>15^\circ$ ) can also lead to unsuccessful treatment. Patients who underwent TAR with this level of malalignment had 10 times more frequent edge loading postoperatively.<sup>27</sup> The 8-year survivorship of patients who underwent TAR was reported at 48% with varus or valgus incongruence noted preoperatively, whereas the survivorship was 90% for patients with a neutrally positioned ankle with osteoarthritis.<sup>30</sup>

If the subchondral plate is removed from the talus or the tibia, there is a decrease in compressive resistance of the bone.<sup>31</sup> Implant subsidence is caused by insufficient bone ingrowth, insufficient bone stock, mal-loading, overstuffing, or over-stressing with high level of activity. Most of these issues can be treated surgically. If performing a revision TAR, use of bone graft and larger components, cement, and staging the revision to allow the graft to take first have been helpful. If performing a revision with arthrodesis, physicians should preserve the height of the ankle with iliac crest autograft or femoral head allograft.<sup>32</sup>

Use of polyethylene in TAR has been reported with some

complications. Fracture and wear are consistent concerns. Ultra-high-molecular-weight polyethylene (known as UHMWPE) has less use in TAR owing to the risk of fracture with mobile-bearing 3-component implants.<sup>33</sup> Cross-linking the polyethylene can reduce its mechanical properties and decrease toughness, ductility, tensile strength, and fatigue strength. Polyethylene wear has been comparable to that in a posterior stabilized total knee arthroplasty, with similar particle size and concentration.<sup>34</sup>

## Total Ankle Replacement Versus Arthrodesis

Tibiotalar arthrodesis has been the gold standard for treating symptomatic end-stage osteoarthritis of the ankle. Historically, reports of the procedure have shown high fusion rates, low failure and complication rates, and significant improvement in clinical outcomes. The comparison of TAR and arthrodesis has been considerably researched.<sup>35-41</sup>

In 2007, SooHoo et al<sup>35</sup> performed a retrospective review on postoperative outcomes of 4705 arthrodesis and 480 TARs. Patients treated with TAR showed a significantly increased risk of device-related infection and major revision. Overall, TAR major revision rates by 1 year postoperatively were 9% and 5 years, 23%. Patients treated with arthrodesis had an increased rate of subtalar fusion at 5 years compared to those treated with TAR.

Four years later, Courville et al<sup>36</sup> reported the outcomes of a 60-year hypothetical cohort of patients with end-stage ankle osteoarthritis treated with either TAR or arthrodesis. The study used quality adjusted life years (QALY) as a generic measurement for disease burden, in which one QALY was equivalent to 1 year in perfect health. The study found that TAR cost \$20,200 more than arthrodesis but had 1.7 more QALY than arthrodesis. The authors concluded that although the implants were costly and patients required lengthier follow-up, TAR remained a more cost-effective alternative to arthrodesis.

In 2007, Haddad et al<sup>37</sup> systematically reviewed relevant studies published between 1990-2004 (49 total; 10 on TAR, 39 on arthrodesis). A total of 852 and 1262 patients underwent TAR and arthrodesis, respectively. The mean American Orthopedic Foot and Ankle Score for TAR was 78.2, whereas that of arthrodesis was 75.6. The 5-year and 10-year survival for TAR was 78% and 77%, respectively. Rate of revision TAR was 7% (vs 9% for arthrodesis, with nonunion being the most common reason). About 1% of patients in the TAR group underwent below-knee amputation (vs 5% for arthrodesis). The study concluded that "intermediate outcomes of [total ankle replacement] appear to be similar to ankle arthrodesis, though ultimately the data is sparse. It should be noted this study while well

conducted is rather outdated and survivorship numbers are reported as much better in the more recent literature.”

The debate on whether to perform TAR or arthrodesis continues with a more recent study in 2016.<sup>38</sup> It is the first randomized control trial comparing TAR to arthrodesis, currently in data collection and based out of the United Kingdom. The goal is to enroll 328 patients aged 50 to 85 years with end-stage ankle osteoarthritis. The primary outcome measure is patient-reported validated outcomes throughout the first postoperative year. Secondary outcomes include quality of life scores, complications, revision, and reoperation.

Overall, arthrodesis remains the gold standard for treating end-stage ankle osteoarthritis; however, patient indicators for choosing TAR (performed with technical skill) should be considered. More studies have been published that reveal improved gait mechanics and better patient outcomes with TAR than arthrodesis.<sup>39</sup> Yet other recent articles have noted adjacent joint osteoarthritis after symptomatic arthrodesis may not be as frequent as once thought.<sup>40</sup> The debate will clearly continue for some time. Thanks to the advent of 3D printing technology, TAR has moved toward involvement of patient-specific implants such as the Prophecy INBONE and Infinity (Wright Medical Group, Memphis, TN) implants.<sup>41</sup> The effect of these implants on TAR has yet to be determined.

## Conclusion

TAR has proven to be a challenging yet successful operative procedure to help patients with symptomatic end-stage ankle osteoarthritis. Although mechanical and technical difficulties with the procedure may challenge surgeons, researchers, and patients, improvements and breakthroughs in implant design are constant. Careful patient selection and technical skill can help minimize the risks and improve outcomes of patients treated with TAR.

## Funding

The author received no financial support for the research, authorship, and publication of this article.

## Conflict of Interest

The author reports no conflicts of interest.

## References

1. Muir DC, Amendola A, Saltzman CL. Forty-year outcome of ankle “cup” arthroplasty for post-traumatic arthritis. *Iowa Orthop J* 2002;22:99-102.

2. Lord G, Marotte JH. Total ankle prosthesis--technic and 1st results: apropos of 12 cases [In French]. *Rev Chir Orthop Reparatrice Appar Mot* 1973;59(2):139-51.
3. Kirkup J. Richard Smith ankle arthroplasty. *J R Soc Med* 1985;78(4):301-4.
4. Wynn AH, Wilde AH. Long-term follow-up of the Conaxial (Beck-Steffee) total ankle arthroplasty. *Foot Ankle* 1992;13(6):303-6.
5. Newton SE 3rd. Total ankle arthroplasty: clinical study of fifty cases. *J Bone Joint Surg Am* 1982;64(1):104-11.
6. Demottaz JD, Mazur JM, Thomas WH, Sledge CB, Simon SR. Clinical study of total ankle replacement with gait analysis: a preliminary report. *J Bone Joint Surg Am* 1979;61(7):976-88.
7. Hamblen DL. Can the ankle joint be replaced? *J Bone Joint Surg Br* 1985;67(5):689-90.
8. Kakkar R, Siddique MS. Stresses in the ankle joint and total ankle replacement design. *Foot Ankle Surg* 2011;17(2):58-63. doi: 10.1016/j.fas.2011.02.002.
9. Leardini A, O'Connor JJ, Catani F, Giannini S. A geometric model of the human ankle joint. *J Biomech* 1999;32(6):585-91.
10. Yamaguchi S, Tanaka Y, Kosugi S, Takakura Y, Sasho T, Banks SA. In vivo kinematics of two-component total ankle arthroplasty during non-weightbearing and weightbearing dorsiflexion/plantarflexion. *J Biomech* 2011;44(6):995-1000. doi: 10.1016/j.jbiomech.2011.02.078.
11. Yamaguchi S, Tanaka Y, Banks S, et al. In vivo kinematics and articular surface congruency of total ankle arthroplasty during gait. *J Biomech* 2012;45(12):2103-8. doi: 10.1016/j.jbiomech.2012.05.043.
12. Valderrabano V, Nigg BM, von Tscharner V, Frank CB, Hintermann B. Total ankle replacement in ankle osteoarthritis: an analysis of muscle rehabilitation [published erratum in: *Foot Ankle Int* 2007;28(5):vi]. *Foot Ankle Int* 2007;28(2):281-91.
13. Hintermann B, Valderrabano V. Total ankle replacement. *Foot Ankle Clin* 2003;8(2):375-405.
14. Valderrabano V, Hintermann B, Dick W. Scandinavian total ankle replacement: a 3.7-year average followup of 65 patients. *Clin Orthop Relat Res* 2004;(424):47-56.
15. Saltzman CL, el-Khoury GY. The hindfoot alignment view. *Foot Ankle Int* 1995;16(9):572-6.
16. Barg A, Saltzman CL. Ankle Replacement. In: Coughlin, MJ, Saltzman CL, and Anderson RB, eds. *Mann's Surgery of the Foot and Ankle*. Philadelphia, PA: Elsevier and Saunders; 2014.
17. Tan EW, Maccario C, Talusan PG, Schon LC. Early complications and secondary procedures in transfibular total ankle replacement. *Foot Ankle Int* 2016;37(8):835-41. doi:10.1177/1071100716644817.

18. Gougoulias NE, Khanna A, Maffulli N. History and evolution in total ankle arthroplasty. *Br Med Bull* 2009;89:111-51. doi: 10.1093/bmb/ldn039.
19. Stengel D, Bauwens K, Ekkernkamp A, Cramer J. Efficacy of total ankle replacement with meniscal-bearing devices: a systematic review and meta-analysis. *Arch Orthop Trauma Surg* 2005;125(2):109-19.
20. Basques BA, Bitterman A, Campbell KJ, Haughom BD, Lin J, Lee S. Influence of surgeon volume on inpatient complications, cost, and length of stay following total ankle arthroplasty. *Foot Ankle Int* 2016 Oct;37(10):1046-51.
21. Knecht SI, Estin M, Callaghan JJ, et al. The Agility total ankle arthroplasty: seven to sixteen-year follow-up. *J Bone Joint Surg Am* 2004;86-A(6):1161-71.
22. Kopp FJ, Patel MM, Deland JT, O'Malley MJ. Total ankle arthroplasty with the Agility prosthesis: clinical and radiographic evaluation. *Foot Ankle Int* 2006;27(2):97-103.
23. Buechel FF Sr, Buechel FF Jr, Pappas MJ. Twenty-year evaluation of cementless mobile-bearing total ankle replacements. *Clin Orthop Relat Res* 2004;(424):19-26.
24. Kerkhoff YR, Kosse NM, Metsaars WP, Louwerens JW. Long-term functional and radiographic outcome of a mobile bearing ankle prosthesis. *Foot Ankle Int* 2016;37(12):1292-302.
25. Conti SF, Wong YS. Complications of total ankle replacement. *Clin Orthop Relat Res* 2001;(391):105-14.
26. Reuver JM, Dayerizadeh N, Burger B, Elmans L, Hoelen M, Tulp N. Total ankle replacement outcome in low volume centers: short-term followup. *Foot Ankle Int* 2010;31(12):1064-8. doi: 10.3113/FAI.2010.1064.
27. Fukuda T, Haddad SL, Ren Y, Zhang LQ. Impact of talar component rotation on contact pressure after total ankle arthroplasty: a cadaveric study. *Foot Ankle Int* 2010;31(5):404-11 doi: 10.3113/FAI.2010.0404.
28. Schubert JM, Patel S, Zarutsky E. Perioperative complications of the Agility total ankle replacement in 50 initial, consecutive cases. *J Foot Ankle Surg* 2006;45(3):139-46.
29. Houdek MT, Wagner ER, Pensy RA, Eglseder WA. Extensor digitorum brevis flap for the coverage of ankle and dorsal foot wounds: a technical trick. *J Orthop Trauma* 2016;30(12):e404-e408.
30. Haskell A, Mann RA. Perioperative complication rate of total ankle replacement is reduced by surgeon experience. *Foot Ankle Int* 2004;25(5):283-9.
31. Athavale SA, Joshi SD, Joshi SS. Internal architecture of the talus. *Foot Ankle Int* 2008;29(1):82-6. doi: 10.3113/FAI.2008.0082.
32. McCollum G, Myerson MS. Failure of the Agility total ankle replacement system and the salvage options. *Clin Podiatr Med Surg* 2013;30(2):207-23. doi: 10.1016/j.cpm.2012.10.001.
33. Brunner S, Barg A, Knupp M, et al. The Scandinavian total ankle replacement: long-term, eleven to fifteen-year, survivorship analysis of the prosthesis in seventy-two consecutive patients. *J Bone Joint Surg Am* 2013;95(8):711-8. doi: 10.2106/JBJS.K.01580.
34. Kobayashi A, Minoda Y, Kadoya Y, Ohashi H, Takaoka K, Saltzman CL. Ankle arthroplasties generate wear particles similar to knee arthroplasties. *Clin Orthop Relat Res* 2004;(424):69-72.
35. SooHoo NF, Zingmond DS, Ko CY. Comparison of reoperation rates following ankle arthrodesis and total ankle arthroplasty. *J Bone Joint Surg Am* 2007;89(10):2143-9.
36. Courville XF, Hecht PJ, Tosteson AN. Is total ankle arthroplasty a cost-effective alternative to ankle fusion? *Clin Orthop Relat Res* 2011;469(6):1721-7. doi: 10.1007/s11999-011-1848-4.
37. Haddad SL, Coetzee JC, Estok R, Fahrback K, Banel D, Nalysnyk L. Intermediate and long-term outcomes of total ankle arthroplasty and ankle arthrodesis: a systematic review of the literature. *J Bone Joint Surg Am* 2007;89(9):1899-905.
38. Goldberg AJ, Zaidi R, Thomson C, et al; TARVA study group. Total ankle replacement versus arthrodesis (TARVA): protocol for a multicentre randomised controlled trial. *BMJ Open* 2016;6(9):e012716. doi: 10.1136/bmjopen-2016-012716.
39. Singer S, Klejman S, Pinsker E, Houck J, Daniels T. Ankle arthroplasty and ankle arthrodesis: gait analysis compared with normal controls. *J Bone Joint Surg Am* 2013;95(24):e191(1-10). doi: 10.2106/JBJS.L.00465.
40. Ling JS, Smyth NA, Fraser EJ, et al. Investigating the relationship between ankle arthrodesis and adjacent-joint arthritis in the hindfoot: a systematic review [published erratum in: *J Bone Joint Surg Am* 2015;97(9):e43]. *J Bone Joint Surg Am* 2015;97(6):513-20. doi: 10.2106/JBJS.N.00426.
41. Hsu AR, Davis WH, Cohen BE, Jones CP, Ellington JK, Anderson RB. Radiographic outcomes of preoperative ct scan-derived patient-specific total ankle arthroplasty. *Foot Ankle Int* 2015;36(10):1163-9. doi: 10.1177/1071100715.

# Performance-Enhancing Drugs: A Review

G. Keith Gill, MD

Department of Orthopaedics & Rehabilitation, The University of New Mexico Health Sciences Center, Albuquerque, New Mexico

## Abstract

Performance-enhancing drugs and substances have been an integral part of athletics and society. The immense popularity and financial compensation associated with success in sports often results in a desire to win at all costs, which stimulates a never-ending appetite for use of ergogenic aids. Athletes have experimented with these substances (ranging from over-the-counter supplements to anabolic-androgenic steroids and beyond) if a possibility of advantage exists, whether scientifically or theoretically supported. As the technology to create new designer drugs becomes more available, the ability to test for the presence of these substances lags slightly behind. The knowledge base of sports-medicine physicians must constantly grow as new drugs and testing protocols change yearly. To help identify and evaluate the effects of performance-enhancing drugs on patient-athletes, I reviewed the history and current studies on anabolic steroids and related substances such as androstenedione, human growth hormone, Beta-2 agonists, stimulants, creatine, erythropoietin, beta blockers, and beta-hydroxy-beta-methylbutyrate. It is critical to be aware of the substances and related side effects to properly educate athlete-patients in decision making and help keep them eligible for participation in sports.

## Introduction

In athletic competition, participants have historically sought advantages to win. Ancient Greeks drank special concoctions such as a viscous opium juice called “doop” that became known more generally as “dope.”<sup>1</sup> Specific meals such as sheep hearts and testicles were eaten to enhance male performance. Ancient Romans used hallucinogenic substances known to be mushrooms, plants, and sesame seeds to aid performance. In this period, the origins of strychnine, an amphetamine-like substance, had its beginning.<sup>1</sup> The Romans also fed horses with hydromel (ie, honey-flavored alcohol) to increase the animals’ competitive edge.<sup>2</sup>

The use of performance-enhancing drugs has remained prevalent in sports. However, scientific data to determine evidence of benefit are relatively limited.<sup>3,4</sup> To help identify

and evaluate the effects of performance-enhancing drugs in sports, I reviewed historical perspectives and current studies on commonly used anabolic steroids and related substances such as androstenedione, human growth hormone (HGH), Beta-2 agonists, stimulants, creatine, erythropoietin (EPO), beta blockers, and beta-hydroxy-beta-methylbutyrate (HMB).

## Development of Performance-Enhancing Drugs: Modern Era

The modern era of performance-enhancing drugs began in 1865 when Dutch swimmers experimented with stimulants. Fifteen years later, two competitive cyclists died after eating ether-coated sugar cubes and drinking cocaine-laced wine.<sup>1</sup> At the 1904 Summer Olympics, the marathon runner Thomas Hicks collapsed at the finish line after receiving several injections of strychnine during the race.<sup>5</sup> (He was not disqualified and retained the Gold medal.) In 1889, Brown-Sequard self-injected extracts of Monkey testicle in attempt to reverse the aging process and increase sexual prowess. Furthermore, Adolf Butenandt isolated androsterone in 1931; he and Ruzicka synthesized testosterone in 1935.<sup>6</sup> Two years later, the first human trials with testosterone began.<sup>6</sup> A few years after that, the first clinical trials using anabolic steroids would begin.<sup>7</sup>

During World War II, German scientists began synthesizing anabolic steroids and testing the result on humans. This included studying chronic wasting to concentration-camp inmates; these testosterone derivatives may have also been given to German soldiers to increase levels of aggression and endurance.<sup>6</sup> Additionally, it was rumored that a physician gave Hitler anabolic steroids for treating certain ailments.<sup>7</sup>

Throughout the 1940s and 1950s, the governments of East Germany and the Soviet Union implemented steroid regimens and weight-training programs for amateur and professional athletes.<sup>8</sup> To counteract the resultant unrivaled success, an Olympic team physician of the United States (US), John Ziegler, helped create methandrostenolone or dianabol. The US Food and Drug Administration (FDA) approved the drug in 1958 originally to treat patients with malnourishment and burns, which quickly

became essential for weight lifters and athletes.<sup>9</sup> Such testosterone derivatives were later modified to enhance effectiveness and duration by alkylation, esterification, and aromatization.<sup>9</sup>

However, the investigation to determine benefits of anabolic steroids as performance enhancers was delayed owing to results of a study in 1972, which showed no difference between use of anabolic steroids and placebos concerning performance enhancement.<sup>3</sup> Researchers later noted that the study lacked consistent controls and statistical significance; however, the evidence remained unchallenged for 18 years. It was not until 2001 that studies showed clear differences between groups with and without high-doses of anabolic steroids in muscle mass, strength, and fat.<sup>3</sup>

## Anabolic Steroids

AAS or anabolic-androgenic steroids are synthetic, testosterone derivatives that exert their effects by two different but overlapping pathways.<sup>10</sup> The first pathway, the anabolic pathway, is responsible for the more desirable effects including muscle hypertrophy, increased muscle mass, and decreased fat storage. This is facilitated by activating steroid receptors and increasing mRNA, thus creating more protein. Furthermore, anabolic steroids stimulate increased growth hormone release and blunt the negative effects of cortisol which facilitates quicker recovery time. In addition, they increase erythropoiesis, appetite, and bone remodeling. However, the second pathway (androgenic pathway) results in virilizing characteristics such as infertility, testicular atrophy, and gynecomastia in men and, alopecia, vocal-cord hypertrophy, and clitoralomegaly in women. Adolescent patients typically experience stunted growth from premature physal closure and precocious puberty.<sup>10</sup>

Other notable side effects of AAS include increased aggression, mania, depression, severe acne, kidney damage commonly focal segmental glomerulosclerosis, liver damage (eg, hepatocellular carcinoma), peliosis hepatis, and increased metabolic burden from oral steroids. Hypertension and lipid abnormalities (ie, increased low-density lipoprotein [LDL] and decreased high-density lipoprotein [HDL]) are common and associated with a mortality risk at 4.6 times higher than non-AAS users. Because the tendons cannot compensate for extreme and accelerated muscle hypertrophy, there is also predilection for tendon rupture. Supplemental medications are used to counteract negative side effects of testosterone derivatives, including aromatase inhibitors, HCG (human chorionic gonadotropin) agonists, and selective estrogen antagonists.<sup>9</sup>

Although the FDA has approved some medical use

of AAS (including bone marrow stimulation, growth stimulation, appetite stimulate, hormone replacement therapy, and gender dysmorphia), the typical use is non-medical. Several studies found that the average AAS user is an educated, non-athlete man seeking cosmetic benefit. (This patient population appears to be well read and successful, challenging the typical “meat-head” stereotype.) The substances are delivered orally, parenterally, and transdermally. Stacking and pyramiding are common tactics used, which involve multiple forms of steroids and cycle them for 4 to 18 weeks, respectively. This method facilitates competition-based training and may help avoid positive test results for drug use.<sup>9</sup>

Anabolic steroids are considered Schedule III controlled substances, meaning a prescription is required and possession is punishable by up to 7 years in prison. Yet legality differs among countries, and some such as Mexico and Thailand have no legal ramifications.<sup>7</sup> Legislation in the US changed considerably after Ben Johnson tested positive for a banned substance at the Summer Olympics in Seoul, which resulted in the Anabolic Control Act of 1990.<sup>7</sup> The law expanded in 2014 to include 24 new substances and crimes for mislabeling. In 1994, the Dietary Supplement Health and Education Act was passed, allowing supplements and prohormones to be available over-the-counter and not subjected to strict regulations by the FDA. Major sporting bodies (ie, International Olympic Committee, National Football League [NFL], Major League Basketball, National Hockey League, National Basketball Association, and National Collegiate Athletic Association [NCAA]) have banned use of anabolic steroids (Table 1).<sup>7</sup>

Although testing for use of anabolic steroids is commonplace in professional associations, high-school testing has been described as unsuccessful thus far.<sup>4</sup> Texas led the way in legislation and testing of young athletes, spending up to 10 million dollars; however, owing to minimal positive tests out of thousands and the high cost of testing equipment and processes, the funding for high-school testing was canceled in 2015.<sup>4</sup> A normal ratio of testosterone to epitestosterone in adult males is 1.3:1, respectively. Rarely can a ratio of 4:1 be observed, yet a ratio of 6:1 equates to a positive test result.<sup>9</sup>

The substances are usually obtained using illegal channels, often smuggled across borders with other illegal drugs. Today, anabolic steroids are rarely produced in the US and commonly reflect a veterinary grade. Domestically, purchasing occurs by mail-order advertisements in workout magazines, websites, and most frequently at local gymnasiums.<sup>7</sup> Recently, counterfeit drugs and supplements have been making headlines.<sup>11</sup> Because the substances are not regulated, producers are diluting products to maximize profit and sometimes add toxic additives.<sup>11</sup>

Table 1. Banned substances of major sports as noted by the World Anti-Doping Agency <sup>a</sup>			
All times <sup>b</sup>	In competition <sup>c</sup>	In particular sports	NCAA, NFL, NBA, and MLB
Anabolic agents	Stimulants	Alcohol <sup>d</sup>	Stimulants
Peptide hormones, growth factors, related substances, and mimetics	Narcotics	Beta blockers <sup>e</sup>	Anabolic agents
Beta-2 agonists	Cannabinoids		Alcohol and beta blockers
Hormone and metabolic modulators	Glucocorticoids		Diuretics and masking agents
Diuretics and masking agents			Illicit drugs Peptide hormones, analogues Anti-estrogens Beta-2 Agonists

NCAA, National Collegiate Athletic Association; NFL, National Football League; NBA, National Basketball League; MLB, Major League Baseball.

<sup>a</sup> WADA. Prohibited List January 2017. Montreal, Canada: World Anti-Doping Agency; effective January 1, 2017.

<sup>b</sup> “All times” refers to substances banned at all times, eg, even during training.

<sup>c</sup> “In competition” refers to substances banned only during the actual game.

<sup>d</sup> Alcohol is banned in air sports, archery, and powerboating.

<sup>e</sup> Beta blockers are banned during archery, billiards, darts, golf, shooting, skiing, snowboarding, and underwater sports.

## Androstenedione

As Mark McGwire and Sammy Sosa set the baseball world on fire during the historic homerun race of 1998, so came the interest in an over-the-counter supplement called “Andro”. After being discovered in Mark McGwire’s locker, the drug gained great popularity, associated with increased muscle mass and rapid recovery after injury. Androstenedione is a direct precursor to testosterone and theoretically converts to testosterone. In reality, most studies have shown no increase in testosterone levels after androstenedione use.<sup>12</sup>

Furthermore, studies have found no improvement in athletic performance, lean body mass, or strength.<sup>12,13</sup> Because most of the side effects are shared with anabolic steroids, some studies have described an increased predilection of androstenedione to cause considerable increases in estrogen levels and decreased HDL.<sup>13,14</sup> Although it was readily available during the late 1990s, androstenedione is now banned by all major sports associations and considered a Schedule III controlled substance. The Anabolic Steroid Act was amended in 2004 to include androstenedione.<sup>13</sup>

## Human Growth Hormone

Originally discovered by Cushing in 1912, HGH is produced in the anterior lobe of the pituitary gland and responsible for accelerating linear growth and increasing body weight and muscle mass.<sup>15</sup> GnRH, sleep, exercise, L-Dopa, and arginine regulate growth-hormone release. HGH effects almost every tissue in the body.<sup>15</sup> In 1956, it was isolated from cadaver brains of monkeys and humans. The drug was then used to treat dwarfism and in children until the discovery of Creutzfeldt-Jakob disease transmission. Subsequently, HGH was discontinued until a recombinant form came in the 1980s.<sup>16</sup>

Numerous studies have shown significantly increased muscle hypertrophy but no increase in strength with use of HGH supplementation.<sup>16</sup> Overall, limited research has been conducted on HGH supplementation. Results of recent polls have revealed that since 2012, high-school teenager use of HGH has doubled.<sup>17</sup> Serious side effects from exogenous administration include insulin resistance, increased cholesterol and triglycerides, hypertrophic cardiomyopathy, hypogonadism, osteoporosis, acromegaly, and myopathic muscles.<sup>15</sup> HGH is available only by prescription.<sup>16</sup> It is banned by all major sporting associations but extremely difficult to detect. In 2010, only 15 positive test results were noted of 18,000, and the 2014-2015 NFL test revealed zero positive tests of 290.<sup>18</sup>



## Beta-2 Agonists

Well known for the use in treating asthma and chronic obstructive pulmonary disease, beta-2 agonists have also been used as performance-enhancing drugs. Specifically, athletes have abused clenbuterol and salbutamol owing to the known bronchodilation and anabolic effects. Clenbuterol and salbutamol increase protein synthesis and lean body mass.<sup>19</sup>

Bodybuilders have used high doses of clenbuterol before competitions because of the “cutting” or rapid fat-loss effect. Furthermore, many well-known celebrities have used these substances for weight-loss aids.<sup>20</sup> Beta-2 agonists also act as tocolytics and increase basal metabolic rate.<sup>19,20</sup> For example, the Tour de France Cyclist Alberto Contador tested positive for clenbuterol and was stripped of his 2010 crown. Side effects of using beta-2 agonist include tremor, agitation, palpitations, tachycardia, hypertension, myocardial infarction, and thyrotoxicosis.<sup>19</sup>

## Stimulants

Some of the oldest and most used performances-enhancing drugs include amphetamines and caffeine. Other, less-known stimulants include ephedrine, bromantane, and meldonium. In theory, these substances act by stimulating the sympathetic nervous system.<sup>21</sup>

Caffeine is the most widely available ergogenic aid and highly effective at delaying onset of fatigue. It is allowed in competitive athletics in small to moderate doses, and only levels greater than 800 mg are detectable by testing.<sup>21</sup> Doses of caffeine at 3 mg/kg to 9 mg/kg have been shown to increase performance in prolonged exercise and in intense short-duration exercises.<sup>21,22</sup> Side effects of caffeine include dehydration, tachycardia, and increased susceptibility to heat-related injury. Amphetamines have a potent ergogenic effect by increasing cardiac output and metabolism of free fatty acids.<sup>22</sup> Their mechanism involves central nervous system stimulation, which increases aggression, mental alertness, and decreases perception of fatigue.<sup>23</sup>

Ephedrine, ephedra or ma huang became popular in the 1990s as a weight-loss drug and energy enhancer.<sup>24</sup> It has been shown to promote short-term, modest weight-loss but with notable side effects.<sup>24</sup> These side effects include psychiatric symptoms, ventricular dysrhythmias, hypertension, and increased heat-related illness and stroke risk.<sup>25</sup> Numerous deaths have been associated with athletic activity and ephedrine usage.<sup>25</sup> Most notably, Corey Stringer, a football player (specifically, a lineman) of the Minnesota Vikings, died after sustaining a heat-related stroke during practice while using ephedrine.<sup>25</sup> The NFL has now banned ephedrine.<sup>25</sup>

Bromantane, originally used by Russian soldiers to decrease fatigue and shorten recovery time, gained prominence at the 1996 Summer Olympics when several Russian athletes tested positive for the substance.<sup>26</sup> Bromantane is a psychostimulant and anxiolytic with dopaminergic effects. It is thought to increase physical as well as mental performance.<sup>26</sup> It was later banned in 1997 as a stimulant and masking agent.<sup>26</sup> Use of bromantane is now researched as a treatment of numerous neurological disorders.<sup>26</sup>

Meldonium or mildronate made headlines when Maria Sharapova, professional tennis player, was suspended 2 years owing to testing positive for the substance. Meldonium had been described as a “metabolic modulator” owing to its ability to modulate enzymatic reactions in the body. Medically, its uses include treatment of coronary artery disease by vasodilation, anticonvulsant, and antihypnotic.<sup>27</sup> Although meldonium was placed on the banned list of substances in January 2016, there is limited evidence of benefit as a performance enhancer.<sup>27</sup> The potential benefits of meldonium include increased utilization of fatty acids, decreased production of lactic acid, improved utilization of glycogen, decreased oxidative stress, and enhanced aerobic endurance.<sup>28</sup>

## Creatine

First discovered by Chevreul in 1832, creatine was not seen in athletic performance until 1992 during the Barcelona Summer Olympics.<sup>29</sup> Creatine has since become the most popular nutritional supplement in history.<sup>29</sup> Several studies have shown a 50% use-rate among collegiate athletes and 33% in NFL players.<sup>29</sup>

Creatine is a naturally occurring compound primarily synthesized in the liver, pancreas, and kidney. Almost 95% of creatine is stored in skeletal muscle. It is made from the amino acids glycine, arginine, and methionine. Creatine provides energy during short-duration maximal bouts of anaerobic exercise. The phosphorylated form donates a phosphorus atom to resynthesize adenosine triphosphate.<sup>30</sup>

Multiple performance studies have described the effectiveness of Creatine supplementation for simple, short-duration maximal anaerobic events.<sup>30,31</sup> Weight lifters typically have increased single repetition (maximum, 20%-30%); cyclists, increased muscular force and power; sprinters, about 1% to 2% decrease in sprint times; and all athletes have been noted with increased weight and lean body mass.<sup>30</sup> However, studies have noted up to a 30% non-responder rate in the population and suggested increased mass owing to water retention.<sup>31</sup> Dehydration and muscle cramping have been the most common side effects.<sup>31</sup>

Creatine appears to be safe for short-term use, although

the effects of long-term use are unknown.<sup>32</sup> Intake of creatine supplements appears to be enhanced with carbohydrate ingestion, though multiple forms of creatine exist, creatine monohydrate appears to be most effective.<sup>32</sup> Creatine is an abundantly available over-the-counter substance and not tested or banned by any major sporting associations. The NCAA does not allow teams to provide creatine to players but it is not prohibited.<sup>32</sup>

## Erythropoietin

EPO and transfusion of red blood cells increases the oxygen carrying capacity of red blood cells and thus improves aerobic capacity and performance of working muscles.<sup>33</sup> The ergogenic benefit may be primarily in the endurance athlete who relies on aerobic metabolism. Subsequently, use of EPO has become extremely popular with cyclists, runners, and triathletes. The presence of EPO is difficult to detect, making it more enticing to endurance athletes.

EPO is a naturally occurring hormone produced in the kidney, which stimulates erythropoiesis in the body.<sup>33</sup> Additionally, a synthetic form can be produced with use of recombinant deoxyribonucleic acid (known more commonly as DNA) technology. Many highly publicized scandals, most notably Lance Armstrong, involved cyclists using and abusing EPO. Five Dutch cyclists died in 1987 after synthetic EPO release; between 1997 and 2000, eighteen cyclists died of stroke, myocardial infarction, or pulmonary embolism. EPO and blood doping is prohibited in all major sporting associations but continues to be difficult to detect. However, training at high altitudes and hyperbaric oxygen chambers are acceptable. Severe side effects exist with EPO use: transfusion risks, hyperviscosity syndrome, stroke, MI, heart failure, pulmonary embolism, dehydration, and death.

## Beta Blockers

Although drugs with antihypertensive and antianxiety effects would seem contradictory to performance enhancing, successful shooting and archery rely on fine motor control. In those certain sports, beta-blockers have been considered performance-enhancing drugs. A study from 1986 showed increased shooting performance of a beta-blocker group compared to the placebo group.<sup>34</sup>

## Beta-hydroxy-beta-methylbutyrate

HMB is a leucine metabolite, marketed as an anticatabolic supplement and aid in recovery time.<sup>35,36</sup> Use of HMB has been thought to result in increased testosterone levels,

delayed anaerobic metabolism, and avoidance of exercise-induced muscle damage.<sup>35,36</sup> HMB has a minimal side-effect profile, and some studies show it may be cardioprotective owing to its ability to lower LDL, total cholesterol, and systolic blood pressure. HMB is available over-the-counter as a nutritional supplement and is not banned by any sporting leagues or governing bodies.<sup>35,36</sup> Although several studies have shown promise in suppressing protein breakdown and muscle damage, studies have also noted minimal ergogenic advantage.<sup>37,38</sup>

## Conclusion

Performance-enhancing drugs have historically been an integral part of athletic competition. In the modern era, the use of performance-enhancing substances remains common (ie, anabolic steroids and related drugs such as androstenedione, HGH, beta-2 agonists, stimulants, creatine, EPO, beta blockers, and HMB). Although research on the potential effects of performance-enhancing drugs remains extensive, the results of some studies have questioned any significantly measurable evidence of benefit.<sup>12,13,27,31,37,38</sup> Furthermore, the difficulty in testing the presence of performance-enhancing substances (ie, testing protocols associated with high costs and minimal detections) may complicate study results.

Further studies are needed to evaluate the true prevalence of performance-enhancing drugs among athletes and differentiate sport-specific rates. Such studies may stem from randomized testing of athletes. Randomized, controlled studies are also needed to resolve conflicting data on specific substances and their effects on performance in sports.<sup>39</sup> Owing to constant discoveries and changes in the realm of performing-enhancing substances, sports-medicine physicians should be aware of available and current drugs to better educate and guide decisions of patient-athletes.

## Funding

The author received no financial support for the research, authorship, and publication of this article.

## Conflict of Interest

The author reports no conflicts of interest.

## References

1. Higgins AJ. From ancient Greece to modern Athens: 3000 years of doping in competition horses. *J Vet Pharmacol Ther* 2006;29(suppl 1):4-8. doi: 10.1111/j.1365-

2885.2006.00770\_4.x.

2. Kumar R. Competing against doping. *Br J Sports Med* 2010;44(suppl 1):i8.

3. Ariel G, Saville W. Anabolic steroids: the physiological effects of placebos. *Med Sci Sports Exerc* 1972;4(2):124-6.

4. Vertuno J. Texas high school steroid testing. The Dallas Morning News Inc. May 2015. <https://www.dallasnews.com/news/local-politics/2015/05/29/texas-high-school-steroids-testing-effort-shut-down>. Accessed January 9, 2017.

5. Woodland L. *Dope: The Use of Drugs in Sport*. Newton Abbott, UK: David & Charles; 1980.

6. Hoberman JM, Yesalis CE. The history of synthetic testosterone. *Sci Am* 1995;272(2):76-81.

7. Taylor WN. *Anabolic Steroids and the Athlete*. 2nd ed. Jefferson, NC: McFarland; 2002.

8. Franke WW, Berendonk B. Hormonal doping and androgenization of athletes: a secret program of the German Democratic Republic government. *Clin Chem* 1997;43(7):1262-79.

9. Hartgens F, Kuipers H. Effects of androgenic-anabolic steroids in athletes. *Sports Med* 2004;34(8):513-54.

10. Bowers LD. Athletic drug testing. *Clin Sports Med* 1998;17(2):299-318.

11. Petocz A, Taylor G, Naughton DP. Mission impossible? Regulatory and enforcement issues to ensure safety of dietary supplements. *Food Chem Toxicol* 2011;49(2):393-402. doi: 10.1016/j.fct.2010.11.014.

12. King DS, Sharp RL, Vukovich MD, et al. Effect of oral androstenedione on serum testosterone and adaptations to resistance training in young men: a randomized controlled trial. *JAMA* 1999;281(21):2020-8.

13. Broeder CE, Quindry J, Brittingham K, et al. The Andro Project: physiological and hormonal influences of androstenedione supplementation in men 35 to 65 years old participating in a high-intensity resistance training program. *Arch Intern Med* 2000;160(20):3093-104.

14. Josefson D. Concern raised about performance enhancing drugs in the US. *BMJ* 1998;317(7160):702.

15. Haupt HA. Anabolic steroids and growth hormone. *Am J Sports Med*. 1993;21(3):468-74.

16. Yarasheski KE, Zachwieja JJ, Campbell JA, Bier DM. Effect of growth hormone and resistance exercise on muscle growth and strength in older men. *Am J Physiol* 1995;268(2 pt 1):e268-e276.

17. LaBotz M, Griesemer BA; Council on Sports Medicine and Fitness. Use of performance-enhancing substances. *Pediatrics* 2016;138(1):e20161300. doi: 10.1542/peds.2016-1300.

18. Schrottenboer B. First year of HGH testing in NFL catches no one. *USA Today*. Feb 2, 2015. <https://www.usatoday.com/story/sports/nfl/2015/02/02/hgh-testing->

[effectiveness-questioned-debated-facade/22715375/](https://www.usatoday.com/story/sports/nfl/2015/02/02/hgh-testing-effectiveness-questioned-debated-facade/22715375/). Accessed January 9, 2017.

19. Koch S, MacInnis MJ, Rupert JL, Sporer BC, Koehle MS. Pharmacogenetic effects of inhaled salbutamol on 10-km time trial performance in competitive male and female cyclists. *Clin J Sport Med* 2016;26(2):145-51. doi: 10.1097/JSM.000000000000201.

20. Hostrup M, Kalsen A, Auchenberg M, Bangsbo J, Backer V. Effects of acute and 2-week administration of oral salbutamol on exercise performance and muscle strength in athletes. *Scand J Med Sci Sports* 2016;26(1):8-16. doi: 10.1111/sms.12298.

21. Spriet LL. Exercise and sport performance with low doses of caffeine. *Sports Med* 2014;44(suppl 2):S175-84. doi: 10.1007/s40279-014-0257-8.

22. Spriet LL. Caffeine and performance. *Int J Sport Nutr* 1995;5 suppl:S84-S99.

23. Wagner JC. Enhancement of athletic performance with drugs. An overview. *Sports Med* 1991;12(4):250-65.

24. Shekelle PG, Hardy ML, Morton SC, et al. Efficacy and safety of ephedra and ephedrine for weight loss and athletic performance: a meta-analysis. *JAMA* 2003;289(12):1537-45.

25. Casa DJ, Armstrong LE, Kenny GP, O'Connor FG, Huggins RA. Exertional heat stroke: new concepts regarding cause and care. *Curr Sports Med Rep* 2012;11(3):115-23. doi: 10.1249/JSR.0b013e31825615cc.

26. Oliynyk S, Oh S. The pharmacology of actoprotectors: practical application for improvement of mental and physical performance. *Biomol Ther (Seoul)* 2012;20(5):446-56. doi: 10.4062/biomolther.2012.20.5.446.

27. Axon R. Experts say there's little evidence meldonium enhances performance. *USA Today*. April 5, 2016. <https://www.usatoday.com/story/sports/olympics/2016/04/05/meldonium-experts-wada-performance-enhancing-drug/82663156/>. Updated April 8, 2016. Accessed January 10, 2017.

28. Lippi G, Mattiuzzi C. Misuse of the metabolic modulator meldonium in sports. *J Sport Health Sci* 2017;6(1):49-51. doi: 10.1016/j.jshs.2016.06.008

29. Harris RC, Söderlund K, Hultman E. Elevation of creatine in resting and exercised muscle of normal subjects by creatine supplementation. *Clin Sci (Lond)* 1992;83(3):367-74.

30. Kilduff LP, Vidakovic P, Cooney G, et al. Effects of creatine on isometric bench-press performance in resistance-trained humans. *Med Sci Sports Exerc* 2002;34(7):1176-83.

31. Syrotuik DG, Bell GJ. Acute creatine monohydrate supplementation: a descriptive physiological profile of responders vs. nonresponders. *J Strength Cond Res* 2004;18(3):610-7.

32. Green AL, Hultman E, Macdonald IA, Sewell DA, Greenhaff PL. Carbohydrate ingestion augments skeletal muscle creatine accumulation during creatine supplementation in humans. *Am J Physiol* 1996;271(5 pt 1):e821-e826.
33. Adamson JW, Vapnek D. Recombinant erythropoietin to improve athletic performance. *N Engl J Med* 1991;324(10):698-9.
34. Kruse P, Ladefoged J, Nielsen U, Paulev PE, Sørensen JP. beta-Blockade used in precision sports: effect on pistol shooting performance. *J Appl Physiol* (1985) 1986;61(2):417-20.
35. Hoffman JR, Gepner Y, Stout JR, et al.  $\beta$ -Hydroxy- $\beta$ -methylbutyrate attenuates cytokine response during sustained military training. *Nutr Res* 2016;36(6):553-63. doi:10.1016/j.nutres.2016.02.006.
36. Jówko E, Ostaszewski P, Jank M, et al. Creatine and beta-hydroxy-beta-methylbutyrate (HMB) additively increase lean body mass and muscle strength during a weight-training program. *Nutrition* 2001;17(7-8):558-66.
37. Slater G, Jenkins D, Logan P, et al. Beta-hydroxy-beta-methylbutyrate (HMB) supplementation does not affect changes in strength or body composition during resistance training in trained men. *Int J Sport Nutr Exerc Metab* 2001;11(3):384-96.
38. Ransone J, Neighbors K, Lefavi R, Chromiak J. The effect of beta-hydroxy beta-methylbutyrate on muscular strength and body composition in collegiate football players. *J Strength Cond Res* 2003;17(1):34-9.
39. Momaya A, Fawal M, Estes R. Performance-enhancing substances in sports: a review of the literature. *Sports Med* 2015;45(4):517-31. doi: 10.1007/s40279-015-0308-9.

# Elbow Injuries in the Throwing Athlete: A Review

Drew K. Newhoff, MD

Department of Orthopaedics & Rehabilitation, The University of New Mexico Health Sciences Center, Albuquerque, New Mexico

## Abstract

Overhand-throwing motions can create supraphysiologic stresses on the elbow. Repeated stresses often result in overuse injuries affecting the elbow, which are commonly seen in throwing athletes. Noted problems include medial epicondylitis, valgus extension overload, olecranon stress fractures, ulnar neuritis, and damage to the ulnar collateral ligament. Symptoms of pain or numbness at presentation vary in location depending on the injury. Successful diagnosis is typically made using results of physical examinations of elbow, wrist, and arm extensions; results of tests for valgus instability; and findings radiographs can all help indicate the problem. However, pathological features of these injuries are not always clear, which can complete effective treatment. Baseball pitchers are often discussed when investigating overhand-throwing athletes; yet the current review examines players of various overhand-throwing sports to help assess causes, diagnosis, and treatment of related elbow injuries.

## Introduction

The overhand-throwing motion can create supraphysiologic stresses on the elbow, with most injuries considered attritional rather than acute or traumatic.<sup>1</sup> During the acceleration phase of throwing, the elbow reaches an angular velocity of 3000 degrees per second. This motion creates three primary forces across the elbow. A tension force occurs along the medial side of the elbow (ulnar collateral ligament [UCL], flexor-pronator mass), which has been measured up to 64 N. The second force created during throwing is a shear stress in the posterior compartment, owing to excessive valgus moment caused by the angular velocity of the elbow. Shear forces result in excess stress in the posteromedial olecranon and trochlea. Finally, a compression force on the lateral aspect of the elbow is created, balancing the tension on the medial side. Up to 500 N of compression in the radiocapitellar joint has been noted in some studies.<sup>2,3</sup>

Subsequently, repeated stresses may result in overuse injuries affecting the elbow for overhand-throwing athletes. Although throwing athletes are commonly thought of as

baseball pitchers, the current review also examines players of other sports (eg, javelin throw, American football, tennis, and water polo) to help assess a wider spectrum of related elbow injuries. Problems discussed include medial epicondylitis, valgus extension overload (VEO), olecranon stress fractures, ulnar neuritis, and UCL injury.

## Medial Epicondylitis

Medial epicondylitis is the result of overuse of the flexor-pronator mass and can be caused by repetitive throwing. Commonly affected areas include the pronator teres and flexor carpi radialis origins. This inflammation may also result in irritation of the ulnar nerve. Patients typically present with pain over the medial epicondyle. On physical examination, this pain can be reproduced with resisted wrist flexion.

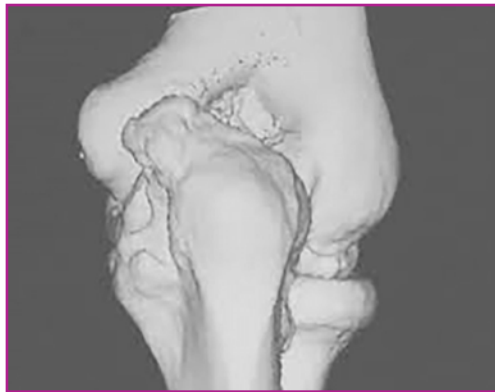This condition is up to five times less common than lateral epicondylitis and often more difficult to treat. First line of treatment should include the use of non-steroidal anti-inflammatory medication and counter-force bracing. Some studies support the use of kinesiotaping for conservative management. Corticosteroid injections may also be considered, which should be performed in the peritendinous and synovial tissues to avoid tendon injury.

Surgical treatment is usually withheld until the patient has undergone 6 months of conservative treatment without success. Operative treatment involves debridement of the flexor-pronator attachment at the medial epicondyle. Most patients experience symptom relief postoperatively, but results can worsen if ulnar nerve injury remains unaddressed.<sup>4</sup>

## Valgus Extension Overload

VEO, also known as pitchers' elbow, is a condition characterized by pathological features in the posterior elbow. VEO is caused by repetitive shear forces during throwing motion. Bony changes, including formation of posteromedial olecranon osteophyte, occur after attenuation of the UCL. Increasing laxity in the UCL places additional stress in the posterior elbow through the throwing motion (Figure 1). Both the olecranon and

the UCL contribute to valgus stability of the elbow. One study<sup>5</sup> found that all pitchers showed reactive changes to the subchondral bone as a result of this activity. Thus, additional instability at the elbow created by UCL injury contributes considerably to the pathological features causing VEO.



**Figure 1.** 3D reconstruction of computed tomography showing the elbow, revealing evidence of valgus extension overload, highlighted by notable posteromedial osteophyte formation on the olecranon.

Patients with VEO typically present with pain in the posterior elbow, particularly in full extension. Baseball pitchers specifically may note pain during the deceleration phase of throwing. On physical examination, these patients have tenderness to palpation in the posteromedial olecranon. Furthermore, baseball pitchers may have crepitus through the range of motion, particularly if loose bodies have formed in the posterior elbow joint. Patients will also have pain with forced elbow extension.

Treatment should include an initial period of rest and trial of non-steroidal anti-inflammatory medication. Baseball pitchers can also be instructed to correct poor technique. Studies have noted certain throwing mechanics may place athletes at higher risk for UCL- and VEO-related injuries. If nonoperative treatment is unsuccessful, patients typically undergo surgical procedure. However, care must be taken to avoid resecting native ulna, which can lead to increased valgus instability at the elbow.<sup>6,7</sup> Use of arthroscopic and open techniques have been described. The procedure consists of debridement of osteophytes and removal of loose bodies.<sup>10</sup>

Special attention must be paid to the UCL during surgical treatment of VEO. Patients with considerable UCL insufficiency are at a high risk for unsuccessful treatment with isolated posterior elbow debridement. Studies have described up to 25% of Major League Baseball pitchers who require UCL reconstruction after undergoing isolated posterior elbow debridement.<sup>8,9</sup>

## Olecranon Stress Fracture

Olecranon stress fracture is a rare baseball-related injury, which may be the result of repetitive shear forces in the posterior elbow similar to that described of VEO. In adolescent patients, traction of the triceps muscle with repetitive throwing can play a role, pulling against the olecranon apophysis. The fracture typically arises from the articular surface, involves the epiphyseal plate, and propagates in a dorsal and proximal direction. Patients present with pain in the posteromedial olecranon when throwing, which is usually relieved with rest. Tenderness and swelling over the olecranon may also be noted. The arm should be tested for signs of valgus instability.

These fractures can often be treated conservatively, with rest and splinting methods. Electrical bone stimulation may also be considered. For patients that do not experience healing in 3 to 6 months, surgical treatment is recommended. A single intramedullary screw across the fracture site or unfused apophysis is usually sufficient for successful treatment.

Patients with olecranon stress fractures related to throwing, like those with VEO, frequently have concomitant UCL or medial epicondyle injury, and special attention should be paid to this diagnosis during workup of these patients.<sup>11,12,13</sup>

## Ulnar Neuritis

Repetitive throwing can result in inflammation of the ulnar nerve. This condition commonly arises with other medial-sided elbow injuries. Patients typically present with numbness in the ulnar nerve distribution after throwing. On physical examination, patients may have a positive Tinel sign at the cubital tunnel. Results of the elbow flexion test are positive when the elbow flexion for 60 seconds reproduces symptoms. Findings of nerve conduction studies may aid in the diagnosis. Similar to ulnar neuritis from other causes, treatment is typically surgical and consists of *in situ* decompression versus transposition. No clear consensus exists regarding optimal treatment. Some authors advocate for more aggressive indications for transposition in throwing athletes owing to the stresses placed at the elbow during the throwing motion, but there is little data to support this.<sup>1,14,15</sup>

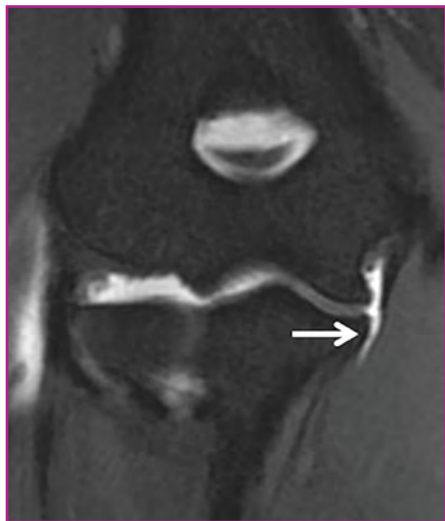## Ulnar Collateral Ligament Injury

Injury to the UCL is caused by overuse resulting from repetitive valgus stress of throwing motions. The late-cocking and early acceleration phases of throwing are most notable for these stresses.

The UCL is composed of three bundles: anterior, posterior, and transverse. The ligament functions to resist valgus and distraction at the elbow joint, in which the anterior bundle provides the most notable contribution. It originates at the medial epicondyle of the humerus and has its attachment at the sublime tubercle of the ulna.

Throwers who injure the UCL may experience a 'pop.' The injury is associated with a loss of velocity and accuracy when throwing. Patients also experience medial-sided elbow pain during the late-cocking and early acceleration phases of throwing. On physical examination, patients have tenderness over the medial epicondyle. The moving valgus stress test of O'Driscoll is the most sensitive examination for diagnosing UCL injury. During the test, the patient's elbow is flexed with the forearm supinated and a valgus stress is delivered by the examiner. The patient is then taken through elbow range of motion. Results are considered positive when the patient experiences pain, instability, or apprehension with the elbow flexed between 80° and 120°.

Radiographs may be obtained during workup but are typically not useful for diagnosis of ligament injury. Gravity stress radiographs may be considered, and medial-joint line widening greater than 3 mm may indicate a UCL injury. Magnetic resonance imaging (MRI) is the most helpful imaging technique, and sensitivity and specificity are increased with addition of arthrogram. A capsular T sign can be appreciated on MRI as contrast leaves the joint (Figure 2).



**Figure 2.** Capsular T-sign on magnetic resonance imaging, indicating ulnar collateral ligament rupture (white arrow).

Surgical treatment of UCL injuries are rare because mostly high-level throwers who wish to continue competitive sports are willing to undergo extensive rehabilitation. The most sizable population available for

study is Major League Baseball pitchers, in which up to 33% of active pitchers have undergone UCL reconstruction. Use of multiple techniques have been described for UCL treatment. In general, reconstruction of the ligament is favored over direct repair. A muscle-slitting approach is also helpful, as this avoids injury to the flexor-pronator mass and the ulnar nerve.

In general, performance of UCL reconstruction has shown successful results. Cain et al<sup>16</sup> reported an 83% return to previous level of competition in the largest series to date. Average time to begin a throwing program postoperatively is 4.4 months, and average time to return to full competition is nearly 12 months.<sup>16</sup> Complications after surgery can be up to 20% but are frequently minor, including transient ulnar neuropraxia. Revision rate has been reported between 1% to 5%, with a 0.5% risk of fracture at the tunnel sites. Results of several studies have suggested no significant difference in outcomes between surgical technique, autograft choice, or patient sport or level of competition.<sup>17</sup> In general, reviews of baseball pitchers returning to competitions have shown an ability of patients to compete at high levels. However, on average, baseball pitchers have a decreased pitch velocity and diminished position-related statistical measures.<sup>18,19</sup> These effects are worse in athletes older than 35 years.<sup>19</sup>

Outcomes for revision UCL reconstruction are generally less successful. Average time to recovery is significantly longer, and rates of return to high levels of competition are lower.<sup>20</sup> Much research is currently being dedicated to preventing these potentially career-ending injuries. Many baseball pitchers use altered throwing mechanics to create additional power during their throwing motion. Early rotation of the torso (before foot strike) has been particularly associated with UCL injury.<sup>21</sup> Pitch velocity alone does not play a factor, but baseball pitchers who throw a high percentage of fastballs are at higher risk for UCL injury, perhaps owing to the higher angular velocity associated with maximum throwing effort.<sup>22</sup> In one study,<sup>22</sup> for every 1% increase in fastball percentage thrown, there was a 2% increased risk of UCL injury. Limitations in glenohumeral passive range of motion has also been implicated.<sup>23</sup>

## Conclusion

Elbow injuries resulting from overhand-throwing motions typically occur over time from repeated stress at the region.<sup>1</sup> Reported problems include medial epicondylitis, VEO, olecranon stress fractures, ulnar neuritis, and damage to the UCL. Pathological features are often unclear for each injury; however, successful diagnosis can often be made when noting symptoms of the patient at

presentation, results of physical examination, and findings of radiographs. For UCL injuries, an MRI is considered the most helpful for diagnosis. Generally, surgeons should be aware that patients with olecranon stress fractures and VEO typically have concomitant UCL or medial epicondyle injuries, which can help with successful diagnosis .

Treatment of each injury is initially conservative, with surgical methods explored if observational techniques are unsuccessful. On the other hand, patients with ulnar neuritis are often treated operatively at first, yet no technique has been proven more effective than another.<sup>1,14,15</sup> Although rare, injury to the UCL is perhaps the most devastating elbow injury of throwing athletes. Baseball pitchers with UCL damage typically undergo successful UCL reconstruction, with minor complications, yet on average have decreased pitch velocity and diminished position-related statistical measures.<sup>18,19</sup>

Overall, successful diagnostic and treatment methods have been established for most elbow injuries associated with throwing athletes. However, further clinical studies on various types of throwing athletes may help illuminate the pathological features of these problems to help return to previous levels of high-competitive activity.

## Funding

The author received no financial support for the research, authorship, and publication of this article.

## Conflict of Interest

The author reports no conflicts of interest.

## References

1. Andrews JR, Cain EL, Dugas JR, Jost PW. Elbow injuries in the throwing athlete. *OrthoInfo*. <http://orthoinfo.aaos.org/topic.cfm?topic=a00644>. Reviewed December 2012. Accessed May 28, 2016.
2. Loftice J, Fleisig GS, Zheng N, Andrews JR. Biomechanics of the elbow in sports. *Clin Sports Med* 2004;23(4):519-30, vii-viii.
3. Werner FW, An KN. Biomechanics of the elbow and forearm. *Hand Clin* 1994;10(3):357-73.
4. Amin NH, Kumar NS, Schickendantz MS. Medial epicondylitis: evaluation and management. *J Am Acad Orthop Surg* 2015;23(6):348-55. doi: 10.5435/JAAOS-D-14-00145.
5. Funakoshi T, Furushima K, Momma D, et al. Alteration of stress distribution patterns in symptomatic valgus instability of the elbow in baseball players: a computed tomography osteoabsorptiometry study. *Am J Sports Med* 2016;44(4):989-94. doi: 10.1177/0363546515624916.
6. Kamineni S, ElAttrache NS, O'driscoll SW, et al. Medial collateral ligament strain with partial posteromedial olecranon resection: a biomechanical study. *J Bone Joint Surg Am* 2004;86-A(11):2424-30.
7. Bell TH, Ferreira LM, McDonald CP, Johnson JA, King GJ. Contribution of the olecranon to elbow stability: an in vitro biomechanical study. *J Bone Joint Surg Am* 2010;92(4):949-57. doi: 10.2106/JBJS.H.01873.
8. Dugas JR. Valgus extension overload: diagnosis and treatment. *Clin Sports Med* 2010;29(4):645-54. doi: 10.1016/j.csm.2010.07.001.
9. Paulino FE, Villacis DC, Ahmad CS. Valgus extension overload in baseball players. *Am J Orthop (Belle Mead NJ)* 2016;45(3):144-51.
10. Byram IR, Kim HM, Levine WN, Ahmad CS. Elbow arthroscopic surgery update for sports medicine conditions. *Am J Sports Med* 2013;41(9):2191-202. doi: 10.1177/0363546513482106.
11. Furushima K, Itoh Y, Iwabu S, Yamamoto Y, Koga R, Shimizu M. Classification of olecranon stress fractures in baseball players. *Am J Sports Med* 2014;42(6):1343-51. doi: 10.1177/0363546514528099.
12. Rettig AC, Wurth TR, Mielsing P. Nonunion of olecranon stress fractures in adolescent baseball pitchers: a case series of 5 athletes. *Am J Sports Med* 2006;34(4):653-6.
13. Fujioka H, Tsunemi K, Takagi Y, Tanaka J. Treatment of stress fracture of the olecranon in throwing athletes with internal fixation through a small incision. *Sports Med Arthrosc Rehabil Ther Technol* 2012;4(1):49. doi: 10.1186/1758-2555-4-49.
14. Elhassan B, Steinmann SP. Entrapment neuropathy of the ulnar nerve. *J Am Acad Orthop Surg* 2007;15(11):672-81.
15. Zlowodzki M, Chan S, Bhandari M, Kalliainen L, Schubert W. Anterior transposition compared with simple decompression for treatment of cubital tunnel syndrome: a meta-analysis of randomized, controlled trials. *J Bone Joint Surg Am* 2007;89(12):2591-8.
16. Cain EL Jr, Andrews JR, Dugas JR, et al. Outcome of ulnar collateral ligament reconstruction of the elbow in 1281 athletes: results in 743 athletes with minimum 2-year follow-up. *Am J Sports Med* 2010;38(12):2426-34. doi: 10.1177/0363546510378100.
17. Erickson BJ, Bach BR Jr, Cohen MS, et al. Ulnar collateral ligament reconstruction: the rush experience. *Orthop J Sports Med* 2016;4(1):2325967115626876. doi: 10.1177/2325967115626876.
18. Keller RA, Steffes MJ, Zhuo D, Bey MJ, Moutzouros V. The effects of medial ulnar collateral ligament reconstruction on Major League pitching performance. *J Shoulder Elbow Surg* 2014;23(11):1591-8. doi: 10.1016/j.jse.2014.06.033.



19. Lansdown DA, Feeley BT. The effect of ulnar collateral ligament reconstruction on pitch velocity in major league baseball pitchers. *Orthop J Sports Med* 2014;2(2):2325967114522592. doi: 10.1177/2325967114522592.
20. Liu JN, Garcia GH, Conte S, ElAttrache N, Altchek DW, Dines JS. Outcomes in revision Tommy John surgery in Major League Baseball pitchers. *J Shoulder Elbow Surg* 2016;25(1):90-7. doi: 10.1016/j.jse.2015.08.040.
21. Douguih WA, Dolce DL, Lincoln AE. Early cocking phase mechanics and upper extremity surgery risk in starting professional baseball pitchers [published erratum in: *Orthop J Sports Med*. 2015 Jun;3(6):2325967115595220]. *Orthop J Sports Med* 2015;3(4):2325967115581594. doi: 10.1177/2325967115581594.
22. Keller RA, Marshall NE, Guest JM, Okoroa KR, Jung EK, Moutzouros V. Major League Baseball pitch velocity and pitch type associated with risk of ulnar collateral ligament injury. *J Shoulder Elbow Surg* 2016;25(4):671-5. doi: 10.1016/j.jse.2015.12.027.
23. Wilk KE, Macrina LC, Fleisig GS, et al. Deficits in glenohumeral passive range of motion increase risk of elbow injury in professional baseball pitchers: a prospective study. *Am J Sports Med* 2014;42(9):2075-81. doi: 10.1177/0363546514538391.

# Current Issues in Treatment of Anterior Shoulder Instability: A Review

Ian Power, MD

Department of Orthopaedics & Rehabilitation, The University of New Mexico Health Sciences Center, Albuquerque, New Mexico

## Abstract

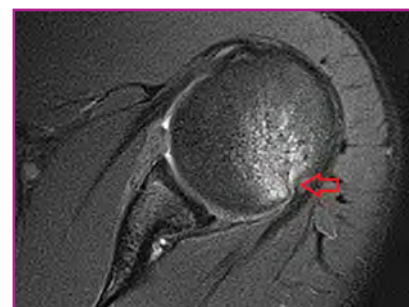Anterior shoulder instability can be problematic in the young, active population, particularly in athletes and military personnel. The shoulder joint is the most frequently dislocated joint, and there is a high rate of dislocation recurrence in younger patients. The stability of the glenohumeral joint is conferred through the bony anatomy and the static and dynamic stabilizers. Recognizing pathological features, identifying glenoid bone loss, and detecting Bankart and Hill-Sachs lesions are key to formulating an appropriate treatment strategy and improving surgical outcomes. Furthermore, the concept of critical bone loss has been refined by looking at subcritical loss. Recent evidence has shown that patients with glenoid bone loss at or above a subcritical level of 13.5% had higher re-dislocation rates, and those patients that did not re-dislocate experienced worse outcomes compared to those without subcritical bone loss. Intraoperative estimations of bone loss may not be always accurate, and advanced preoperative imaging using computed tomography or magnetic resonance imaging can be useful. To help assess successful treatment of anterior shoulder instability, I reviewed glenoid anatomy, injury workup, bone loss, the concept of glenoid track for engaging lesions, determination of bone loss, subcritical bone loss, and surgical treatment. Careful assessment of both types of lesions, the patient's preferred activity level, and postoperative goals allows surgeons to decide between procedures to restore anterior glenoid bone deficits and soft-tissue repair and determine any role for a Remplissage procedure.

## Introduction

Anterior shoulder instability is a problem frequently encountered in young, athletic populations, with a high predominance in men.<sup>1</sup> It is the most frequently dislocated joint, and in this population there is a high risk of recurrence.<sup>1</sup> This frequently dictates operative treatment for stabilization of the shoulder.

Patients with anterior shoulder instability are often aged 15 to 40 years, although any age group can sustain the injury.<sup>2</sup> It has much higher incidence in military populations, ranging 1.69 to 4.35 per 1000 person-years compared to 0.08 to 0.24 per 1000 person-years in the civilian population.<sup>2</sup> In 1923, Bankart described the anteroinferior labral lesion that now bears his name.<sup>2</sup> Surgical treatment originally consisted of open repair, with debate often centering on whether any bony augmentation was needed.<sup>3</sup> Surgical stabilization generally produced favorable results and, with the advent of arthroscopy, this became the primary means of Bankart repair.<sup>3</sup> The efficacy of these repairs has been evaluated and may be affected by patient characteristics.<sup>4</sup> Results of recent studies have added to treatment strategies by determining which patients underwent successful treatment with a stand-alone arthroscopic Bankart repair and which need additional stabilization to reduce the risk of recurrent dislocation.

Estimates on the prevalence of engaging lesions varies widely. Engaging lesions are defined by a Hill-Sachs lesion that engages with the anterior glenoid rim and contributes to subluxation or dislocation (Figure 1).<sup>4,5</sup> Hill-Sachs lesions that are large or close enough to the articular margin may cause the humeral head to lever anteriorly with engagement of the lesion.<sup>4,5</sup> To help assess successful treatment of anterior shoulder instability, I reviewed glenoid anatomy, injury workup, bone loss, the concept of glenoid track, and surgical treatment.



**Figure 1.** Magnetic resonance imaging of a Hill-Sachs lesion with subchondral edema (red arrow). This is classified as an “on-track” lesion and not expected to engage. Just 4 mm, or 17% anterior glenoid bone loss, would convert this to an engaging, “off-track” lesion that requires treatment.

## Glenoid Anatomy

Glenoid anatomy also plays a role in anterior shoulder instability.<sup>4</sup> The shallow ball and socket anatomy of the glenohumeral joint is better described as a golf ball on a tee. Coupled with the degree of freedom of rotation, this joint is more susceptible to instability than others in the body. Normal anatomic stabilizers include both static stabilizers, including the morphological features of the glenoid, the labrum, glenohumeral ligaments and negative pressure of the joint, whereas dynamic stabilizers include the rotator cuff and long head of the biceps. Multiple glenohumeral ligaments resist translation at varying angles of shoulder abduction. Bankart tears of the labrum can result in loss of stability through loss of the bumper mechanism and detachment of the anterior-inferior glenohumeral ligament.

Glenohumeral joint congruence depends on the depth of the glenoid and the labrum, and the arc length.<sup>4,6</sup> The labrum and glenoid each contribute 50% of the depth. The effective glenoid arc is the available articular surface for humeral head compression. This concept was later advanced when describing the glenoid track. Shortening this arc leads to less available motion before instability occurs. The balance stability angle is defined as the angle from the center of the humeral head and the center of the glenoid to the edge of the glenoid, and is approximately 18° anteriorly. A total force vector on the humeral head greater than 18° can cause a loss of bony constraint of the humeral head and risk of anterior dislocation if the soft-tissue restraints fail.

Loss of glenoid bone results in a shallower glenoid surface with less constraint and a shorter arc of motion before the Hill-Sachs lesion engages.<sup>7</sup> This often causes a sense of subluxation or a fulcrum for anterior dislocation. The chance of engagement and dislocation are increased when the shoulder is abducted 90° while flexed and with varying external rotation.<sup>7</sup> This athletic position is most often encountered in athletes who participate in overhead-throwing sports.<sup>2</sup>

## Workup

Thorough workup begins with a detailed history about instability events, number of events, arm position or activity during instability, and type of physical activity or sports.<sup>8</sup> Findings of physical examinations help support the diagnosis of anterior instability. Standard examination protocols should include range of motion, apprehension and relocations tests, which specifically focus on anterior dislocation. The load-and-shift test estimates the degree of translation and lesions that will engage the posterior humeral head on the anterior glenoid and whether they

are reducible. Additionally, the sulcus sign, an indicator of inferior laxity, and generalized ligamentous laxity with the Beighton Score may help with the diagnosis.

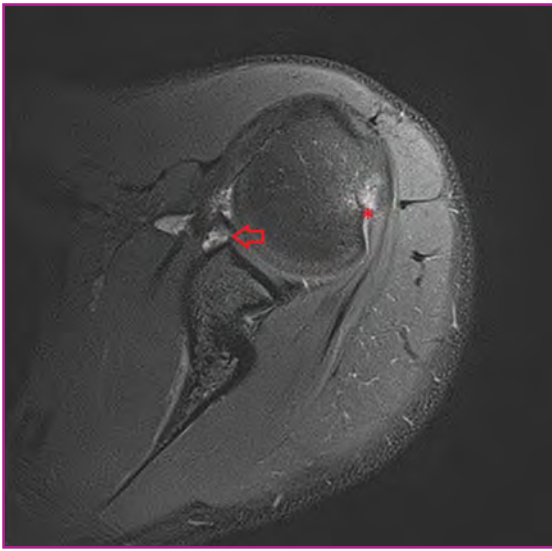
## Glenoid Bone Loss

Estimates of the degree of glenoid bone loss have varied considerably. Sugaya et al<sup>9</sup> felt that glenoid bone loss was significant in patients with recurrent anterior dislocations. With 50% of the fragment type, and 40% erosion type, that left 10% without any glenoid bone loss.

Burkhart and De Beer<sup>4</sup> discussed the concept of “significant bone loss.” They described traumatic glenoid bone loss of 25%, below the mid-glenoid notch, which has been noted as creating an inverted pear shape. This traumatic loss lead to greater instability than an isolated Bankart lesion (Figure 2). They determined that the key to arthroscopic Bankart repair was proper placement of the labrum on the glenoid. If fixed laterally on the glenoid rim, rather than medially, it was equivalent to an open repair.

Recurrence rates after arthroscopic stabilization are dependent on bone loss and type of activity. This is particularly true for athletes in contact-based sports. Contact athletes had a higher recurrence rate with a bony defect (up to 89%) than without (down to 6.5%).<sup>4</sup> For non-contact athletes, two-thirds with a bony defect had recurrence, whereas those with an intact glenoid had a 4% recurrence rate that was comparable to an open Bankart repair.<sup>4</sup> Burkhart and De Beer<sup>4</sup> also found that 100% of patients with an engaging Hill-Sachs had recurrence.<sup>4</sup> This statistic helped lead to the general consensus that patients with more than 25% glenoid bone loss might require an additional procedure to ensure stabilization.<sup>4</sup>

Quantifying the amount of glenoid bone loss helps determine whether Bankart repair may be successful or should be augmented or replaced by another procedure. Antero-inferior bone loss of 21% of the superior-inferior length has been shown to predict failure of Bankart repair alone.<sup>10</sup> Previously, the amount of significant bone loss was thought to be about one-third of the glenoid width.<sup>10</sup> Itoi et al<sup>10</sup> found this fraction was more likely to be as little as one-fifth of the width and theorized that glenoid bone loss may also lead to instability owing to internal rotation and laxity of the anterior ligamentous constraint. Yamamoto et al<sup>11</sup> defined this as 25% of the loss of width (19% loss of height), representing a 26% loss in surface area. Additionally, the length may be easier to measure because the width can be altered by bone loss.<sup>11</sup> Bankart repair can decrease terminal external rotation, losing about 25° for every centimeter of anterior capsular imbrication. This is important in throwing athletes, and consideration to bony treatment of the glenoid may be more important in these patients.<sup>10</sup>



**Figure 2.** Axillary T2-weighted magnetic resonance imaging, showing the Bankart lesion, an anterior-inferior labrum tear (red arrow). A moderate Hill-Sachs lesion is also present (red asterisk).

## Glenoid Track Concept

The concept of the glenoid track is a continuation of the idea of an engaging lesion. It defines the articular contact of the humeral head on the glenoid. An intact glenoid track often indicates a stable glenohumeral joint. The glenoid track is 84% of the glenoid width, which is equivalent to the medial margin of the humeral head contact area to the medial margin of the rotator cuff attachment at 90° of abduction.<sup>12</sup>

The area of contact between the glenoid and the humeral head changes with motion of the joint. As the humeral head abducts the posterior humeral contact area shifts from inferomedial to superolateral.<sup>12</sup> If the Hill-Sachs lesion is within the track, or “on-track,” it will not override the anterior glenoid rim and engage.<sup>12</sup> An “off track” lesion risks overriding and engagement.<sup>12</sup> Thus, the depth of the Hill-Sachs lesion is not as important as its medial-most margin.

Likewise, glenoid bone loss directly narrows the glenoid track and risks engagement and dislocation.<sup>12</sup> The humeral portion of the track should be measured from the lateral margin (medial footprint of rotator cuff) because the posterolateral cartilage may not be a reliable marker.<sup>12</sup> This concept has been used to unify the issue of bipolar lesions and how to address them.<sup>12</sup> Although studies with computed tomography (CT) have helped demonstrate glenoid bone loss and Hill-Sachs lesions, Omori et al<sup>13</sup> used magnetic resonance imaging (MRI) with similar findings and noted that the glenoid track was 83% of the glenoid width.

Giacomo et al<sup>5</sup> noted that arthroscopic evaluation could

be problematic. Evaluation of engaging lesions before soft-tissue labral repair would not indicate true stability because of lack of capsular, labral, and ligamentous stability. Evaluation post-repair risked damage to the repair. They advocated for more rigorous classification and preoperative measurement with CT scan and arthroscopic measurement. By calculating the diameter of the glenoid (D) minus the amount of bone loss (d), the width of the glenoid track (GT) is determined ( $GT = 0.83[D-d]$ ). The Hill-Sachs Interval (HSI) is then determined, which is the width of the Hill-Sachs lesion (HS) plus the width of the bone bridge (BB) between the rotator cuff attachments and the lateral aspect of the Hill-Sachs lesion. ( $HSI = HS + BB$ ). If the HSI value is greater than that of GT, the Hill-Sachs lesion is off-track or engaging; if less, the Hill-Sachs lesion is on-track or non-engaging.<sup>5</sup> This can be confirmed arthroscopically by measuring the anterior and posterior rims of the glenoid from the center of the bare spot and measuring the medial edge of the Hill-Sachs lesion.

To clarify the presence of engaging lesions that needed to be treated, Kurokawa et al<sup>14</sup> reviewed 100 consecutive patients with primary dislocation, unilateral disease, and CT scans. About 86% of patients had glenoid bone loss of 9% (SD, 6%) and 94% had a Hill-Sachs lesion, with a medial margin of 69% (SD, 20%) of the glenoid track. The study noted that 7% of patients had engaging lesions and all had glenoid bone loss, without which there would not have been engagement. In these seven patients, the Hill-Sachs lesions were either wide and large or narrow and medial; additionally, the Hill-Sachs lesion was noted to be 114% (SD, 7%; range, 100%-121%) of the glenoid track width and the glenoid bone defect was 20% (SD, 6%; range, 12%-27%).

## Determination of Bone Loss

Gyftopoulos et al<sup>15</sup> correlated MRI measurements with arthroscopic findings. Glenoid bone loss on MRI was measured with a best fit circle. Thirteen of 18 lesions on MRI were classified as off-track, with a sensitivity of 72.2%. Fifty-one lesions were classified as on-track on MRI, for a specificity of 87.9%. Positive predictive value was 61.1% and negative predictive value was 87.9%. In comparing CT measurements to MRI measurements, Huijsmans et al<sup>16</sup> found no difference between CT or MRI and digital-photograph measurements; however, MRI measurements tended to be larger and had a larger standard deviation.<sup>16</sup>

Chuang et al<sup>17</sup> retrospectively viewed CT scans of shoulders to correlate the arthroscopic findings compared to the injured and uninjured sides. They calculated the glenoid index (1.0 minus the percent loss) and found that patients treated arthroscopically had a glenoid

index of 0.85 to 0.95. Of those repaired with the Latarjet procedure, a total of 92% were correctly identified by CT, with a glenoid index of 0.58 to 0.74. Glenoid index was determined by the measured glenoid compared to the predicted width, and a glenoid index > 0.75 could be treated arthroscopically.

Determining the location of the bone loss is also important to guide treatment, especially when using arthroscopic measurement. One study<sup>18</sup> retrospectively reviewed CT scans and noted that the defects were at 3:01 on a clock face from the superior glenoid, which correlated to 4:17 in relation to the body. Ji et al<sup>19</sup> reported similar findings with defects at 3:20 on the glenoid. Altan et al<sup>20</sup> questioned the accuracy of a single linear CT measurement. The measurement of the diameter at 4:00, referenced from the superior glenoid, was the most accurate for smaller overall loss (6%). There was difficulty in measuring increasing values. As the loss grew greater than 14%, it showed no correlation, potentially owing to biconcave-shaped bone loss. Averaging multiple measurements of diameter improved the correlation, but the results also revealed that use of width can complicate accurate measurements.

Although correlation with arthroscopy has been considered reliable, two studies called this into question. Kralinger et al<sup>21</sup> found that the bare spot was often not present, severely deformed owing to degenerative disease, or eccentric. Eccentricity was caused by the inferior radius and differences between the anterior and posterior radii, which placed the bare spot closer to the anterior rim in intact specimens. Such a placement may lead to overestimation of bony loss when measuring arthroscopically. Aigner et al<sup>22</sup> confirmed that the bare spot was not concentrically located along the inferior margin or referencing anterior or posterior. More recently, Bakshi et al<sup>23</sup> reinforced such results by describing four different types of similar CT measurements that arthroscopy overestimated the amount of bone loss.<sup>23</sup> Not all patients had a CT scan, but Auffarth et al<sup>24</sup> showed multiple missed glenoid rim fractures and Hill-Sachs lesions between different observers on radiographs. Even dedicated and appropriate films can miss these. Because of the difficulty in determining treatment even with CT or MRI in conjunction with arthroscopy, surgeons should consider use of advanced imaging in determining glenoid bone loss.

### Subcritical Bone Loss

Shaha et al<sup>25</sup> advanced the idea of glenoid bone loss through impaction by analyzing subcritical bone loss. Initial results showed that patients who underwent successful arthroscopic repair had an average of 14.5%

bone loss, whereas patients with unsuccessful treatments had an average of 21% bone loss. Subcritical thresholds were calculated with a 25% risk of dislocation after arthroscopic repair with more than 7% bone loss and a 95% risk above a threshold of 17.1%.

A follow-up study divided patients into quartiles based on bone loss and correlated preoperative MRI using the Western Ontario Stability Index (WOSI) to determine risks of failure.<sup>26</sup> In this military population, most patients (89%) had some bone loss and fewer (19%) had critical bone loss. Patients with critical bone loss had a 27.8% risk of undergoing unsuccessful treatment, whereas those with less than critical loss had a 7.3% risk. Using a sub-critical threshold of 13.5%, the study found a much higher rate of dislocation above this threshold (21.9% to 4.9%) and a significant difference in WOSI scores. When excluding unsuccessful treatments, patients with more than 13.5% bone loss had a significantly lower WOSI score. The findings showed unacceptable results with subcritical bone loss, even without re-dislocation, which supports that bone loss is better viewed on a continuum rather than a strict cutoff to help guide treatment.

### Surgical Treatment

Treatment options have typically involved activity modification, bracing, and physical therapy.<sup>27</sup> Surgical treatments include arthroscopic anteroinferior capsulolabral repairs with or without capsular shift, anatomic versus non-anatomic bony augmentation procedures guided by the size of the glenoid and humeral bone deficit, and posterior capsulodesis and rotator cuff tenodesis procedures of the Hill-Sachs lesion (Remplissage procedure).<sup>27</sup> Using cadavers, one study showed that restoring glenoid concavity also restored translation stability to that of the intact joint or greater.<sup>11</sup>

### Latarjet Transfer

Latarjet transfer uses a sling from the conjoined tendon, capsular augmentation and bone block from the corocoid to help restore glenoid loss and confer anterior stability.<sup>27</sup> Mook et al<sup>27</sup> retrospectively reviewed 35 patients who had a Latarjet procedure for treating instability and calculated the anticipated postoperative glenoid track. Eight patients had recurrent instability, with four (50%) having off-track lesions. Three of the patients with unstable shoulders underwent revision treatment, and all three had off-track lesions. Of the on-track lesions, four of 25 were unstable. Subsequently, off-track lesions were four times more likely to be unstable after Latarjet stabilization. Yet the results should be interpreted carefully. Five patients in the

unsuccessful-treatment group had subluxation but not frank dislocation. Additionally, the sling effect after Latarjet reconstruction can add stability and soft-tissue constraint beyond restoring glenoid depth and arc length.<sup>27</sup>

Yang et al<sup>28</sup> reviewed modified Latarjet stabilization and evaluated glenoid bone loss and engaging lesions. All patients had engaging lesions at arthroscopy. The group with less than 25% glenoid bone loss had improved motion and WOSI scores. This group had fewer revisions, but this was not statistically significant.

### *Remplissage Procedure*

To address off-track lesions, useful techniques to prevent the lesion from engaging include bone grafting and Remplissage procedure to fill in the defect. Warner et al<sup>29</sup> reported on using iliac crest autograft in patients who underwent unsuccessful treatment with a previous Bankart repair. Despite a small loss of motion, all patients returned to sports-related activity such as professional-level, contact-based sports. Healing was noted on postoperative radiographs and CT.

Zhu et al<sup>30</sup> reported promising results with the Remplissage procedure used in 49 patients, all of whom had engaging lesions and less than 25% glenoid loss. There was a single re-dislocation from new trauma, two subluxations, and one with apprehension. Including these four patients, the failure rate was 8.2% (but 48 of 49 reported satisfaction with treatment). Most patients (71.4%) returned to preoperative levels of sports participation.

One study<sup>31</sup> reported long-term follow-up on the Remplissage procedure alone used in 59 patients with less than 25% glenoid bone loss. Findings of the MRI were used to diagnose Hill-Sachs lesions, but nine patients were not diagnosed successfully (all had glenoid bone loss). Recurrent instability was noted in 4.4% of patients after trauma during sports. Some (10.2%) had pain, apprehension, or did not return to sports but showed no signs of persistent instability. No loss of motion was noted.

### *Postoperative Results*

Because many patients are athletes, the question of returning to sports is important to consider in postoperative follow-up. A cohort of patients who underwent the Remplissage procedure had a 12% re-dislocation rate, in which 6% were traumatic and 6% were atraumatic.<sup>32</sup> All underwent a revision procedure and had no further dislocations. Many patients (90%) were satisfied to very satisfied after operative treatment, and 70% expressed that the treatment greatly improved their quality

of life. Almost all of them returned to sports or work, and 85% were satisfied with their level of participation. However, 69% were throwing athletes and two-thirds had throwing issues. This group had an average loss of 4.8° of external rotation, and most commonly had trouble with windup or loss of velocity. Overhead athletes returned to sports activity, but throwing athletes were less successful in returning and showed that greater than four dislocations preoperatively may increase the risk of postoperative dislocation. Although a trend was noted, patients with revisions did not have a significantly higher rate of dislocation than those who underwent only one procedure.

Comparing postoperative outcomes between primary arthroscopic Remplissage versus revision procedure, McCabe et al<sup>33</sup> found that the decision to perform a Remplissage procedure was not made until intraoperatively in almost half of patients, using the bare spot method. This illustrated the need for advanced imaging and preoperative planning. No difference was noted preoperatively between the primary and revision group. The primary group had no dislocations after repair. The re-dislocations all happened in the revision group, accounting for almost one-third of that group, and all were because of new traumatic events.

When comparing postoperative outcomes of Latarjet and Remplissage biomechanically, both restored stiffness to near preoperative levels.<sup>34</sup> Despite small difference in motion, no significant difference was found compared to the intact specimens.<sup>34</sup> A secondary measure showed Latarjet with fewer dislocations than the Remplissage, but this was not significant as the study was underpowered.<sup>34</sup>

### **Conclusion**

In a young population, anterior shoulder disability is a notable problem that limits activity.<sup>4</sup> Treatment of the unstable shoulder, including complex groups of recurrent instability after primary stabilization, overhead athletes and contact athletes, should involve careful preoperative planning and intraoperative decision making.<sup>5</sup> The use of CT or MRI preoperatively should be seriously considered to evaluate not only soft-tissue damage, but also glenoid bone defects and the medial extent of any Hill-Sachs lesion to determine whether it is on- or off-track.<sup>15,17</sup> This objective planning is still corroborated by intraoperative evaluation and specifics of each patient.<sup>21-23</sup>

Using the following algorithm can help guide surgical treatment. Treatment should center on first evaluating bone loss and on-track or off-track lesions, and categorizing them into four groups. Patients with less than 20% bone loss and an on-track lesions can be treated with arthroscopic Bankart repair alone. Usually, these are small Hill-Sachs lesions. If the lesion is off-track, then

a Remplissage procedure should be added. For glenoid bone loss greater than 25%, on-track lesions can be treated with a Latarjet procedure. For off-track lesions, the lesion should be re-evaluated after Latarjet. If the lesion engages, then humeral-sided treatment such as a Remplissage or allografting to address the lesion, converting it to an on-track lesion should be considered.<sup>5</sup> Furthermore, the idea of subcritical bone loss, along with individual factors, should help guide the algorithm.

Some of these specific populations who often present with anterior shoulder instability include overhead-throwing athletes who may lose external rotation following Remplissage.<sup>32</sup> This can make an otherwise successful operative treatment less desirable because it may limit return to activity. Depending on goals, a Latarjet procedure may be a more appropriate treatment option. Additionally, there is an overall trend toward unsuccessful outcomes of revisions, suggesting that aggressive surgical treatment for these patients, may be beneficial.<sup>27, 28</sup> Considering each patient's goals as well as findings during preoperative evaluation and work-up can help the surgeon plan and perform an appropriate stabilization procedure, increasing the likelihood of returning the patient to prior levels of activity.

## Funding

The author received no financial support for the research, authorship, and publication of this article.

## Conflict of Interest

The author reports no conflicts of interest.

## References

1. Zacchilli MA, Owens BD. Epidemiology of shoulder dislocations presenting to emergency departments in the United States. *J Bone Joint Surg Am* 2010;92(3):542-9. doi: 10.2106/JBJS.I.00450.
2. Bankart, ASB. Recurrent or habitual dislocation of the shoulder-joint. *Br Med J* 1923;2(3285):1132-3.
3. Rowe CR, Patel D, Southmayd WW. The Bankart procedure: a long-term end-result study. *J Bone Joint Surg Am* 1978 Jan;60(1):1-16.
4. Burkhart SS, De Beer JF. Traumatic glenohumeral bone defects and their relationship to failure of arthroscopic Bankart repairs: significance of the inverted-pear glenoid and the humeral engaging Hill-Sachs lesion. *Arthroscopy* 2000;16(7):677-94.
5. Di Giacomo G, Itoi E, Burkhart SS. Evolving concept of bipolar bone loss and the Hill-Sachs lesion: from “engaging/non-engaging” lesion to “on-track/off-track” lesion. *Arthroscopy* 2014;30(1):90-8. doi: 10.1016/j.arthro.2013.10.004.
6. Howell SM, Galinat BJ. The glenoid-labral socket: a constrained articular surface. *Clin Orthop Relat Res* 1989;(243):122-5.
7. Hill HA, Sachs MD. The grooved defect of the humeral head: a frequently unrecognized complication of dislocations of the shoulder joint. *Radiology* 1940;35(6):690-700.
8. Hovelius L, Rahme H. Primary anterior dislocation of the shoulder: long-term prognosis at the age of 40 years or younger. *Knee Surg Sports Traumatol Arthrosc* 2016;24(2):330-42. doi: 10.1007/s00167-015-3980-2.
9. Sugaya H, Moriishi J, Dohi M, Kon Y, Tsuchiya A. Glenoid rim morphology in recurrent anterior glenohumeral instability. *J Bone Joint Surg Am* 2003;85-A(5):878-84.
10. Itoi E, Lee SB, Berglund LJ, Berge LL, An KN. The effect of a glenoid defect on anteroinferior stability of the shoulder after Bankart repair: a cadaveric study. *J Bone Joint Surg Am* 2000;82(1):35-46.
11. Yamamoto N, Muraki T, Sperling JW, et al. Stabilizing mechanism in bone-grafting of a large glenoid defect. *J Bone Joint Surg Am* 2010;92(11):2059-66. doi: 10.2106/JBJS.I.00261.
12. Yamamoto N, Itoi E, Abe H, et al. Contact between the glenoid and the humeral head in abduction, external rotation, and horizontal extension: a new concept of glenoid track. *J Shoulder Elbow Surg* 2007;16(5):649-56.
13. Omori Y, Yamamoto N, Koishi H, et al. Measurement of the glenoid track in vivo as investigated by 3-dimensional motion analysis using open MRI. *Am J Sports Med* 2014;42(6):1290-5. doi: 10.1177/0363546514527406.
14. Kurokawa D, Yamamoto N, Nagamoto H, et al. The prevalence of a large Hill-Sachs lesion that needs to be treated. *J Shoulder Elbow Surg* 2013;22(9):1285-9. doi: 10.1016/j.jse.2012.12.033.
15. Gyftopoulos S, Beltran LS, Bookman J, Rokito A. MRI evaluation of bipolar bone loss using the on-track off-track method: a feasibility study. *AJR Am J Roentgenol* 2015;205(4):848-52. doi: 10.2214/AJR.14.14266.
16. Huijsmans PE, Haen PS, Kidd M, Dhert WJ, van der Hulst VP, Willems WJ. Quantification of a glenoid defect with three-dimensional computed tomography and magnetic resonance imaging: a cadaveric study. *J Shoulder Elbow Surg* 2007;16(6):803-9.
17. Chuang TY, Adams CR, Burkhart SS. Use of preoperative three-dimensional computed tomography to quantify glenoid bone loss in shoulder instability. *Arthroscopy* 2008;24(4):376-82. doi: 10.1016/j.arthro.2007.10.008.

18. Saito H, Itoi E, Sugaya H, Minagawa H, Yamamoto N, Tuoheti Y. Location of the glenoid defect in shoulders with recurrent anterior dislocation. *Am J Sports Med* 2005;33(6):889-93.
19. Ji JH, Kwak DS, Yang PS, Kwon MJ, Han SH, Jeong JJ. Comparisons of glenoid bony defects between normal cadaveric specimens and patients with recurrent shoulder dislocation: an anatomic study. *J Shoulder Elbow Surg* 2012;21(6):822-7. doi: 10.1016/j.jse.2011.10.016.
20. Altan E, Ozbaydar MU, Tonbul M, Yalcin L. Comparison of two different measurement methods to determine glenoid bone defects: area or width? *J Shoulder Elbow Surg* 2014;23(8):1215-22. doi: 10.1016/j.jse.2013.11.029.
21. Kralinger F, Aigner F, Longato S, Rieger M, Wambacher M. Is the bare spot a consistent landmark for shoulder arthroscopy? A study of 20 embalmed glenoids with 3-dimensional computed tomographic reconstruction. *Arthroscopy* 2006;22(4):428-32.
22. Aigner F, Longato S, Fritsch H, Kralinger F. Anatomical considerations regarding the "bare spot" of the glenoid cavity. *Surg Radiol Anat* 2004;26(4):308-11.
23. Bakshi NK, Patel I, Jacobson JA, Debski RE, Sekiya JK. Comparison of 3-dimensional computed tomography-based measurement of glenoid bone loss with arthroscopic defect size estimation in patients with anterior shoulder instability. *Arthroscopy* 2015;31(10):1880-5. doi: 10.1016/j.arthro.2015.03.024.
24. Auffarth A, Mayer M, Kofler B, et al. The interobserver reliability in diagnosing osseous lesions after first-time anterior shoulder dislocation comparing plain radiographs with computed tomography scans. *J Shoulder Elbow Surg* 2013;22(11):1507-13. doi: 10.1016/j.jse.2013.04.020.
25. Shaha SH, Cook JB, Bottoni CR, et al. "Subcritical" glenoid bone loss increases redislocation rates in primary arthroscopic Bankart repair [AOSSM abstract]. *Orthop J Sports Med* 2014;2(7)(suppl 2):1s. doi: 10.1177/2325967114S00025.
26. Shaha JS, Cook JB, Song DJ, et al. Redefining "critical" bone loss in shoulder instability: functional outcomes worsen with "subcritical" bone loss. *Am J Sports Med* 2015;43(7):1719-25. doi: 10.1177/0363546515578250.
27. Mook WR, Petri M, Greenspoon JA, Horan MP, Dornan GJ, Millett PJ. Clinical and anatomic predictors of outcomes after the Latarjet procedure for the treatment of anterior glenohumeral instability with combined glenoid and humeral bone defects. *Am J Sports Med* 2016;44(6):1407-16. doi: 10.1177/0363546516634089.
28. Yang JS, Mazzocca AD, Cote MP, Edgar CM, Arciero RA. Recurrent anterior shoulder instability with combined bone loss: treatment and results with the modified Latarjet procedure. *Am J Sports Med* 2016;44(4):922-32. doi: 10.1177/0363546515623929.
29. Warner JJ, Gill TJ, O'hollerhan JD, Pathare N, Millett PJ. Anatomical glenoid reconstruction for recurrent anterior glenohumeral instability with glenoid deficiency using an autogenous tricortical iliac crest bone graft. *Am J Sports Med* 2006;34(2):205-12.
30. Zhu YM, Lu Y, Zhang J, Shen JW, Jiang CY. Arthroscopic Bankart repair combined with remplissage technique for the treatment of anterior shoulder instability with engaging Hill-Sachs lesion: a report of 49 cases with a minimum 2-year follow-up. *Am J Sports Med* 2011;39(8):1640-7. doi: 10.1177/0363546511400018.
31. Wolf EM, Arianjam A. Hill-Sachs remplissage, an arthroscopic solution for the engaging Hill-Sachs lesion: 2- to 10-year follow-up and incidence of recurrence. *J Shoulder Elbow Surg* 2014;23(6):814-20. doi: 10.1016/j.jse.2013.09.009.
32. Garcia GH, Wu HH, Liu JN, Huffman GR, Kelly JD 4th. Outcomes of the remplissage procedure and its effects on return to sports: average 5-year follow-up. *Am J Sports Med* 2016;44(5):1124-30. doi: 10.1177/0363546515626199.
33. McCabe MP, Weinberg D, Field LD, O'Brien MJ, Hobgood ER, Savoie FH 3rd. Primary versus revision arthroscopic reconstruction with remplissage for shoulder instability with moderate bone loss. *Arthroscopy*. 2014 Apr;30(4):444-50. doi: 10.1016/j.arthro.2013.12.015. PubMed PMID: 24680304.
34. Degen RM, Giles JW, Johnson JA, Athwal GS. Remplissage versus Latarjet for engaging Hill-Sachs defects without substantial glenoid bone loss: a biomechanical comparison. *Clin Orthop Relat Res* 2014;472(8):2363-71. doi: 10.1007/s11999-013-3436-2.



# Antegrade Nailing of Femur Shaft Fractures: A Review

Thomas A. DeCoster, MD; Shahram Bozorgnia, MD<sup>a</sup>; Samer Kakish, MD, FRCS  
Department of Orthopaedics & Rehabilitation, The University of New Mexico Health Sciences Center,  
Albuquerque, New Mexico

## Changed Affiliation

<sup>a</sup>Department of Orthopaedic Surgery, Medical College of Georgia, Augusta University, Augusta, Georgia

## Abstract

Rigid intramedullary (IM) nailing is an effective procedure for treating fractures of the femoral shaft. Despite the existence of alternative devices and techniques (eg, unreamed nails, flexible nails, plates, external fixation, and traction), the use of rigid reamed nails has shown excellent healing rates, return of function, alignment, and low complications. This type of nail has been used in an antegrade approach to the entry site of the fracture, resulting in successful treatment. We describe indications, contraindications, and surgical techniques of antegrade IM nailing associated with our personal experience and published results. We provide pearls and pitfalls to assist orthopaedic surgeons in the effective implementation of this approach. A complete understanding and awareness of the various techniques related to antegrade IM nailing can help successfully treat most femoral shaft fractures in adults.

## Introduction

Reamed, locked, rigid intramedullary (IM) nailing can effectively treat most fractures of the femoral shaft.<sup>1</sup> IM nailing has allowed stabilization of the bone without direct exposure of the fracture site, thus preserving the soft-tissue integrity and healing potential of the region around the fracture.<sup>1</sup> The procedure has also restored length, alignment, and rotation of fractured bones, with rapid return of function and early, reliable healing.<sup>2-6</sup> The nail is a load-sharing device that allows cyclic loading with ambulation and thus low risk of implant failure. Use of special instrumentation has reduced surgical exposure and operating times.<sup>7</sup>

Alternative treatment options include use of unreamed nails, flexible nails, and plates; external fixation; and traction.<sup>8</sup> However, use of rigid reamed nails generally

results in improved healing rate, return of function, bone alignment, and postoperative complications.<sup>9,10</sup> Alternative techniques are reserved for specialized situations. Since the introduction of medullary fixation by Küntscher in 1939 at the University of Hamburg, associated techniques have been refined.<sup>11</sup>

For decades, physicians successfully used antegrade IM nailing through the piriformis fossa at the junction of the greater trochanter and neck of the femur.<sup>12</sup> The piriformis entry site is co-linear with the medullary canal of the femur shaft and was appropriate with use of large diameter, open section, stiff, straight nails.<sup>11,13</sup> To provide better control of nail rotation and length, locking screws were developed and allowed use of nails that are flexible, smaller in diameter, thinner walled, closed section, and curved.<sup>11,13</sup> This change in nail design allowed easy surgical access to the tip of the greater trochanter, as opposed to the piriformis fossa.<sup>14-17</sup>

Subsequently, the trochanteric entry site has become a widely used approach for antegrade IM nailing, although the piriformis entry point is preferred by some providers and in special circumstances.<sup>18</sup> Starr et al<sup>19</sup> reported no difference between the two entry points in union rate, blood loss, intra- and postoperative complications, and long-term functional outcome scores. Ricci et al<sup>15</sup> noted that use of a trochanter entry-point nail with a lateral bend, compared to piriformis entry-point nails, resulted in decreased fluoroscopy and operating times (especially when used in patients with large body habitus) and decreased risk of heterotopic ossification (15% vs 21%). A study by Tupis et al<sup>16</sup> advised against use of a straight nail in the greater trochanter owing to increased strain levels and thereby potential iatrogenic fracture. The study also reported an increase in varus malalignment when using a straight nail with a trochanteric entry site. The piriformis entry site is much closer to the medial femoral circumflex artery than the trochanteric entry point. Owing to the

development of avascular necrosis of the femoral head, using the piriformis entry site in adolescents is avoided.<sup>20,21</sup>

In the current paper, we combine the results of our experience with those of published studies. We describe the indications, contraindications, and current techniques for use of antegrade IM nailing of femoral shaft fractures. We also examine differences between the piriformis and trochanteric entry sites. Our review of surgical technique includes positioning, incision, entry site, fracture reduction, reaming, nail insertion, locking screws, wound closure, and postoperative management. We present pearls and pitfalls of antegrade IM nailing to assist orthopaedic surgeons in effectively using the technique for treating femur shaft fractures.

## Indications and Contraindications

Table 1 shows general indications, general contraindications, and relative contraindications of antegrade approach for treating femur shaft fractures with IM nailing.<sup>22</sup>

## Surgical Technique

### Positioning

Antegrade IM nailing can be performed in the supine or lateral position. The supine position is easier to set up but the entry site can be difficult to access due to the soft tissue and chest wall. Lateral position is more complicated for airway access for anesthesia.<sup>23</sup> It is also

more difficult to assess rotational reduction in the lateral position, and fluoroscopic visualization of the entry site is more difficult.<sup>23,24</sup> The lateral position requires more time to set up, but reaming and nail insertion are much easier.<sup>25</sup> Gravity retracts the soft tissue and the chest is far from the entry-site path.<sup>25</sup> Hip adduction to gain proximal femur access is facilitated. The choice between a supine or lateral positioning remains primarily based on individual preference. The decision is influenced by the fracture pattern and the patient's other associated injuries.<sup>23,24</sup>

A study by Firat et al<sup>25</sup> reported less operating time and fluoroscopy time with use of a supine approach. Lateral positioning has been associated with a higher risk of external rotation deformity, with more difficult reductions of comminuted fractures.<sup>26</sup> Apostle et al<sup>23</sup> reported no difference between the two with regards to mortality or admission to the intensive care unit (ICU) in patients with an injury severity score of  $\geq 18$ . This study, however, reported that in a subgroup of patients who had an abbreviated chest injury score of  $\geq 3$ , use of intraoperative lateral positioning had a significant protective effect against ICU admission. This was thought to be caused by a greater lung functional residual capacity in the lateral position compared to the supine position.

The patient is placed on a fracture table and lies with adduction of the trunk and affected extremity. The unaffected limb is moved out of the way of the fluoroscope by extending or flexing and abducting at the hip. Traction is applied through a skeletal pin or foot holder against a perineal post.

For lateral position IM nailing, the bovie ground pad is

General indication <sup>a</sup>	General contraindication	Relative contraindication (to antegrade nailing)
Aged 18 years and older (almost always)	Aged 11 years and younger <sup>c</sup>	Severe open fractures <sup>c</sup>
Aged 14 to 18 years	Active infection	Severe soft-tissue injury of hip
Shaft with distal or proximal extension	Disorders (eg, osteopoetrosis) that prevent nail to enter medullary canal	Pre-existing implant blocking antegrade medullary access
Pathological fractures <sup>b</sup>	Multiple trauma (ISS more than 25) <sup>d</sup>	Fractures extended into the distal femur (metaphyseal or articular)

ISS, Injury Severity Score.  
<sup>a</sup> Patient-based variables (eg, the patient is aged 18 years and older).  
<sup>b</sup> Ambulation even with delayed bone healing; stabilizes entire shaft.  
<sup>c</sup> The medullary diameter is too small to accept the implant.  
<sup>d</sup> Includes incompletely resuscitated or hemodynamically unstable injuries, particularly with evolving or uncompensated chest injury. May be an indication for using damage-control techniques.  
<sup>e</sup> External fixation may be preferred.<sup>37</sup>

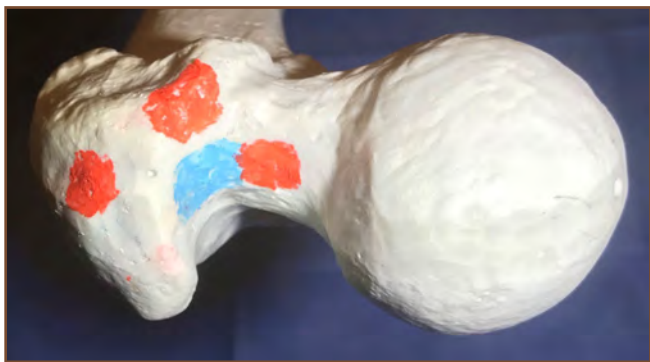applied to the thigh and a compressive wrap applied from toe to hip. The patient is placed on their unaffected side and the trunk supported with bean bag and contralateral axillary roll. The contralateral limb is extended at the hip while the fractured limb is flexed and adducted to allow independent fluoroscopic visualization of the broken femur. Traction is applied through the fracture table with counter-traction by a perineal post. Reduction is confirmed fluoroscopically.

### *Incision*

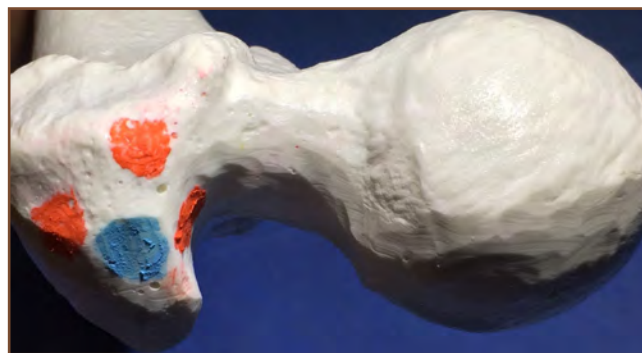
An oblique 6 cm incision is made in line with the greater trochanter starting 6 cm proximal to the trochanteric tip. The fascia of the abductor muscles is exposed and then divided in line with its fibers. The incision in the abductors is kept as small as needed to insert the instruments to the entry point on the proximal femur.<sup>27,28</sup>

### *Entry Site*

The tip of the greater trochanter is palpated and a guide pin is placed under fluoroscopic bi-planar control. The guide-pin is advanced 5 cm into the proximal femur in line with medullary canal and position confirmed on bi-planar fluoroscopy. Küntscher's awl technique can still be used effectively<sup>11</sup>; however, a guide pin is now standard. A cannulated entry reamer opens the proximal femur 5 cm into the medullary canal. A sleeve helps minimize muscular and skin damage. The piriformis fossa is located at the junction of the neck and greater trochanter slightly anterior to mid-coronal (Figure 1). The trochanteric entry point is at the tip of the greater trochanter (Figure 2).



**Figure 1.** Photograph of the recommended piriformis entry site (blue), with eccentric (ie, not recommended) locations in red.



**Figure 2.** Photograph of the recommended trochanteric entry site (blue), with eccentric (ie, not recommended) locations in red.

### *Fracture Reduction and Ball-Tipped Guide Passage*

The fracture is distracted and aligned with traction and external pressure. A ball-tipped guide rod is inserted into the cannulated reduction tool (“finger”), and both are inserted into the proximal fragment of the femur to the level of the fracture. The fracture reduction tool can be used as a lever to manipulate the proximal fracture fragment into a more precisely reduced position.<sup>27,28</sup>

The curve at the tip of the “finger” helps direct the ball-tipped guide across the fracture site into the medullary canal of the distal fragment under fluoroscopic control. The reduction tool is removed. The ball-tipped guide is advanced distally to the center of the distal physal scar on AP and lateral fluoroscopy. The measuring sleeve is slid down until it aligns with the entry point on the surface of the proximal femur to measure the length of the nail. The ball-tipped guide is advanced 1 cm further into the distal femur to avoid displacement during subsequent reamer removal.

### *Medullary Reaming*

Serial reaming of the femoral canal is started with an end cutting reamer (9-mm diameter). Reamer rotation speed is maximized while the reamer is slowly advanced all the way to the distal physal scar and then slowly extracted while reaming. The reaming is continuous and never in reverse. The reamer tip is exchanged and the steps repeated in 0.5-mm increments until isthmus cortical chatter is encountered, usually at about 11 mm. An obturator is used during reamer exchange to maintain the guide position. It is recommended to use a nail at least 1 mm less in diameter than the maximum diameter reamed to facilitate easy passage of the nail.<sup>29</sup>

### *Nail Insertion*

The appropriate sized nail is selected and mounted onto the driver assembly. Fracture reduction is confirmed clinically and radiographically. In supine position, rotation of the limb is adjusted by comparing it with the uninjured leg and by imaging to reveal the profile of the lesser trochanter to rotationally align the distal fragment with the proximal fragment.<sup>28,29</sup> The patella generally should point straight anteriorly. Assessment of rotation is more difficult but equally important with lateral position nailing.

The nail and driver assembly is placed over the guide wire and into the femoral entry site. The nail is advanced to the fracture site with gentle blows while monitoring the guide wire to ensure that it does not advance with the nail. The nail should advance with each blow, which is especially important as the tip of the nail passes the fracture site. Reduction is confirmed as the nail is passed across the fracture. The guide rod is removed. The nail is seated to the distal physal scar with the proximal end of the nail at the entry site. Length and rotation of the nail and the limb are maintained and confirmed during nail insertion.<sup>28</sup>

### *Locking*

Placement of locking screws in both the proximal and distal fragment is recommended in nearly all cases.<sup>7,26</sup> Some nail systems have two or more distal interlock screw options; one may be oblong or a "slot" for a dynamic locking option.<sup>30</sup> A locking screw placed through the distal aspect of the dynamic locking slot maintains rotation only. The second locking screw in the static round hole maintains length and angular alignment.<sup>30</sup> If delayed union occurs, the static locking screw can be removed. The retained dynamic locking screw allows slight shortening to facilitate healing but prevents excessive shortening and maintains stability against rotation and angulation. More recent studies indicate that dynamization with a screw preserved in the dynamic locking hole is associated with a higher union rate when compared to removing two static inter-lock screws in patients with delayed bony union. This union rate is highest when dynamization was performed between 10 and 24 weeks from the time of the index surgery according to a study by Huang et al.<sup>31</sup>

Proximal locking is performed through a nail mounted guide. The most common pattern is a single oblique screw from proximal lateral, through the nail, to the distal medial cortex at the lesser trochanter. Some nail designs have one or two transverse screws at the level of the lesser trochanter. Reconstruction nails are available which provide cephalad fixation into the femoral head and neck when required in proximal fractures.<sup>32</sup> One must confirm that the nail tip

is at the cortex of the greater trochanteric or piriformis entry point immediately prior to proximal locking screw placement.<sup>31</sup> An incision is made where the drill sleeve meets the skin. The drill sleeve is seated down to bone. Using the specific drill bit, a hole is drilled through the lateral and medial cortex. The depth gauge is utilized to determine the length of the screw.

A variety of techniques are available for distal locking. Nail mounted guides have not generally been successful.<sup>7</sup> We, like most surgeons, use a freehand technique with fluoroscopic guidance. Alternative techniques for distal locking have also been reported. A radiolucent drill is particularly useful when learning the technique of distal locking. A hand held electromagnetic targeting system has been introduced, which may facilitate the insertion.<sup>33</sup> This system has been shown to reduce radiation exposure and operating time and is equivalent in accuracy when compared to the free hand technique according to two recent studies by Chan et al.<sup>34</sup>

Correct length and rotation of the femur is confirmed immediately prior to distal locking. Using lateral fluoroscopy, a perfect circle of the distal locking hole in the nail is obtained and the overlying skin is marked. A 2-cm longitudinal incision is made and the lateral fascia is divided in the mid coronal plane in line with its fibers.<sup>33</sup> The periosteum of the lateral cortex of the femur is elevated with a Freer elevator. The tip of the drill bit is centered over the hole on fluoroscopy with the drill handle anterior to the thigh. The drill is rotated parallel to the beam and perpendicular to the nail and a hole is drilled through the lateral cortex to the endosteum of the medial cortex. Length is measured from the scored bit and 5 mm is added. The medial cortex is drilled and the screw is then placed. A second screw can be placed in similar fashion.

### *Wound Closure*

The wounds are irrigated to remove remainings.<sup>22</sup> The fascia of the abductors, the subcutaneous tissue and the skin are each closed. The locking incisions skin layer is closed.

### *Postoperative Management*

At the completion of the case the limb is assessed for length and rotation. A ligamentous examination of the knee is performed and recorded. The femoral neck should be radiographically inspected for fracture by bi-planar fluoroscopy in internal and external rotation.<sup>3</sup> Plain radiographs are obtained of the entire femur in two planes and reviewed to assess fracture reduction, implant position and the absence of intraoperative complications. Postoperative management of femoral shaft fractures

depends on the extent and severity of other injuries.<sup>34</sup>

Most isolated closed fractures can be started with weight bearing as tolerated immediately. Crutches or a walker are used for the first 6 weeks. Restricted weight bearing has been recommended in non-compliant patients, those with extensive comminution of the fracture or other significant lower extremity articular injuries.<sup>34</sup> Hip and knee range-of-motion and strengthening exercises are started after 2 days. Routine follow-up consists of a 2-week clinic visit with removal of skin sutures. Subsequent follow-up should occur every 6 weeks until full function is observed with radiographs until union, typically at 5 months. A final clinic visit occurs at 1 year after the injury. Nail removal is rarely indicated.

## Outcomes

IM nailing has resulted in restoration of both form and function and produced remarkably good short- and long-term results, with low complication rates.<sup>6</sup> The reported results of reamed nailing have been superior to those of other methods for treating closed and open type I, II, and IIIA fractures.<sup>8</sup> Almost complete return of hip and knee motion with a union rate of more than 95% can be expected.<sup>12,21</sup> Infection rates have been minimal (< 1%) for closed fractures. IM nailing of severe open fractures has higher infection rates, but so do other treatments of this injury.<sup>8</sup> Systemic complications and death rates associated with patients with femur shaft fractures have decreased in the past 25 years because nailing techniques have improved.<sup>12,35,36</sup> The early return to ambulation prevents most of the problems of prolonged recumbent status, including disuse atrophy, stiffness, weakness, deep vein thrombosis, and pneumonia.<sup>37</sup> Hospitalization is relatively short and many patients are able to return to work while the fracture heals.<sup>37,38</sup>

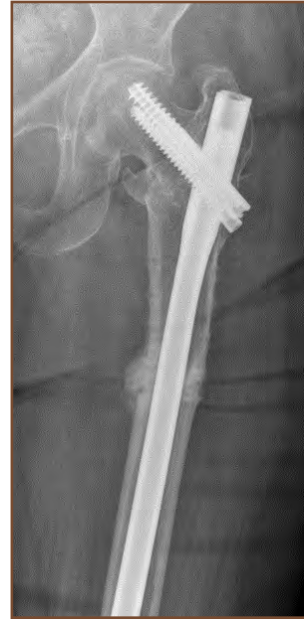## Pearls

Based on our personal experience in using antegrade approaches with IM nailing, our noted “pearls” or helpful considerations include:

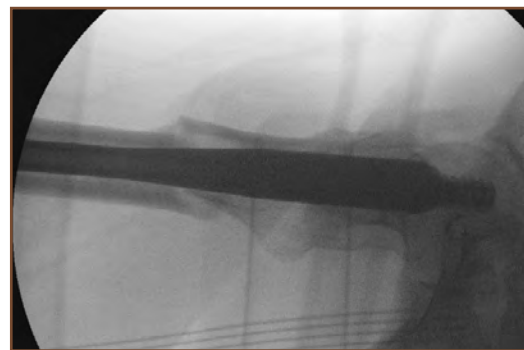
1. It is important to ream at least 1 mm more than the selected nail diameter to accommodate for the natural curvature of the femoral canal and ease of insertion. The nail should pass easily with light tapping with a mallet. If resistance is encountered, remove the nail and ream an additional 1-2 mm.<sup>37</sup>
2. Use the guide pin with bi-planar fluoroscopy to make sure the entry point is exactly correct before reaming. “Eccentric” starting point may result in fracture malreduction,<sup>4</sup> iatrogenic comminution, nail mal-

position or nail breakage (Figure 3).

3. Make sure the fracture is reasonably aligned prior to entry reaming for IM nailing of sub-trochanteric fractures. If the entry channel is created with the proximal fragment flexed and apex anterior angulation of the subtrochanteric fracture site, that same deformity will recur with nail placement (Figure 4).<sup>32</sup>



**Figure 3.** Anteroposterior radiograph of the femur, showing effect of an eccentric (too lateral) trochanteric entry site. Notably, the placement results in varus (apex lateral) mal-reduction of the femur shaft fracture.



**Figure 4.** Lateral radiograph of the femur, showing effect of an eccentric (too anterior) piriformis entry site. Notably, the placement results in extension (apex anterior) malreduction of the subtrochanteric femur shaft fracture.

4. Withdraw the guide wire after the nail has entered the distal fragment. Otherwise the guide wire may be driven through the distal femur or become stuck as the nail is seated.
5. If the distal locking screw lateral entry site is anterior to the coronal midline, the nail or fracture is likely internally mal-rotated and should be corrected before proceeding.

6. If the fracture is distracted after nail insertion then seat the nail to the physal scar distally and perform distal locking. Release traction and backslap the nail to impact the fracture and then perform proximal locking.
7. For proximal and mid-shaft fractures, only one distal locking screw is required. In more distal fractures, two screws should be used to prevent angulatory deformity.
8. Note the specific implants used in the operating note, particularly if any special instruments are needed. This will facilitate removal or revision.
9. Aggressive intravenous or intramuscular management of pain is appropriate for the first 48 hours postoperatively. Orally, analgesia is appropriate for 14 days postoperatively. Avoid chronic narcotic problems after 2 weeks postoperatively.

### Pitfalls

Based on personal experiences and results of published studies, our noted “pitfalls” (ie, complications associated with antegrade locked rigid IM nailing) involve associated injuries, wrong measurements of length, and difficulties with reaming, nail insertion, locking, and rehabilitation.

#### *Associated Injuries*

1. Late diagnosis of associated femoral neck fracture. There is a 5% incidence of associated femoral neck fracture, and many of these are not diagnosed initially.<sup>12</sup>
2. Iatrogenic femoral neck fracture.
3. Late diagnosis of other injuries (eg, tear of the knee ligament).

#### *Wrong Measurement of Length*

1. Unfamiliarity with the measuring device of the system used.
2. Distraction or shortening at the fracture site during length measurement, resulting in nail of the wrong length (too short or too long).
3. Not maintaining or confirming the distal location of the ball-tipped guide during length measurement.
4. Not ensuring that the measuring device is at the entry cortex (the measuring device can get caught in the soft tissue or advanced inside the entry canal).
5. Choosing the next longer nail when optimal length is between available sizes, resulting in prominent nail. Shorter nail is generally preferred.

### *Reaming*

1. Never use a reamer in the reverse mode as it may unwind and break.
2. Failure to use a ball-tipped guide, which is required to extract a stuck reamer.
3. Advancing the reamer too rapidly. The reamer may become stuck or spiral down the femur resulting in a “rifling” effect that leads to rotation of the nail or failure to advance the nail during insertion.
4. Using shallow fluted or dull reamers, which increase heat and pressure and pushes medullary contents into the circulation and causes pulmonary dysfunction.
5. Failure to maintain reasonable reduction during reaming, which results in increased risk of comminution at the fracture site. Eccentric reaming also leads to malreduction.
6. Failure to use an obturator (or other method) to maintain position of the guide during reamer extraction, which may result in loss of intramedullary position of the ball-tipped guide. This can lead to extramedullary reaming (very undesirable) or considerable time loss in replacement of the ball-tipped guide (undesirable).
7. Holding the ball-tipped guide with the gloved hand during reamer extraction. The ball-tipped guide can spin, wrapping up the glove and contaminating both the reamer and the ball-tipped guide, adding an hour to operating time while new sterile instruments are obtained. A Kocher clamp should be used.
8. Failure to adequately ream distally, which can cause distraction of the fracture site during nail insertion.
9. Extensive reaming in severely traumatized patients, which may cause pulmonary decompensation. Damage control techniques may be preferable.

### *Nail Insertion*

1. Incorrectly mounting the nail relative to anterior and lateral bow. The surgeon (not a scrub technician) should confirm alignment before insertion. Trochanteric nail systems have right and left designs.<sup>39</sup>
2. Failure to correctly identify the correct orientation and diameter of the interlocking guides, holes, and drill bit diameter before insertion.
3. Using a nail of larger diameter than reamed.
4. Striking the drill guide assembly with the mallet. This deforms the guide which is no longer aligned to the holes in the nail. Only the insertion or extraction attachment should be struck.
5. Failure to advance the nail with each blow. The next strike may comminute the fracture or incarcerate the

nail. Impact sound will also change if the nail is not advancing.

6. Using excessive force advancing the nail, which may result in fracture comminution or nail incarceration.
7. Failure to maintain rotation of the nail during insertion will result in oblique mal-positioned locking screws and cause malreduction of the fracture through loss of anatomic anterior bow.
8. Failure to maintain reduction (especially length and rotation) during nail insertion, which results in malunion.
9. Failure to confirm seating of the nail at the time of locking, which can lead to prominence of the nail into the hip musculature.
10. Failure to confirm central position of the guide wire, reamer, and nail within a short distal fragment resulting in angulatory mal-union.
11. Mismatch radius of curvature between patient and nail. Specifically using a straight nail (large radius of curvature) in older patients with a bowed femur (small radius of curvature). As a result, the nail penetrates through the anterior cortex distally.

### Locking

1. Failure to establish a stable alignment for the limb, resulting in motion during locking screw placement and subsequent malposition of the screws.
2. Failure to remove the guide rod prior to drilling for locking screws.
3. Drilling a cortical hole near but not directly over the hole in the nail. This makes subsequent correct placement difficult and weakens the bone.
4. Placement of screws that are too long, resulting in medial irritation, or too short, resulting in angulation.
5. Failure to fully seat the screw head against the near cortex, resulting in soft-tissue irritation. This is especially common in screws with an increased diameter of thread at the neck of the screw.
6. Losing the screw from the screwdriver into the soft tissue during insertion. (See Pearl 8.)
7. Attempting to use nail-mounted guides for distal locking. These are not generally reliable because the nail deforms somewhat during insertion.
8. Failure to place both proximal and distal locking screws in rotationally or length unstable fracture patterns (most fractures).
9. Placement of locking screw in the proximal (wrong) end of the dynamic slot.
10. Failure to assess length, rotation and stability at the end of the case. This is the time when it is easiest to correct any problems.

11. Failure to assess other injuries at the end of the case (femoral neck fracture, knee ligament injury, etc). This is the best time to diagnose these injuries and determine a plan of treatment.

### Rehabilitation

1. Failure to recognize abnormal length or rotation during early ambulation when it is relatively easy to correct by revision of the nail.
2. Failure to recognize occult fractures of the femoral neck when the patient begins to ambulate.<sup>40</sup>
3. Failure to match patient physical activity to the postoperative levels of stability and healing. Too much activity too soon can result in loss of fixation, fracture, or bending of the nail. Excessive restriction of activity can result in stiffness, weakness, and delayed union.
4. Failure to recognize delayed union early when it is easiest to treat by simple dynamization.<sup>9</sup>
5. Prolonged use of narcotic analgesics, resulting in chronic dependency problems.<sup>41</sup>

### Conclusion

Antegrade locked rigid IM nailing is an effective method for treating femur shaft fractures. Piriformis and trochanteric entry sites can both be used as an approach. Knowledge of implant design, specific techniques, and treatment pearls can facilitate the procedure and help avoid problems and pitfalls.

### Funding

The authors received no financial support for the research, authorship, and publication of this article.

### Conflict of Interest

The authors report no conflicts of interest.

### References

1. Bain GI, Zacest AC, Paterson DC, Middleton J, Pohl AP. Abduction strength following intramedullary nailing of the femur. *J Orthop Trauma* 1997;11(2):93-7.
2. Bucholz RW, Jones A. Fractures of the shaft of the femur. *J Bone Joint Surg Am* 1991;73(10):1561-6.
3. Court-Brown BM. Femoral diaphyseal fractures. In: Browner BD, Jupiter JB, Levine AM, et al, eds. *Skeletal Trauma*. 3rd ed. Philadelphia, PA: WB Saunders; 2003:1879-1956.

4. Ostrum RF, Gruen GS, Zelle BA. Fractures of the femoral diaphysis. In: Baumgaermer MR, Tornetta P 3rd, eds. 3rd ed. Rosemont, IL: American Academy of Orthopaedic Surgeons; 2005:387-95.
5. Veitch RG, Hansen ST, Clawson D. Closed Küntscher nailing of femoral fractures. In: Browner B, Edwards C, eds. *The Science and Practice of Intramedullary Nailing*. Philadelphia, PA: Lea & Febiger; 1984:149-68.
6. Winquist RA, Hansen ST Jr, Clawson DK. Closed intramedullary nailing of femoral fractures: a report of five hundred and twenty cases. *J Bone Joint Surg Am* 1984;66(4):529-39.
7. Kempf I, Grosse A, Beck G. Closed locked intramedullary nailing. Its application to comminuted fractures of the femur. *J Bone Joint Surg Am* 1985;67(5):709-20.
8. Nowotarski PJ, Turen CH, Brumback RJ, Scarboro JM. Conversion of external fixation to intramedullary nailing for fractures of the shaft of the femur in multiply injured patients. *J Bone Joint Surg Am* 2000;82(6):781-8.
9. Ostrum RF, Agarwal A, Lakatos R, Poka A. Prospective comparison of retrograde and antegrade femoral intramedullary nailing. *J Orthop Trauma* 2000;14(7):496-501.
10. Tornetta P 3rd, Tiburzi D. Reamed versus nonreamed antegrade femoral nailing. *J Orthop Trauma* 2000;14(1):15-9.
11. Küntscher, G. *Practice of Intramedullary Nailing*. In: Rinne HH, trans-ed. Springfield, IL: Charles C. Thomas; 1967.
12. el Moumni M, Leenhouts PA, ten Duis HJ, Wendt KW. The incidence of non-union following unreamed intramedullary nailing of femoral shaft fractures. *Injury* 2009;40(2):205-8. doi: 10.1016/j.injury.2008.06.022.
13. Küntscher, G. *The Marrow Nailing Method*. In: US Fleet, US Naval Forces, Germany, Technical Section (Medical), trans-ed. Reprint 1947. Kalamazoo, MI: Stryker; 2006.
14. Ricci WM, Devinney S, Haidukewych G, Herscovici D, Sanders R. Trochanteric nail insertion for the treatment of femoral shaft fractures. *J Orthop Trauma* 2005;19(8):511-7.
15. Ricci WM, Schwappach J, Tucker M, et al. Trochanteric versus piriformis entry portal for the treatment of femoral shaft fractures. *J Orthop Trauma* 2006;20(10):663-7.
16. Tupis TM, Altman GT, Altman DT, Cook HA, Miller MC. Femoral bone strains during antegrade nailing: a comparison of two entry points with identical nails using finite element analysis. *Clin Biomech (Bristol, Avon)* 2012;27(4):354-9. doi: 10.1016/j.clinbiomech.2011.11.002.
17. Ricci WM, Devinney S, Haidukewych G, Herscovici D, Sanders R. Trochanteric nail insertion for the treatment of femoral shaft fractures. *J Orthop Trauma* 2005;19(8):511-7.
18. Dougherty PJ, Gherebeh P, Zekaj M, Sethi S, Oliphant B, Vaidya R. Retrograde versus antegrade intramedullary nailing of gunshot diaphyseal femur fractures. *Clin Orthop Relat Res* 2013;471(12):3974-80. doi: 10.1007/s11999-013-3058-8.
19. Starr AJ, Hay MT, Reinert CM, Borer DS, Christensen KC. Cephalomedullary nails in the treatment of high-energy proximal femur fractures in young patients: a prospective, randomized comparison of trochanteric versus piriformis fossa entry portal. *J Orthop Trauma* 2006;20(4):240-6.
20. Letts M, Jarvis J, Lawton L, Davidson D. Complications of rigid intramedullary rodding of femoral shaft fractures in children. *J Trauma* 2002;52(3):504-16.
21. Wu CC, Yu CT, Hsieh CP, Chen SJ, Chang IL. Femoral head avascular necrosis after interlocking nail of a femoral shaft fracture in a male adult: a case report. *Arch Orthop Trauma Surg* 2008;128(4):399-402.
22. Tornetta P 3rd, Tiburzi D. Reamed versus nonreamed antegrade femoral nailing. *J Orthop Trauma* 2000;14(1):15-9.
23. Apostle KL, Lefavre KA, Guy P, et al. The effects of intraoperative positioning on patients undergoing early definitive care for femoral shaft fractures. *J Orthop Trauma* 2009;23(9):615-21. doi: 10.1097/BOT.0b013e3181a6a941.
24. Pape HC, Hildebrand F, Pertschy S, et al. Changes in the management of femoral shaft fractures in polytrauma patients: from early total care to damage control orthopedic surgery. *J Trauma* 2002;53(3):452-61; discussion 461-2.
25. Firat A, Tecimel O, Devenci A, Ocguder A, Bozkurt M. Surgical technique: supine patient position with the contralateral leg elevated for femoral intramedullary nailing. *Clin Orthop Relat Res* 2013;471(2):640-8. doi: 10.1007/s11999-012-2722-8.
26. DeCoster TA, Miller RA. Closed locked intramedullary nailing of femoral shaft fractures in the elderly. *Iowa Orthop J* 2003;23:43-5.
27. DeCoster TA, Swenson DR. Femur shaft fractures. In: Bulstrode C, Buckwalter J, Carr A, et al, eds. *Oxford Textbook of Orthopedics and Trauma*. London, UK: Oxford University Press; 2002.
28. DeCoster TA, Xing Z. Femur shaft fractures. In: Bulstrode C, Wilson-MacDonald J, Eastwood D, et al, eds. *Oxford Textbook of Trauma and Orthopaedics*. 2nd ed. New York, New York: Oxford University Press; 2011:1328-37.
29. Rudloff MI, Smith WR. Intramedullary nailing of the femur: current concepts concerning reaming. *J Orthop Trauma* 2009;23(suppl 5):S12-S7. doi: 10.1097/BOT.0b013e31819f258a.
30. Beltran MJ, Mitchell PM, Collinge CA. Posterior to anteriorly directed screws for management of talar neck fractures. *Foot Ankle Int* 2016;37(10):1130-6.



31. Huang KC, Tong KM, Lin YM, Loh el-W, Hsu CE. Evaluation of methods and timing in nail dynamisation for treating delayed healing femoral shaft fractures. *Injury* 2012;43(10):1747-52. doi: 10.1016/j.injury.2012.06.024.
32. Wiss DA, Matta JM, Sima W, Reber L. Subtrochanteric fractures of the femur. *Orthopedics* 1985;8(6):793,797-800.
33. Maqungo S, Horn A, Bernstein B, Keel M, Roche S. Distal interlocking screw placement in the femur: free-hand versus electromagnetic assisted technique (suershot). *J Orthop Trauma* 2014;28(12):e281-e283. doi: 10.1097/BOT.0000000000000125.
34. Chan DS, Burris RB, Erdogan M, Sagi HC. The insertion of intramedullary nail locking screws without fluoroscopy: a faster and safer technique. *J Orthop Trauma* 2013;27(7):363-6. doi: 10.1097/BOT.0b013e3182828e10.
35. Shih KS, Hsu CC, Hsu TP, Hou SM, Liaw CK. Biomechanical analyses of static and dynamic fixation techniques of retrograde interlocking femoral nailing using nonlinear finite element methods. *Comput Methods Programs Biomed* 2014;113(2):456-64. doi: 10.1016/j.cmpb.2013.11.002.
36. Starr AJ, Hay MT, Reinert CM, Borer DS, Christensen KC. Cephalomedullary nails in the treatment of high-energy proximal femur fractures in young patients: a prospective, randomized comparison of trochanteric versus piriformis fossa entry portal. *J Orthop Trauma* 2006;20(4):240-6.
37. Bosse MJ, MacKenzie EJ, Riemer BL, et al. Adult respiratory distress syndrome, pneumonia, and mortality following thoracic injury and a femoral fracture treated either with intramedullary nailing with reaming or with a plate: a comparative study. *J Bone Joint Surg Am* 1997;79(6):799-809.
38. MacKenzie EJ, Burgess AR, McAndrew MP, et al. Patient-oriented functional outcome after unilateral lower extremity fracture. *J Orthop Trauma* 1993;7(5):393-401.
39. Jaicks RR, Cohn SM, Moller BA. Early fracture fixation may be deleterious after head injury. *J Trauma* 1997;42(1):1-5; discussion 5-6.
40. Wu CC, Shih CH. Ipsilateral femoral neck and shaft fractures. Retrospective study of 33 cases. *Acta Orthop Scand*. 1991;64:346-351.
41. Morris BJ, Mir HR. The opioid epidemic: impact on orthopaedic surgery. *J Am Acad Orthop Surg*. 2015 May;23(5):267-71.

# Radiographic and Clinical Evaluation of Syndesmotic Screws in Treating Injuries of the Distal Aspect of the Tibiofibular Syndesmosis

James A. Dollahite, MD; Paul J. Goodwyn, MD; Katherine J. Gavin, MD;  
Richard A. Miller, MD

Department of Orthopaedics & Rehabilitation, The University of New Mexico Health Sciences Center,  
Albuquerque, New Mexico

## Abstract

*Background:* Several factors can affect the success of surgical treatment of injuries to the distal aspect of the tibiofibular syndesmosis, including the bony articulation between the distal aspect of the fibula, tibia, and the supporting ligamentous structures; number and size of screws; number of cortices penetrated; and planned routine removal of screws.

*Methods:* We conducted a retrospective review of radiographs and clinic notes for all patients who underwent open reduction and internal fixation of injury to the tibiofibular syndesmosis, which was performed by a single surgeon (RAM), between January 2011 and December 2014. Only screws were used. The screws were removed postoperatively if pain was noted or if requested by the patients. Exclusion criteria included patients with fractures treated initially with external fixation and patients with diabetic neuropathy; ultimately, 44 patients were included in the study.

*Results:* During postoperative follow-up, eight screws broke and six screws loosened. Two broken screws and one loose screw were causing symptoms of pain and subsequently removed. One broken screw was replaced owing to loss of fixation. Four intact screws were causing pain and later removed.

*Conclusions:* There is not a clearly defined advantage to routine screw removal. Risks and costs associated with an additional operative treatment for routine removal are likely unnecessary, but removal when the hardware results in pain is recommended. Treatment outcomes were similar between cortices crossed, number of screws used, and placement of screws through plates.

## Introduction

Multiple methods exist regarding appropriate use of screws with operative treatment of syndesmosis-related injuries of the ankle. Studies have debated the benefits and risks of the size and number of screws, number of cortices through which the screws should penetrate, and whether to routinely remove the screws after treatment.<sup>1,2,3</sup>

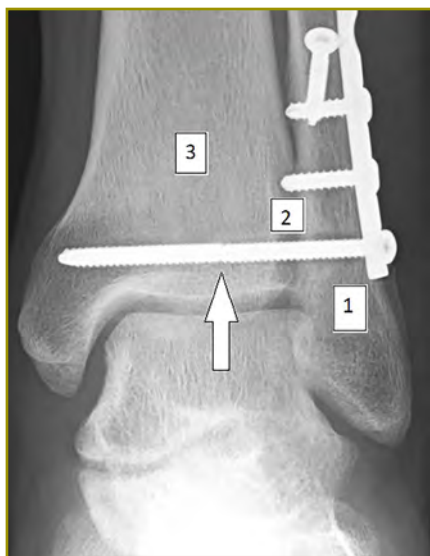Because the fibula has some motion relative to the tibia during ankle motion and gait, surgeons have argued that fixation of three cortices instead of four may result in more frequent loosening of the syndesmotic screws and subsequent restoration of distal tibial-fibular motion.<sup>4</sup> However, several recent papers have described no definitive evidence supporting improved treatment outcomes involving three cortices versus four.<sup>5,6</sup> Similarly, routine postoperative removal (ie, at several months after the treatment) of syndesmotic screws has been proposed to restore distal tibial-fibular motion and improve ankle function.<sup>7</sup> The size of screws is another debate in treating syndesmotic injuries. The use of larger screws (eg, 4.5 mm) has been noted to result in improved fixation and less chance of premature screw breakage, yet the clinical advantage has not yet been proven.<sup>8</sup> Other surgeons have noted that screws often break after postoperative healing, which suggests a possible advantage to less robust, 3.5mm screws.<sup>9</sup> Yet it is unclear whether restoration of syndesmotic motion is important for ankle function.

To better understand the question of optimal screw number, screw size, number of cortices of fixation, and whether to routinely remove syndesmotic screws, we reviewed patients with operatively treated syndesmosis injuries. We focused particularly on postoperative outcomes of the syndesmotic screws. During this period, it was the senior author's practice to not routinely remove syndesmotic screws unless desired by the patient. Removal was also offered for persistent pain or ankle stiffness.

## Methods

We received approval from our Human Research Review Committee (HRRC #16-391). We reviewed radiographs and orthopaedic clinic notes of patients who underwent open reduction and internal fixation (ORIF) for treating syndesmosis injuries between January 2011 and December 2014. During this period, the senior author performed ORIF for treating 197 malleolar ankle fractures. Exclusion criteria were fractures treated initially with external fixation and patients with diabetes and symptoms of neuropathy; ultimately, 44 patients (22%) underwent reduction and fixation of the syndesmosis and were included in the study.

We noted the associated fractures operatively repaired and the treatment method. Follow-up radiographs were evaluated for status of the syndesmosis fixation. We also documented whether the screws had been removed, broken, or loosened with loss of alignment. Figure 1 shows the location of broken screws; zones 1, 2, and 3 represent screws that broke within the fibula, syndesmosis, and tibia, respectively.



**Figure 1.** Anteroposterior view of the ankle, showing the zones of broken screws. A screw broken in zone 3 is marked (arrow).

### *Surgical Technique*

After reduction and fixation of the malleolar fracture, the syndesmosis was stressed to determine instability. While fluoroscopically viewing the ankle, we evaluated internal and external stress levels and performed a Cotton test. During a Cotton test, a distraction force is applied on the fibula, with a bone hook, to attempt to separate it from the tibia. An opposing force is applied to the tibia to try to prevent tibial motion. If widening of the syndesmosis or medial clear space occurred, then reduction and fixation of

the syndesmosis were undertaken. The syndesmosis was often reduced and temporarily held with a large ball-tipped, two-point reduction clamp under fluoroscopic guidance.

Fixation with screws was performed after drilling and measuring with a depth gauge. Fixation of 4 cortices was desired; however, the medial malleolar fixation occasionally prevented four cortical fixation. In these cases, three cortices were fixed. Three cortical fixation was also used when the screw system only had screw lengths in increments of 5 mm and when use of the longer screws would have resulted in excessive prominence of the thread portion medially. Screws were placed across the syndesmosis at a level that best fit the location of an empty screw hole when plate fixation of the fibula had been performed. Screws were placed centrally through the syndesmosis when there was no plate on the fibula. Most commonly, one screw was placed. Two screws were used in presence of an unfixed high fibula fracture.

Postoperatively, patients were placed in a splint that would be exchanged for a cast after 1 or 2 weeks. Patients were kept non-weight-bearing for 6 weeks; after which, patients used a walking boot and were allowed weight bearing and motion. At 12 weeks, patients gradually stopped using the cast boot. Indications for removal of syndesmotomic screws were discussed, but routine removal was not performed. All patients were given subsequent follow-up appointments to evaluate their status of recovery.

## Results

In addition to a syndesmosis injury, the anatomical regions of associated fractures were as follows: lateral malleolus (28 patients); medial malleolus (1 patient); medial and lateral (7 patients); medial, lateral, and posterior (1 patient); and Maisonneuve (5 patients); The remaining patients (2) had a syndesmosis injury without fracture. Most patients (28) had concomitant treatment of a lateral malleolus fracture. Table 1 describes the various methods used (labeled A through H) in treating syndesmosis injuries. Data included the number and size of syndesmotomic screws, the number of cortices fixed by the screws, and whether the screw went through a plate.

Twenty-three of 44 patients had one 3.5-mm screw placed through a plate capturing four cortices (ie, method A; Table 2). Eight patients had broken screws postoperatively, and screws in two of the eight were removed owing to symptoms of pain. Another one of the eight patients with broken screws underwent operative treatment to reduce and replace the syndesmotomic screws owing to notable loss of alignment with medial clear space widening. Six patients had loose screws, and one of the six had the screw removed because of pain. Four screws

were removed for pain without breaking or loosening. In total, seven of the 44 patients (16%) underwent removal of the syndesmotom screws, and one patient underwent replacement of the syndesmotom screw owing to loss of alignment.

**Table 1.** Description of methods used in treating 44 patients with syndesmosis injuries

Method label	No. of screws	Width of screws (mm)	Placed through a plate?	No. cortices penetrated by each screw
A	1	3.5	Yes	Four
B	1	3.5	Yes	Three
C	1	3.5	No	Four
D	2	3.5	Yes	Four
E	2	3.5	Yes	Three and four
F	2	4.5	No	Four
G	2	4.5 and 3.5	No	Three and four
H	2	4.5	No	Four

Six patients had less than 3 months of follow up and are not included in Tables 3 and 4. Screws broke in a total of eight patients (Table 3). Five had been fixed by method A and one each by method B, C, and D. Two of the eight patients had broken screws removed owing to pain, and one had the screw replaced after loss of alignment. One screw broke in zone 1, three screws broke in zone 2, and two screws broke in zone 3. One patient had one screw break in both zones 1 and 3. One patient had two screws break, each in different zones.

A loose screw was noted in one patient with developed syndesmotom widening (Figures 2 and 3). Six patients had loose screws with similar syndesmotom widening (Table 4). Four of these patients were treated using method A. Despite the loosening seen in radiographs, the self-reported pain level of patients at final follow-up was low.

Table 5 compares results of using one versus two screws; two 3.5-mm screws versus two 4.5-mm screws; and one 3.5-mm screw through four cortices versus three cortices at greater than 3-month follow-up. Fifteen of the 29 patients (52%) with one screw were reported with broken, loose, or removed screws, whereas three of the nine patients (33%) with two screws had similar outcomes. Thirteen of the 24 patients (54%) who had screws that penetrated four cortices were noted with broken, loose, or removed screws (versus two of the five patients [40%] with three cortices).

**Table 2.** Treatment of syndesmosis injuries in 44 patients, with corresponding numbers of patient treated per method, postoperative follow-up times, and patients with broken screws, loose screws, and removed screws<sup>a</sup>

Treatment method <sup>b</sup>	No. Patients	Follow-up, month <sup>c</sup>				Patients with broken screws <sup>d</sup>	Patients with loose screws <sup>e</sup>	Patients with removed screws <sup>f</sup>
		<3	3-6	6-9	>9			
A	23	4	9	3	7	5	4	3
B	5	0	2	2	1	1	1	0
C	5	0	4	1	0	1	0	0
D	4	0	2	1	1	1	0	0
E	3	2	1	0	0	0	0	0
F	2	0	0	1	1	0	0	0
G	1	0	0	0	1	0	0	1
H	1	0	0	1	0	0	1	0
<b>Totals</b>	<b>44</b>	<b>6</b>	<b>18</b>	<b>9</b>	<b>11</b>	<b>8</b>	<b>6</b>	<b>4</b>

<sup>a</sup> Eight procedures were performed to remove (seven) or replace (one) syndesmotom screws.

<sup>b</sup> Descriptions of each method are defined in Table 1.

<sup>c</sup> Values in columns represent the number of patients within each follow-up group (ie, in Method A, four patients had < 3 months of follow-up).

<sup>d</sup> Of the eight patients with broken screws, two underwent removal of screws.

<sup>e</sup> Loose screws were not broken. One patient underwent screw removal.

<sup>f</sup> Removed screws were not loose or broken. One patient underwent screw replacement.

**Table 3.** Analysis of broken screws in eight patients

Treatment method <sup>a</sup>	Zone of screw breakage	Associated fracture	Postoperative month noted	Outcome of screw	Final follow-up, month
A	3	LM	4	Removed (pain)	9
A	1 and 3	LM	5	Not removed	5
A	1	LM	5	Not removed	5
A	2	LM	4	Removed (pain)	9
A	3	LM	3	Replaced	13
B	2	LM	2	Not removed	4
C	2	Medial and LM	7	Not removed	7
D	2 and 3	Isolated syndesmosis injury	4, 5	Not removed	17

LM, lateral malleolus.

<sup>a</sup> Descriptions of each method are defined in Table 1.

**Table 4.** Analysis of loose syndesmotic screws in six patients

Treatment method <sup>a</sup>	Postoperative month <sup>b</sup>	Final follow-up, month	Self-reported pain level at final follow-up <sup>c</sup>
A	2	3	0
A	2	4	0
A	18 (not 3)	18	0
A	12 (not 6)	14	0 <sup>d</sup>
B	4	5	1
H	3	6	0

<sup>a</sup> Descriptions of each method are defined in Table 1.

<sup>b</sup> The syndesmotic screw was viewed on a radiograph obtained at this month.

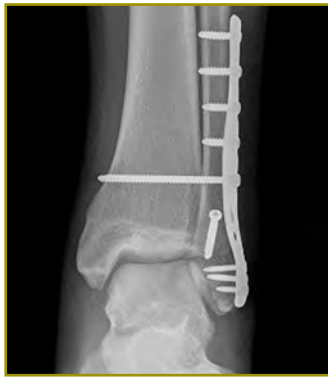<sup>c</sup> The scale defined 0 as the lowest level of pain and 10 as the highest.

<sup>d</sup> The screw was removed in this patient.

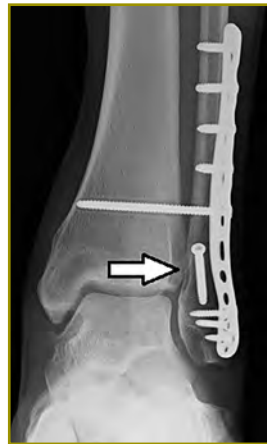**Table 5.** Results of using one versus two screws; two 3.5-mm screws versus two 4.5-mm screws; and one 3.5-mm screw through four cortices versus three cortices<sup>a</sup>

Variable (No. patients)	Broken screws	Loose screws	Removed screws
One screw (29)	7	5	3
Two screw (9)	1	1	1
Two 3.5-mm screws (5)	1	0	0
Two 4.5-mm screws (3)	0	0	1
Four cortices (24)	6	4	3
Three cortices (5)	1	1	0

<sup>a</sup> Data was obtained at > 3 month follow-up.



**Figure 2.** Postoperative radiograph, showing the syndesmosis fixed with one 3.5-mm screw through the fibula plate capturing four cortices.



**Figure 3.** Same patient as in Figure 2 but at 10 months postoperatively, with loosening of the syndesmosis screw and slight widening of the syndesmosis (arrow). Note the lucency surrounding the screw, which no longer penetrates four cortices.

## Discussion

Studies continue to debate the most successful method in treating injuries to the distal tibiofibular syndesmosis. This multifaceted debate has centered on issues such as whether syndesmosis screws should be routinely removed, how the foot should be positioned during screw placement, and the proper trajectory of screws.<sup>10</sup> There is no consensus on seemingly simple matters such as the number of screws, number of cortices to be engaged, or the diameter of screws to use.<sup>11</sup>

Once surgical fixation is achieved, the surgeon can plan for scheduled removal of syndesmosis screws or choose to forego removal unless the hardware results in symptoms of pain.<sup>12</sup> Advocates for routine removal have argued that it facilitates physiologic motion at the syndesmosis.<sup>13,14</sup> Furthermore, Manjoo et al<sup>15</sup> noted slightly worse functional outcomes in patients with intact screws compared to patients with broken, loosened, or removed screws. Yet Kaftandzief et al<sup>16</sup> reported no statistically significant differences in clinical outcome between patients with

removed or retained syndesmosis screws. The findings of our study suggest that a small proportion of screws break or loosen, and not all of these caused pain or required removal. Unbroken screws that resulted in pain were also rare.

We did note one patient who lost acceptable alignment of the syndesmosis after the screws broke, and six patients with loose screws had syndesmosis widening. These findings are congruent with two papers describing how screw removal resulted in subsequent syndesmosis widening.<sup>17,18</sup> However, a more recent report by Gennis et al<sup>3</sup> found that the mortise remained radiographically intact without syndesmosis widening after weight bearing, regardless of whether syndesmosis screws were removed, loosened, or broken, or remained intact and in place. Our data, consistent with recent trends of loosening or breakage, do not support a clearly defined advantage to routine screw removal. We assert the risks and costs associated with an additional procedure for routine removal are likely unnecessary, but we do advocate for removal when the screws result in symptoms of pain. Also, our treatment method was modestly heterogeneous. The data intimated clinical outcomes were similar regarding factors such as cortices crossed, number of screws used, or whether a screw was placed through a plate,

This study had limitations. This was a retrospective, nonrandomized case series of a single surgeon. Although 44 patients were included in the study, a larger sample size would enable more confidence regarding a representative sample of the population served. There was no precisely defined protocol during the study period. We are, however, confident that the process of shared decision making between the senior author and patient falls within the scope of standard of care. Additionally, there was a relatively short follow-up period and lack of statistical significance between techniques owing to the small number of patients that underwent some of the fixation methods. Subsequently, no definitive conclusion can be made regarding what is the best technique and ultimate outcome of syndesmosis screws

However, the results of the current study provide some informative data regarding our experience with syndesmosis fixation. In general, patients seemed to have promising short-term clinical outcomes even in the presence of broken or loose screws. The number of our patients who developed broken or loose screws or who had screw removal owing to pain was previously unknown to us. Most of the broken and loose screws did not require removal. When results of studies fail to provide decisive treatment recommendations, expert opinion—rooted in the surgical experience reported here—can greatly assist practicing orthopedists.

## Funding

The authors received no financial support for the research, authorship, and publication of this article.

## Conflict of Interest

The authors report no conflicts of interest.

## References

1. Solan MC, Davies MS, Sakellariou A. Syndesmosis stabilisation: screws versus flexible fixation. *Foot Ankle Clin* 2017;22(1):35-63. doi: 10.1016/j.fcl.2016.09.004.
2. Walley KC, Hofmann KJ, Velasco BT, Kwon JY. Removal of hardware after syndesmotom screw fixation. *Foot Ankle Spec* 2016;1938640016685153. doi: 10.1177/1938640016685153.
3. Gennis E, Koenig S, Rodericks D, Otlans P, Tornetta P 3rd. The fate of the fixed syndesmosis over time. *Foot Ankle Int.* 2015;36(10):1202-8. doi: 10.1177/1071100715588186.
4. Moore JA Jr, Shank JR, Morgan SJ, Smith WR. Syndesmosis fixation: a comparison of three and four cortices of screw fixation without hardware removal. *Foot Ankle Int* 2006;27(8):567-72.
5. Magan A, Golano P, Maffulli N, Khanduja V. Evaluation and management of injuries of the tibiofibular syndesmosis. *Br Med Bull* 2014;111(1):101-15. doi: 10.1093/bmb/ldu020.
6. Høiness P, Strømsøe K. Tricortical versus quadricortical syndesmosis fixation in ankle fractures: a prospective, randomized study comparing two methods of syndesmosis fixation. *J Orthop Trauma* 2004;18(6):331-7.
7. Miller AN, Paul O, Boraiah S, Parker RJ, Helfet DL, Lorich DG. Functional outcomes after syndesmotom screw fixation and removal. *J Orthop Trauma* 2010 24(1):12-6. doi: 10.1097/BOT.0b013e3181c6e199.
8. Stuart K, Panchbhavi VK. The fate of syndesmotom screws. *Foot Ankle Int* 2011;32(5):S519-25. doi: 10.3113/FAI.2011.0519.
9. Peek AC, Fitzgerald CE, Charalambides C. Syndesmosis screws: how many, what diameter, where and should they be removed? A literature review. *Injury* 2014;45(8):1262-7. doi: 10.1016/j.injury.2014.05.003.
10. Schepers T, van der Linden H, van Lieshout EM, Niesten DD, van der Elst M. Technical aspects of the syndesmotom screw and their effect on functional outcome following acute distal tibiofibular syndesmosis injury. *Injury* 2014;45(4):775-9. doi: 10.1016/j.injury.2013.09.035.
11. Van Heest TJ, Lafferty PM. Injuries to the ankle syndesmosis. *J Bone Joint Surg Am* 2014;96(7):603-13. doi: 10.2106/JBJS.M.00094.
12. Tucker A, Street J, Kealey D, McDonald S, Stevenson M. Functional outcomes following syndesmotom fixation: A comparison of screws retained in situ versus routine removal - Is it really necessary? *Injury* 2013;44(12):1880-4. doi: 10.1016/j.injury.2013.08.011.
13. Huber T, Schmoelz W, Böldlerl A. Motion of the fibula relative to the tibia and its alterations with syndesmosis screws: a cadaver study. *Foot Ankle Surg* 2012;18(3):203-9. doi: 10.1016/j.fas.2011.11.003.
14. Needleman RL, Skrade DA, Stiehl JB. Effect of the syndesmotom screw on ankle motion. *Foot Ankle* 1989;10(1):17-24.
15. Manjoo A, Sanders DW, Tieszer C, MacLeod MD. Functional and radiographic results of patients with syndesmotom screw fixation: implications for screw removal. *J Orthop Trauma* 2010;24(1):2-6. doi: 10.1097/BOT.0b013e3181a9f7a5.
16. Kaftandziev I, Spasov M, Trpeski S, Zafirova-Ivanovska B, Bakota B. Fate of the syndesmotom screw--Search for a prudent solution. *Injury* 2015;46(suppl 6):S125-S129. doi: 10.1016/j.injury.2015.10.062.
17. Jordan TH, Talarico RH, Schubert JM. The radiographic fate of the syndesmosis after trans-syndesmotom screw removal in displaced ankle fractures. *J Foot Ankle Surg* 2011;50(4):407-12. doi: 10.1053/j.jfas.2011.03.014.
18. Schepers T. To retain or remove the syndesmotom screw: a review of literature. *Arch Orthop Trauma Surg* 2011;131(7):879-83. doi: 10.1007/s00402-010-1225-x.

# Lateral Versus Dorsal Plating for Treating Metacarpal and Phalanx Fractures: A Retrospective Cohort Study

Joshua W. Hustedt, MD, MHS\*; Collin C. Barber, MD\*; Michael Bonnelly, BS†; Lloyd P. Champagne, MD\*‡

\*Department of Orthopaedics, The University of Arizona College of Medicine-Phoenix, Phoenix, Arizona

†College of Medicine, The University of Arizona College of Medicine-Phoenix, Phoenix, Arizona

‡Arizona Center for Hand Surgery, Phoenix, Arizona

## Abstract

**Background:** The purpose of this study was to investigate the differences between the dorsal and lateral plate position for metacarpal and phalanx fractures.

**Methods:** We conducted a retrospective review of prospectively collected patient data for 186 fractures treated by a single surgeon between 2009 and 2011. Rates of plate removal, total arc of postoperative motion (TAM), and patient and injury demographics were tested for association with plating position.

**Results:** Increasing age, larger plates, and dorsal plating were found in univariate analysis to be associated with decreased TAM and increased plate removal in phalanx but not in metacarpal fractures.

**Conclusions:** These data suggest that dorsal plating results in decreased TAM and increased rates of plate removal in some fractures. TAM was greater in phalanx fractures treated with lateral plating and therefore this plating technique should be considered when treating these fractures.

## Introduction

Despite the widespread use of locked plating for metacarpal and phalanx fractures, surgeons still debate the proper plate placement between the dorsal and lateral position. Early pioneers of hand surgery, including Alan Freeland, advocated for lateral plating to avoid interference with the extensor tendons.<sup>1</sup> However, early biomechanical studies of plating suggested the use of dorsal plating for hand fractures because the dorsal side of the bone experiences the highest tension forces, leading many surgeons to abandon lateral plating.<sup>2</sup> This debate has recently arisen again because modern biomechanical studies have shown equivalent biomechanical strength between lateral and

dorsal locked plating.<sup>3</sup>

Proper plate placement remains a mystery, particularly for treating fractures of the proximal phalanx. It seems intuitive that placement of plates on the side of the proximal phalanx has the inherent benefit of reducing the interaction between the plate and extensor tendon. Yet little evidence exists examining this key relationship. Current treatment options of hand fractures include plating,<sup>4,5</sup> screws alone,<sup>6</sup> intramedullary fixation,<sup>7,8</sup> Kirschner wires,<sup>9</sup> or external fixation,<sup>10</sup> all of which have range-of-motion deficits after operative procedure.<sup>11,12</sup> Therefore, it is essential to examine ways to minimize these considerable side effects.

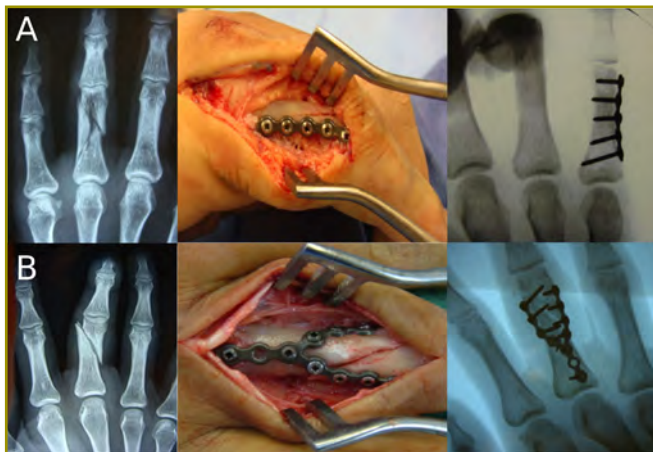This study was designed to assess the difference between dorsal and lateral plating for treating metacarpal and phalanx fractures of patients with hand trauma, treated by a single surgeon. We hypothesized that lateral plating would increase postoperative range of motion and decrease the need for plate removal owing to less irritation on the extensor tendons of the hand in both metacarpal and phalanx fractures.

## Methods

This study was approved by our institutional review board (IRB #15-031). A retrospective cohort study was conducted of patients treated by a single surgeon. Between 2009 and 2011, patients with metacarpal or phalanx fractures treated with open reduction and internal fixation, using locking plates, were identified (Figures 1A and 1B). Patients who had a minimum 1-year follow-up were included. Those with prior injuries and pathological fractures were excluded from the study. In total, 140 patients (186 fractures) were selected for inclusion in the study. All patients were treated with the use of low-profile, locked plates from the A.L.P.S Hand Fracture System (Zimmer-Biomet, Indiana, USA).



All patients were allowed to perform range of motion and weight bearing as tolerated immediately after operative treatment. At the last routine follow-up visit, the surgeon recorded the total arc of postoperative motion (TAM).



**Figure 1.** Preoperative, intraoperative, and postoperative imaging for (A) lateral and (B) dorsal plating.

The average age of the study population was 38.66 years (SD, 13.46). One hundred fifty (81%) fractures occurred in men. A total of 104 patients had isolated fractures, 30 sustained two fractures, five sustained three fractures, and one sustained five fractures. Patients had a wide variety of presenting injury types and were treated with either straight-, T-, or Y-configured plates in a dorsal or lateral position on the basis of the surgeon's discretion. One hundred eight (60%) fractures were treated with dorsal plates, and 73 (40%) with lateral plates.

Rate of plate removal and TAM were selected as the two primary outcome measures of the study. Secondary outcome measures included the need for a secondary tenolysis procedure, a postoperative infection, and postoperative complications. Patient and injury covariates included: age (< 35, 35-49, > 50); gender; mechanism of injury (low energy, high energy, or crush injury); location of injury (metacarpal or phalanx); type of plate (straight-, T-, or Y-configured plate); plate location (dorsal or lateral); soft-tissue injury (open or closed); other injuries (soft-tissue repair or tendon repair); and use of postoperative hand-therapy techniques (yes or no).

All patient and injury covariates were first tested in univariate analysis for association with rate of plate removal and TAM with the use of chi-squared test, Fisher exact test, t-tests, analysis of variance (known as ANOVA), point biserial correlation, and the Pearson correlation, as appropriate. Covariates that were significantly associated with either primary outcome variable were selected for inclusion in multivariate modeling (significance determined at  $\alpha = 0.05$ ). Secondary outcome variables

were described with descriptive statistics.

Multivariate modeling of the primary outcome variables was performed with the use of generalized linear mixed modeling. A mixed-model approach was chosen to account for clustering in the data. Some patients in the study sustained multiple fractures and therefore had multiple inclusions in the dataset. This tiered sampling structure had the potential to bias the results because patients who required one plate removal may have required multiple plate removal for various reasons (ie, infection). To account for this, mixed modeling was used to model fractures and patients as two separate clusters in a hierarchical design.

A multivariate model was run for each primary outcome variable. First, rate of plate removal was tested for association with study covariates with the use of generalized linear mixed modeling with a Poisson distribution and robust error variance. A Poisson distribution was used to directly estimate the relative risk of study variables.<sup>13,14</sup> Next, a generalized linear mixed model was used to test the association of TAM with study covariates.

## Results

### Univariate Analysis

Age, plate type, and plate position were the only variables significantly associated with an increased rate of plate removal. Patients older than 50 years required plate removal more often than patients aged 35 to 49 years or less than 35 years (25% vs 16% vs 5%;  $P = 0.002$ ). Fractures treated with larger T- or Y-type plates required removal more often than straight-type plates in phalanx fractures (28% vs 4.2%;  $P = 0.005$ ), but not in metacarpal fractures (12% vs 9.5%;  $P = 0.753$ ). Dorsal plates were found to have significantly higher rates of removal compared to lateral plates in phalanx fractures (32% vs 5%;  $P = 0.014$ ), but not in metacarpal fractures (14% vs 10%;  $P = 0.746$ ; Figure 2).

Age, plate type, and plate position were the only variables significantly associated with a decreased TAM. Patients older than 50 years had decreased TAM compared to patients aged 35 to 49 years or less than 35 years. ( $211^\circ$  vs  $221^\circ$  vs  $235^\circ$ ;  $P = 0.008$ ). Fractures treated with larger T- or Y-type plates had significantly decreased TAM as compared to straight-type plates in phalanx fractures ( $195^\circ$  vs  $222^\circ$ ;  $P = 0.023$ ), but not in metacarpal fractures ( $232^\circ$  vs  $218^\circ$ ;  $P = 0.145$ ). Likewise, dorsal plates were associated with a significant decrease in TAM compared to lateral plates in phalanx fractures ( $192^\circ$  vs  $222^\circ$ ;  $P = 0.027$ ), but not in metacarpal fractures ( $226^\circ$  vs  $231^\circ$ ;  $P = 0.811$ ; Figure 3).

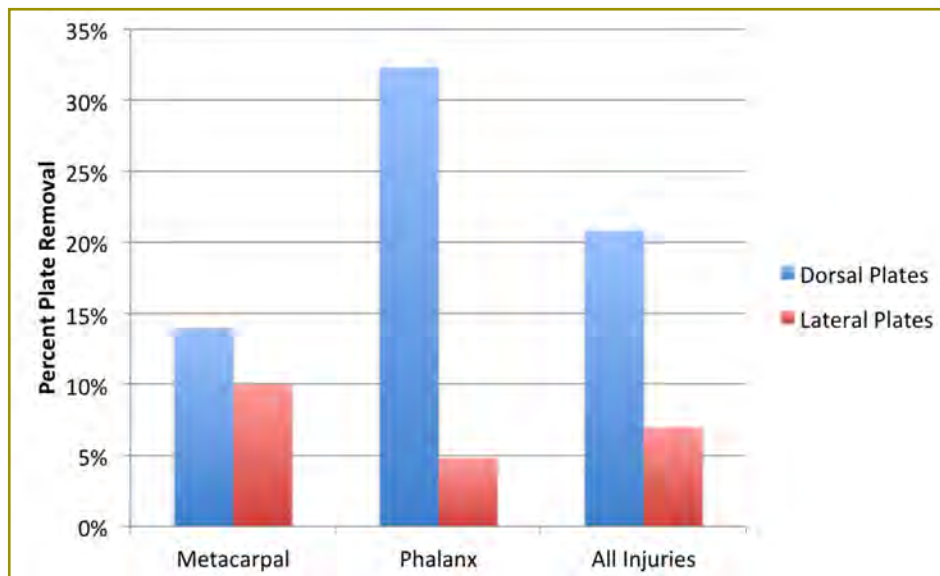


Figure 2. Rate of plate removal by fracture type and plate location.

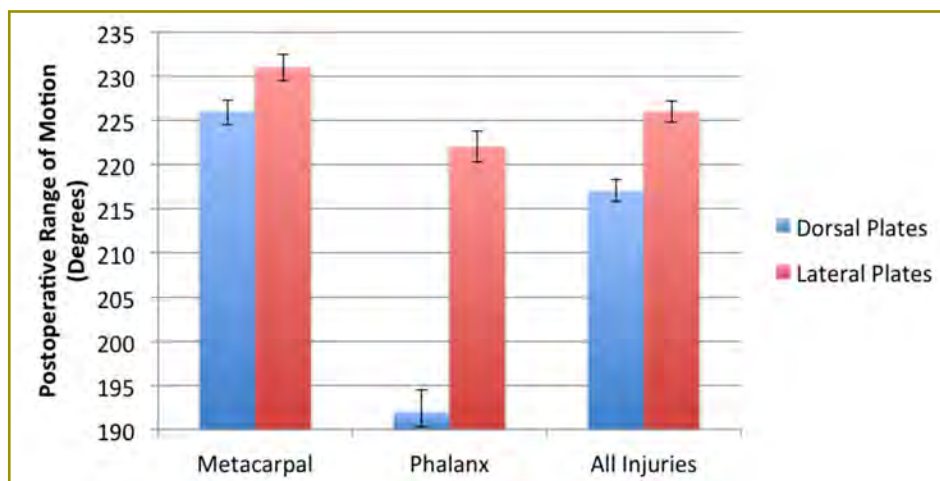


Figure 3. Postoperative total arc of motion by fracture type and plate location.

### Multivariate Analysis

The two primary outcome measures (ie, plate removal and TAM) were significantly associated with study variables in phalanx fractures only. Therefore, a multivariate analysis was performed only for phalanx fractures. In a multivariate analysis of plate removal in phalanx fractures, dorsal plating was associated with a significant increase in relative risk of plate removal as compared to lateral plating (relative risk [RR], 3.89; 95% CI: 1.01-14.92;  $P = 0.04$ ). Both increasing age (RR, 3.33; 95% CI: 0.78-14.11;  $P = 0.19$ ) and larger T-type or Y-type plates (RR, 3.81; 95% CI: 0.94-15.43;  $P = 0.06$ ) were associated with a non-significant increase in relative risk of plate removal.

In a multivariate model of TAM, lateral plating in phalanx fractures was significantly associated with an increase in TAM (increased motion of 26°;  $P = 0.04$ ). Straight plates had a non-significant increase in TAM compared to larger T- and Y-type plates (increased TAM of 19°;  $P = 0.134$ ). Patients younger than 35 years had a

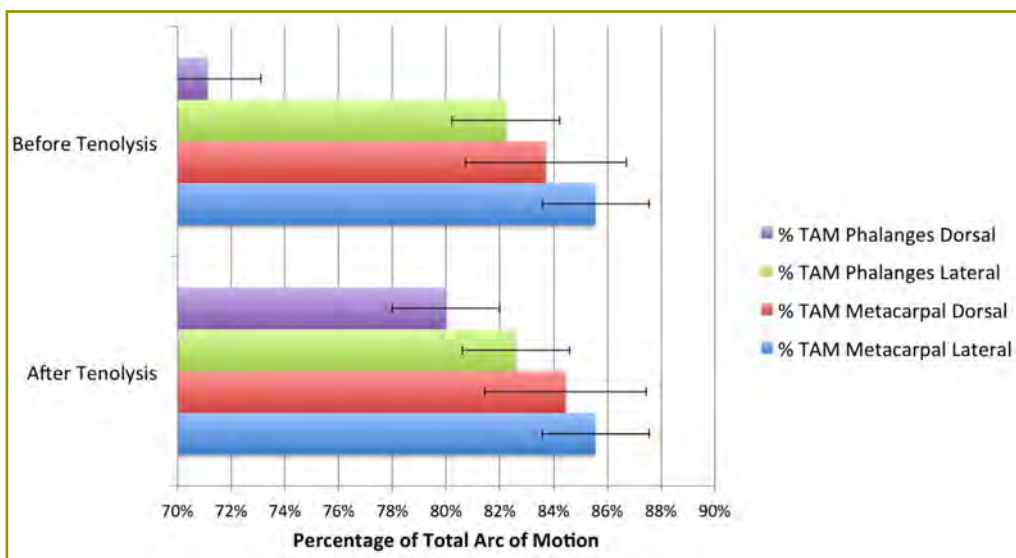
non-significant increased TAM compared to patients aged 35 to 49 years (increase TAM of 12°;  $P = 0.430$ ) and patients older than 50 years (increase TAM of 30°;  $P = 0.06$ ).

### Complications

One patient of 140 (0.7%) developed a deep surgical-site infection; one patient (0.7%) developed a nonunion, and nine patients (6.4%) returned to the operating room for treating soft-tissue defects associated with trauma. Sixteen of 140 (11%) patients returned to the operating room for an additional tenolysis procedure (Table 1). Patients treated with dorsal plating underwent tenolysis more often than those treated with lateral plates in both phalanx (81% vs 19%;  $P < 0.001$ ) and metacarpal fractures (100% versus 0%;  $P < 0.001$ ; Figure 4). After tenolysis, postoperative TAM in dorsal plating was not statistically different than TAM in lateral plating for both phalanx (216 vs 223;  $P = 0.477$ ) and metacarpal fractures (228 vs 231;  $P = 0.706$ ).

**Table 1.** Primary and secondary outcomes of study cohort by fracture location and treatment

Outcome	Metacarpal		Phalanx	
	Dorsal	Lateral	Dorsal	Lateral
Plate removal, percent	12	9.5	24	4.6
Total Arc of Motion, degrees	227	229	197	223
Secondary tenolysis	5	0	9	2



**Figure 4.** Comparison of postoperative total arc of motion (TAM) before and after tenolysis procedures.

## Discussion

This study is one of the largest case series assessing the results of lateral versus dorsal plating in treating metacarpal and phalanx fractures. A retrospective review of patient outcomes found that patients treated with lateral plating had increased range of motion and decreased need for plate removal in proximal phalanx fractures. A similar trend was seen in metacarpal fractures; however, it was not statistically significant.

Placement of plates on the side of the proximal phalanx and not under the tendon would theoretically reduce tendon adhesions. To date, only Omokawa et al<sup>15</sup> showed an association between lateral plating and improved outcomes, although the study lacked the power to examine these effects in a multivariate fashion. Data in this study provided strong evidence that lateral plating significantly reduces need for plate removal and increases postoperative range of motion in phalanx fractures. This is likely owing to the decrease in irritation and adhesions to the extensor tendons.

Despite these findings, most fractures continue to be treated using a dorsal approach, probably because early plating systems in the hand were difficult to contour and therefore sat poorly in a lateral position. In our experience,

lateral plating sometimes requires plate contouring and finesse in placement. The lateral side of the phalanx has large variations in profile that requires axial, sagittal, and coronal bends in the plate to allow the plate to lie cleanly on the bone. These difficulties are more easily overcome with new generation plating systems. These plating systems overcome the difficulty with lateral plating by providing locked fixation on plates that are easily contorted to align with the proximal phalanx.

In addition to tendon irritation and adhesion, scar formation and tissue trauma from the surgical approach also may affect postoperative motion. Although most surgeons prefer a dorsal midline approach owing to the excellent visualization of the fracture site, this approach requires considerable tissue dissection. The method may cause inadvertent tissue injury around the extensor tendon sub-sheath and further affect tendon adhesion.

In the current study, lateral plating was performed from a dorsal approach and a direct lateral approach. Compared to a dorsal approach for dorsal plating, this approach provided inferior visualization of the cortex and makes placement of the plate and drilling and insertion of the screws more difficult. In addition, lateral plating requires a pre-contoured bend to avoid “fracture gapping” and angular deformity at the far cortex. Alternatively, a

direct lateral approach offers the potential benefit of no interaction or generation of scar between the bone and extensor-tendon interface during dissection, reduction, or plate placement. This is particularly true of the distal part of the proximal phalanx, in which minimal dissection occurs between the skin incision and bone. The only sensitive structure is the dorsal branch of the digital nerve, which can be sacrificed when necessary. In the proximal portion of the proximal phalanx, the lateral bands are encountered, which requires elevation or partial excision to aid in exposure.

Despite the difficulties of lateral plating, the authors believe that the procedure offers an obvious benefit to the digit's ultimate total range of motion. Despite our findings that indicate improved use of lateral plate placement, we were unable to recommend one surgical approach over the other owing to limitations of the study design. This study was conducted as a retrospective analysis of a heterogeneous trauma population. Although data were collected on plate location, no data were collected on surgical approach, which limited the ability to specifically examine the direct effect of surgical approach on overall outcomes. Further studies may choose to examine surgical approaches, in addition to plate placement, in a prospective randomized fashion.

Our findings agree with those of other authors who have reported difficulty in need for plate removal and decreased postoperative range of motion after plating of fractures in the hand.<sup>16-19</sup> Studies have suggested that up to 20% of plates will need removal, and up to 89% of patients will experience decreased postoperative range of motion after hand plating.<sup>5,20</sup> This is often worse in the phalanges where less soft tissue surrounds the tendon-bone interface than in the metacarpals.<sup>1</sup>

The current study has limitations. Although designed to limit potential bias, this study was performed retrospectively in a heterogeneous trauma population, including a wide range of patients and injuries. We found no significant relationship between study outcomes and many patient and injury characteristics, including the severity of fractures and open or closed injuries. However, other authors have found such characteristics to be significant.<sup>1,15,21</sup> Our study may have been underpowered to determine specific effects. Additionally, we used a database of patients with traumatic injuries treated by a single surgeon. Patients with 1 year of follow-up were included because plate removal commonly occurs between 4 and 6 months after injury.<sup>20</sup> However, it is plausible that additional plate removal may occur later in some patients. In that case, these findings would be an underestimation of the actual rate of plate removal.

Overall, our results confirm that a main complication

of plating for treating metacarpal and phalanx fractures is the need for an additional operative procedure for plate removal or tenolysis. When clinically feasible, plating in the lateral position may decrease the need for future plate removal and increase postoperative range of motion, especially in phalanx fractures. Lateral plating, therefore, may prove to mitigate some of the negative side effects of fracture fixation with plates and screws and increase outcomes for patients with fractures of the hand.

## Funding

The authors received no financial support for the research, authorship, and publication of this article.

## Conflict of Interest

The authors report no conflicts of interest.

## References

1. Ouellette EA, Freeland AE. Use of the minicondylar plate in metacarpal and phalangeal fractures. *Clin Orthop Relat Res* 1996;(327):38-46.
2. Courtiss EH, reviewer. *Plast Reconstr Surg* 1979;64(4):557. Review of: Gottfried S. Konstam P, translated. *Surgical Stabilization of the Skeleton of the Hand*. Baltimore, MD: Williams & Wilkins; 1977.
3. Shanmugam R, Ernst M, Stoffel K, et al. Angular stable lateral plating is a valid alternative to conventional plate fixation in the proximal phalanx: a biomechanical study. *Clin Biomech (Bristol, Avon)* 2015;30(5):405-10. doi: 10.1016/j.clinbiomech.2015.03.019.
4. Kurzen P, Fusetti C, Bonaccio M, Nagy L. Complications after plate fixation of phalangeal fractures. *J Trauma* 2006;60(4):841-3.
5. Page SM, Stern PJ. Complications and range of motion following plate fixation of metacarpal and phalangeal fractures. *J Hand Surg Am* 1998;23(5):827-32.
6. Crawford GP. Screw fixation for certain fractures of the phalanges and metacarpals. *J Bone Joint Surg Am* 1976;58(4):487-92.
7. Orbay JL, Touhami A. The treatment of unstable metacarpal and phalangeal shaft fractures with flexible nonlocking and locking intramedullary nails. *Hand Clin* 2006;22(3):279-86.
8. Ozer K, Gillani S, Williams A, Peterson SL, Morgan S. Comparison of intramedullary nailing versus plate-screw fixation of extra-articular metacarpal fractures. *J Hand Surg Am* 2008;33(10):1724-31. doi: 10.1016/j.jhsa.2008.07.011.
9. Botte MJ, Davis JL, Rose BA, et al. Complications of smooth pin fixation of fractures and dislocations in the

- hand and wrist. *Clin Orthop Relat Res* 1992;(276):194-201.
10. Margić K. External fixation of closed metacarpal and phalangeal fractures of digits: a prospective study of one hundred consecutive patients. *J Hand Surg Br* 2006;31(1):30-40.
11. Henry MH. Fractures of the proximal phalanx and metacarpals in the hand: preferred methods of stabilization. *J Am Acad Orthop Surg* 2008;16(10):586-95.
12. Kamath JB, Harshvardhan, Naik DM, Bansal A. Current concepts in managing fractures of metacarpal and phalanges. *Indian J Plast Surg* 2011;44(2):203-11. doi: 10.4103/0970-0358.85341.
13. Bohl DD, Basques BA, Golinvaux NS, Miller CP, Baumgaertner MR, Grauer JN. Extramedullary compared with intramedullary implants for intertrochanteric hip fractures: thirty-day outcomes of 4432s procedures from the ACS NSQIP database. *J Bone Joint Surg Am* 2014;96(22):1871-7. doi: 10.2106/JBJS.N.00041.
14. Zou G. A modified poisson regression approach to prospective studies with binary data. *Am J Epidemiol* 2004;159(7):702-6.
15. Omokawa S, Fujitani R, Dohi Y, Okawa T, Yajima H. Prospective outcomes of comminuted periarticular metacarpal and phalangeal fractures treated using a titanium plate system. *J Hand Surg Am* 2008;33(6):857-63. doi: 10.1016/j.jhsa.2008.01.040.
16. Doht S, Meffert RH, Raschke MJ, Blunk T, Ochman S. Biomechanical analysis of the efficacy of locking plates during cyclic loading in metacarpal fractures. *ScientificWorldJournal* 2014;2014:648787. doi: 10.1155/2014/648787.
17. Fusetti C, Meyer H, Borisch N, Stern R, Santa DD, Papaloizos M. Complications of plate fixation in metacarpal fractures. *J Trauma* 2002;52(3):535-9.
18. Gajendran VK, Szabo RM, Myo GK, Curtiss SB. Biomechanical comparison of double-row locking plates versus single- and double-row non-locking plates in a comminuted metacarpal fracture model. *J Hand Surg Am* 2009;34(10):1851-8. doi: 10.1016/j.jhsa.2009.07.005.
19. Ruchelsman DE, Mudgal CS, Jupiter JB. The role of locking technology in the hand. *Hand Clin* 2010;26(3):307-19; v. doi: 10.1016/j.hcl.2010.04.001.
20. Syed S, Mohammed R, Hussain S, Waldram M, Power D, Tan S. Re-operation for tendon adhesions following open reduction and internal fixation of metacarpal fractures [abstract]. *Inj Extra* 2010;41(12):160. doi: 10.1016/j.injury.2010.07.482
21. Shimizu T, Omokawa S, Akahane M, et al. Predictors of the postoperative range of finger motion for comminuted periarticular metacarpal and phalangeal fractures treated with a titanium plate. *Injury* 2012;43(6):940-5. doi: 10.1016/j.injury.2012.02.011.

# Hierarchical Modeling Versus Regression Analysis for Evaluating Results of Orthopaedic Studies That Use the National Inpatient Sample

Joshua W. Hustedt\*, MD, MHS; Kade McQuivey, BS<sup>†</sup>; John C. Hustedt, MPH<sup>‡</sup>

\*Department of Orthopaedics, The University of Arizona College of Medicine-Phoenix, Phoenix, Arizona

<sup>†</sup>School of Medicine, Oakland University William Beaumont, Rochester, Michigan

<sup>‡</sup>Department of Infectious Disease Epidemiology, London School of Hygiene & Tropical Medicine, England, United Kingdom

## Abstract

**Background:** Owing to its hierarchical sampling structure, the National Inpatient Sample (NIS) often involves clusters of study data. We aimed to (1) understand the statistical methods of currently published orthopaedic studies using NIS and (2) examine the role of hierarchical modeling versus traditional regression analysis in a retrospective cohort of patients from NIS.

**Methods:** We conducted a systematic review to examine statistical methods of orthopaedic studies (published between 2005 and 2014) using NIS. Ultimately, 132 studies were identified. We noted percentages of studies that used hierarchical modeling versus traditional regression analysis. Using NIS, we identified a retrospective cohort of patients aged 70 years and older who underwent operative fixation of intertrochanteric hip fractures between 2008 and 2012. Patient comorbidities were tested for association with in-hospital mortality and length of stay in hierarchical linear models and traditional regression analysis. Statistical outcomes were compared between the two models.

**Results:** Seven of 28 (25%) measured comorbidities overestimated the significance of in-hospital mortality in traditional regression compared to hierarchical modeling. Similarly, traditional regression analysis overestimated significance in four of 28 (14%) comorbidities in increasing length of stay. Of the 132 studies, most (74%) used traditional regression analysis, few (7%) used univariate statistics, and even less (2%) used hierarchical modeling. According to these findings, between 11% to 20% of all orthopaedic studies published between 2005 and 2014 using NIS data were at risk of overestimating their clinical results.

**Conclusions:** Traditional regression analysis may overestimate significance in linear and logistic models owing to the inability to address clustered data. Because

healthcare data is often clustered, hierarchical linear modeling should be employed to increase the specificity of outcomes-based research using NIS.

## Introduction

The National Inpatient Sample (NIS) is the largest publically available all-payer inpatient healthcare database representative of all United States (US) hospitals.<sup>1</sup> The large sample size helps track epidemiological trends and in-hospital complications for inpatient orthopaedic procedures.<sup>1,2</sup> Interest in the use of NIS for orthopaedic studies has notably increased, with an exponential rise in publications in orthopaedic journals.<sup>4</sup> However, the large dataset comes with unique statistical challenges for researchers.<sup>5</sup> Clinicians should be aware of issues that may affect the conclusions drawn from studies using the database.

One of the main problems in statistical analysis using NIS arises from the large sample size. This causes even small differences to be statistically significant, yet they may not represent a clinical significance.<sup>4</sup> Many authors have suggested reducing the accepted  $\alpha$  error (ie, 0.05) to 0.01 or 0.001 to combat the discrepancy.<sup>6-24</sup> However, to date there is no standard method to address this issue.

To improve uniformity of statistical analysis in NIS, the Healthcare Cost and Utilization Project (HCUP; the creators of NIS database) have suggested the use of hierarchical linear modeling (also known as mixed modeling) instead of traditional regression analysis.<sup>5</sup> The use of hierarchical linear modeling accounts for clustering within the data. Clustering refers to grouping in the data, which may affect outcomes. In NIS, patients are inherently clustered owing to treatment by the same physician or hospital. Accounting for clustering with hierarchical linear modeling increases confidence intervals of the outcome

variables of interest and, therefore, improves specificity.<sup>26,27</sup> Many orthopedic studies do not account for this clustering and may be overestimating their findings.<sup>28</sup>

This study was designed to determine the effect of hierarchical linear modeling in orthopedic research utilizing NIS. Thus, our aims are: 1) to identify current statistical analysis trends in orthopaedic studies that use NIS; and 2) to determine the effect of hierarchical linear modeling versus traditional regression analysis in an orthopaedic-study population.

## Methods

The study was granted exempt status by our institution's investigation review owing to the de-identified quality of the data available in NIS database. To address our two objectives, a two-step study design was created. First, a systematic review of the orthopedic literature was conducted to determine the current use of statistical analysis in orthopaedic studies using NIS. Second, the effect of hierarchical linear modeling versus traditional regression analysis was tested in a retrospective cohort study using NIS.

### Systematic Review

A systematic review of orthopaedic studies was conducted to identify the current statistical analysis used by studies of NIS in the past 10 years (Figure 1). A PubMed search was undertaken for studies containing "National Inpatient Sample" or "Nationwide Inpatient Sample" (the name of the database was changed from "Nationwide" to "National" Inpatient Sample in 2012) in the top 41 orthopaedic journals as outlined by Moverley et al.<sup>29</sup> Ultimately, a total of 132 studies were identified between 2005 and 2012. The statistical analysis of each study was categorized into one of six statistical groups by two authors (JWH and

KM). Statistical categories included: traditional regression analysis, hierarchical linear modeling, univariate statistics, epidemiological population estimations, propensity scoring, and survival analysis.

### Retrospective Cohort Study

A retrospective cohort study was conducted using NIS discharge data. All patients aged 70 years and older hospitalized for surgical treatment of intertrochanteric hip fractures between 2008 and 2012 were identified (International Classification of Diseases, 9th revision [ICD-9] code 820.21 for intertrochanteric hip fracture and ICD-9 Clinical Modification procedure code 79.15 or 79.35 for open or closed reduction with internal fixation, femur). A total of 370,307 patients met inclusion criteria. NIS is a stratified survey of all US hospitals, which are randomly selected to achieve a 20% sample.<sup>1</sup> Sampling weights are provided to produce national estimates. All patient numbers in this study were reported as national estimates.

The presence or absence of 28 preoperative comorbidities in patients were identified with the use of HCUP comorbidity software.<sup>30</sup> The primary outcome measures of the cohort study were risk of in-hospital mortality and overall length of stay, which represent a dichotomous and steady outcome variable of interest to orthopaedic surgeons in identifying the effect of statistical modeling on continuous and categorical data.

### Statistical Analysis

Descriptive statistics were used to report percentages of studies using different statistical methods from the systematic review. For the retrospective cohort study, each preoperative patient comorbidity was tested for association with either primary outcome measure (ie, in-hospital mortality or overall length of stay). Two separate regression




Figure 1. Flow diagram of systematic review study design.

models were run for each outcome variable: one model with traditional regression analysis and another with hierarchical linear modeling. Level of significance for the regression models was placed at  $\alpha = 0.05$ . The significance from each model was then compared for each preoperative patient comorbidity.

Traditional regression analysis for in-hospital mortality was undertaken with logistic regression. Next, a hierarchical logistic regression model was performed. Patient clustering at the hospital level was accounted for in the hierarchical model. Odds ratios (OR) of each preoperative patient comorbidity were reported from each model.

Next, traditional regression analysis for overall length of stay was undertaken utilizing a gamma regression with a log-link function. A  $\beta$  regression, with a log-link function, was chosen to account for the positive skewness of the length of stay data. Similarly, a hierarchical linear model, with  $\beta$  regression and log-link function, was used to account for patient clustering at the hospital level. The effect of each preoperative patient comorbidity was compared between the two models.

## Results

### Systematic Review

There was an exponential rise in the number of studies published after 2011 (Figure 2). Of 132 studies identified, a total of 98 studies (74%) used traditional regression analysis<sup>3,7-15,18-23,25,31-112</sup>; a total of 11 (13%) used epidemiological population estimates<sup>2,4,113-126</sup>; a total of 10 (7%) used univariate statistics<sup>7,16,17,24,127-132</sup>; four (3%) used propensity scoring<sup>133-136</sup>; one (2%) used hierarchical linear modeling<sup>137,138</sup>; and two (1%) utilized survival analysis (Figure 3).<sup>139</sup>

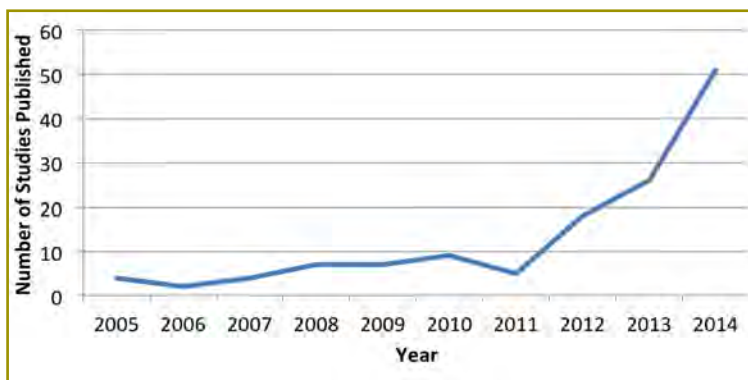


Figure 2. Number of orthopaedic studies using the National Inpatient Sample between 2005 and 2014.

### Retrospective Cohort Study

Of the 370,307 patients included, the average age was 84.4 years (range, 70-110 years). A total of 275,132 (74%) were women, and 95,122 (26%) were men. Almost all patients (356,483; 97%) had a least one comorbidity, with many patients having multiple comorbidities (Figure 4). Figure 5 represents the most common comorbidities in patients such as hypertension (72% of patients), deficiency anemias (31%), fluid and electrolyte disorders (30%), chronic obstructive pulmonary disease (21%), hypothyroidism (19%), and diabetes without complications (19%).

The average length of stay among patients was 6.04 days (SD, 4.14 days). Table 1 shows the patient comorbidities that had the largest effect on increasing length of stay in the regression models, including weight loss and malnutrition (6.13 days), congestive heart failure (3.38 days), and paralysis (3.01 days). Of the 28 variables tested in the regression models, four (14%) were significant in the traditional regression analysis but not in the hierarchical linear model.

The overall in-hospital mortality rate among the study population was 2.4%. Table 2 depicts the patient comorbidities that notably increased the odds of in-hospital mortality, which were: liver disease (OR, 2.7), weight loss and malnutrition (OR, 2.7), and congestive heart failure (OR, 2.6). Of the 28 variables tested in the regression models, seven (25%) were significant in the traditional regression analysis but not in the hierarchical linear model.

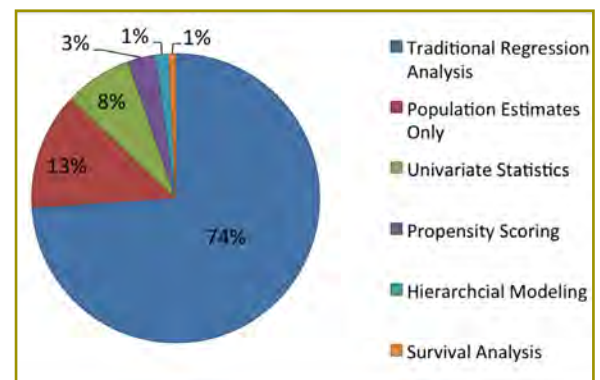


Figure 3. Statistical design of orthopaedic studies using the National Inpatient Sample between 2005 and 2014.



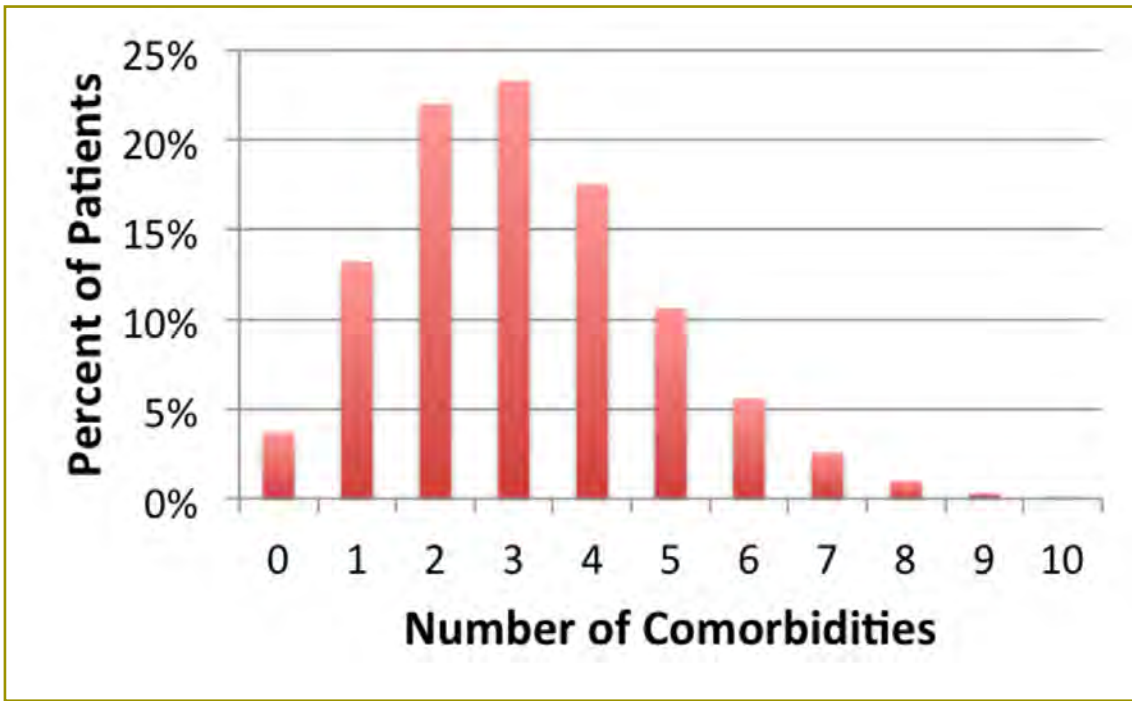


Figure 4. Percent of patients with multiple comorbidities.

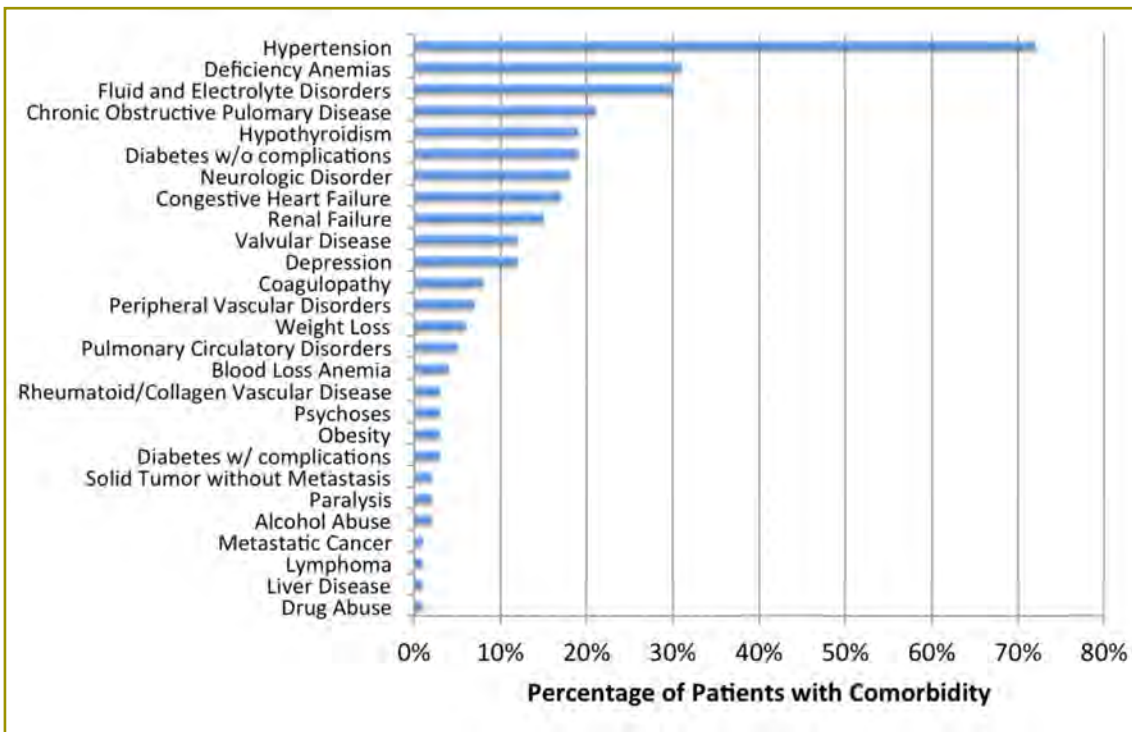


Figure 5. Percent of patients with each of the 29 measured comorbidities.

**Table 1.** Comparison of significance between traditional regression and hierarchical models measuring association between preoperative patient comorbidities and overall length of stay<sup>a</sup>

Study variable	Statistical model	Odds ratio	95% confidence interval		P value	Study variable	Statistical model	Odds ratio	95% confidence interval		P value
			Lower	Upper					Lower	Upper	
			Alcohol abuse	OLS					-0.25	0.00	
	HLM	0.46	-0.03	0.95	0.064		HLM	1.49	0.64	2.35	0.001
Blood loss anemia	OLS	0.88	0.72	1.04	< 0.001	Metastatic cancer	OLS	2.20	1.77	2.64	< 0.001
	HLM	1.14	0.77	1.51	< 0.001		HLM	2.07	1.27	2.88	< 0.001
Chronic obstructive pulmonary disease	OLS	0.55	0.47	0.63	< 0.001	Neurologic disorder	OLS	0.28	0.19	0.36	< 0.001
	HLM	0.73	0.56	0.91	< 0.001		HLM	0.40	0.22	0.58	< 0.001
Coagulopathy	OLS	1.18	1.03	1.33	< 0.001	Obesity	OLS	0.92	0.72	1.12	< 0.001
	HLM	1.33	1.03	1.63	< 0.001		HLM	1.41	0.97	1.85	< 0.001
Congestive heart failure	OLS	3.33	3.17	3.49	< 0.001	Paralysis	OLS	3.06	2.76	3.37	< 0.001
	HLM	3.38	3.03	3.73	< 0.001		HLM	3.01	2.36	3.64	< 0.001
Deficiency anemias	OLS	0.76	0.68	0.83	< 0.001	Peripheral vascular disorders	OLS	0.55	0.42	0.68	< 0.001
	HLM	0.58	0.42	0.74	< 0.001		HLM	0.71	0.43	0.98	< 0.001
Depression	OLS	-0.27	-0.36	-0.18	< 0.001	Psychoses	OLS	1.04	0.83	1.24	< 0.001
	HLM	-0.08	-0.38	0.24	0.618		HLM	1.22	0.78	1.66	< 0.001
Diabetes with complications	OLS	1.22	1.02	1.43	< 0.001	Pulmonary circulatory disorders	OLS	2.71	2.51	2.92	< 0.001
	HLM	1.45	1.01	1.89	< 0.001		HLM	2.66	2.24	3.08	< 0.001
Diabetes without complications	OLS	0.29	0.21	0.37	< 0.001	Renal failure	OLS	1.16	1.05	1.27	< 0.001
	HLM	0.13	-0.03	0.28	0.112		HLM	1.39	1.15	1.64	< 0.001
Drug abuse	OLS	2.89	1.89	3.90	< 0.001	Rheumatoid arthritis and collagen vascular disease	OLS	-0.45	-0.60	-0.29	< 0.001
	HLM	2.58	0.67	4.49	0.008		HLM	-0.08	-0.39	0.23	0.162
Fluid and electrolyte disorders	OLS	2.87	2.74	3.01	< 0.001	Solid tumor without metastasis	OLS	1.36	1.06	1.66	< 0.001
	HLM	2.88	2.56	3.19	< 0.001		HLM	1.25	0.64	1.86	< 0.001
Sex (female)	OLS	-1.24	-1.33	-1.15	< 0.001	Valvular disease	OLS	0.43	0.34	0.52	< 0.001
	HLM	-1.30	-1.49	-1.12	< 0.001		HLM	0.48	0.27	0.69	< 0.001
Hypertension	OLS	-0.73	-0.82	-0.65	< 0.001	Weight loss and nutritional deficiency	OLS	5.87	5.55	6.18	< 0.001
	HLM	-0.65	-0.84	-0.46	< 0.001		HLM	6.13	5.41	6.85	< 0.001
Hypothyroidism	OLS	-0.60	-0.67	-0.53	< 0.001						
	HLM	-0.31	-0.47	-0.16	< 0.001						
Liver disease	OLS	1.35	0.97	1.73	< 0.001						
	HLM	1.15	0.39	1.91	0.003						

OLS, traditional regression model; HLM, traditional hierarchal model.

<sup>a</sup> Comorbidities that were overestimated in traditional regression models are outlined in red.

**Table 2.** Comparison of significance between traditional regression and hierarchical models measuring association between preoperative patient comorbidities and in-hospital mortality<sup>a</sup>

Study variable	Statistical model	Odds ratio	95% confidence interval		P value	Study variable	Statistical model	Odds ratio	95% confidence interval		P value
			Lower	Upper					Lower	Upper	
Alcohol abuse	OLS	0.586	0.480	0.714	< 0.001	Lymphoma	OLS	0.818	0.621	1.078	0.156
	HLM	0.629	0.406	0.972	0.037		HLM	0.847	0.452	1.587	0.603
Blood loss anemia	OLS	0.610	0.535	0.695	< 0.001	Metastatic cancer	OLS	1.511	1.253	1.822	< 0.001
	HLM	0.588	0.430	0.803	0.001		HLM	1.579	1.045	2.385	< 0.001
Chronic obstructive pulmonary disease	OLS	1.390	1.324	1.459	< 0.001	Neurologic disorder	OLS	1.091	1.032	1.154	0.002
	HLM	1.423	1.272	1.593	< 0.001		HLM	1.112	0.974	1.270	< 0.001
Coagulopathy	OLS	1.159	1.081	1.244	< 0.001	Obesity	OLS	0.674	0.570	0.797	0.115
	HLM	1.231	1.042	1.454	< 0.001		HLM	0.730	0.499	1.068	0.105
Congestive heart failure	OLS	2.542	2.420	2.669	0.003	Paralysis	OLS	1.494	1.309	1.704	< 0.001
	HLM	2.610	2.320	2.938	< 0.001		HLM	1.503	1.086	2.079	0.014
Deficiency anemias	OLS	0.859	0.820	0.901	< 0.001	Peripheral vascular disorders	OLS	1.273	1.187	1.367	< 0.001
	HLM	0.610	0.535	0.695	0.040		HLM	1.371	1.156	1.627	< 0.001
Depression	OLS	0.785	0.730	0.845	< 0.001	Psychoses	OLS	0.931	0.819	1.057	0.272
	HLM	0.789	0.670	0.928	0.004		HLM	0.922	0.691	1.230	0.581
Diabetes with complications	OLS	0.764	0.668	0.873	< 0.001	Pulmonary circulatory disorders	OLS	2.119	1.964	2.286	< 0.001
	HLM	0.757	0.552	1.038	0.084		HLM	2.306	1.933	2.751	< 0.001
Diabetes without complications	OLS	0.913	0.861	0.968	< 0.001	Renal failure	OLS	1.638	1.551	1.729	< 0.001
	HLM	0.757	0.552	1.038	0.906		HLM	1.733	1.524	1.970	< 0.001
Drug abuse	OLS	0.271	0.668	0.873	< 0.001	Rheumatoid arthritis and collagen vascular disease	OLS	0.769	0.662	0.892	0.001
	HLM	0.282	0.038	2.084	0.215		HLM	0.748	0.532	1.052	0.095
Fluid and electrolyte disorders	OLS	1.721	1.645	1.800	< 0.001	Solid tumor without metastasis	OLS	1.348	1.184	1.537	< 0.001
	HLM	1.786	1.602	1.991	< 0.001		HLM	1.328	1.000	1.763	0.06
Sex (female)	OLS	0.566	0.540	0.593	< 0.001	Valvular disease	OLS	0.937	0.878	1.001	0.05
	HLM	0.557	0.503	0.616	< 0.001		HLM	0.986	0.843	1.154	0.861
Hypertension	OLS	0.718	0.685	0.752	< 0.001	Weight loss and nutritional deficiency	OLS	2.590	2.435	2.756	< 0.001
	HLM	0.726	0.649	0.812	< 0.001		HLM	2.744	2.352	3.200	< 0.001
Hypothyroidism	OLS	0.976	0.923	1.033	0.412						
	HLM	1.019	0.894	1.161	0.780						
Liver disease	OLS	2.643	2.256	3.098	< 0.001						
	HLM	2.794	1.935	4.032	< 0.001						

OLS, traditional regression model; HLM, traditional hierarchal model.

<sup>a</sup> Comorbidities that were overestimated in traditional regression models are outlined in red.

## Discussion

The National Inpatient Sample (NIS) is commonly used in orthopaedic surgery outcomes-based research. The use of NIS data is particularly helpful in identifying national trends and evaluating rare outcomes.<sup>2,66,88,114,122,128,139</sup>

However, the large sample size obtained from NIS provides researchers with unique difficulties in interpreting study data.<sup>5,27,34</sup> Although many orthopaedic clinicians may not be overly interested in statistics, certain limitations in database research are important to consider when conducting associated studies.

One main difficulty in interpreting large databases is determining the significance of research outcomes. For many casual readers, a *P* value of 0.05 is used to determine the “significance” of findings. However, in large database projects, this simplified interpretation may lead readers to overestimate specific study findings. The large numbers of patients in database projects cause even small differences to be statistically significant, which may not actually represent a clinical significance. In the current study, a variety in  $\alpha$  levels of significance was found among different authors who used NIS,<sup>7-25</sup> providing a “rule of thumb” to help guide clinicians in determining the significance of a study outcome for their own clinical practice.

In our own research using NIS, the HCUP (creators of NIS) recommended to use hierarchical linear modeling instead of traditional regression analysis.<sup>5</sup> However, we have rarely seen this type of analysis conducted in orthopaedic studies. This study was designed to better understand the recommendation from HCUP and the effect it would have on current studies conducted using NIS.

The result of the current study suggest that, in orthopaedic studies published between 2005 and 2014 that used NIS, only 2% used hierarchical modeling analysis. About 74% and 7% used traditional regression analysis and univariate statistics, respectively, which do not account for clustering in the dataset. Furthermore, these data suggest that traditional regression analysis overestimated study findings in 14% of comorbidities in the continuous variable of interest (length of stay) and in 25% of comorbidities in the dichotomous variable of interest (in-hospital mortality). Because most orthopaedic studies examine continual or dichotomous outcomes, between 14% to 25% of study variables may be overestimated in orthopaedic research when using traditional regression analysis. Furthermore, we found that 81% of studies used traditional regression analysis or univariate statistics (both of which do not account for clustering), suggesting that between 11% to 20% of orthopaedic studies published between 2005 and 2014 were at risk for overestimating the significance of results.

The current study has limitations that may affect the generalizability of our findings. First, we tested a specific population of orthopaedic patients. We identified this group to examine the effect of comorbidities on in-hospital mortality and length of stay in patients who underwent operative treatment of intertrochanteric hip fractures, which represents a commonly studied orthopaedic population experiencing osteoporotic fractures. However, this is a specific population, and the findings are specific to these patients. It may be that a study on different populations of patients would produce different results.

Other authors have found similar results as in the current study, showing increased specificity with hierarchical linear modeling in other non-orthopaedic populations.<sup>26,27</sup> We believe, therefore, that our findings may have general application to all orthopaedic populations included in NIS.

Second, we categorized studies in the systematic review into six statistical groups. This was done to simplify the interpretation of 10 years of study results in 132 studies. In certain situations, this categorization may oversimplify the intended statistical analysis. We recognize that many ways exist to apply statistical principles in interpreting data. However, we believe this interpretation is an honest representation of traditional regression versus hierarchical linear modeling currently used by orthopaedic studies.

The findings of the current study echo the call from HCUP for additional hierarchical linear modeling analysis in orthopaedic research using NIS. Orthopaedic clinicians should be aware that study results from NIS should be interpreted with care. An interpretation of effect sizes and clinical relevance is essential in addition to simply looking at *P* values. One way to improve specificity would be for additional studies to use hierarchical linear modeling instead of traditional regression analysis. If we do so as an orthopaedic community, we may greatly increase the specificity of results and, therefore, the clinical applicability of findings.

## Funding

The authors received no financial support for the research, authorship, and publication of this article.

## Conflict of Interest

The authors report no conflicts of interest.

## References

1. HCUP NIS Database Documentation: Healthcare Cost and Utilization Project (HCUP). Rockville, MD: Agency for Healthcare Research and Quality. [www.hcup-us.ahrq.gov/db/nation/nis/nisdbdocumentation.jsp](http://www.hcup-us.ahrq.gov/db/nation/nis/nisdbdocumentation.jsp).
2. Bozic KJ, Kurtz SM, Lau E, et al. The epidemiology of revision total knee arthroplasty in the United States. *Clin Orthop Relat Res* 2010;468(1):45-51. doi: 10.1007/s11999-009-0945-0.
3. Pugely AJ, Martin CT, Gao Y, Belatti DA, Callaghan JJ. Comorbidities in patients undergoing total knee arthroplasty: do they influence hospital costs and length of stay? *Clin Orthop Relat Res* 2014;472(12):3943-50. doi: 10.1007/s11999-014-3918-x.

4. Bohl DD, Basques BA, Golinvaux NS, Baumgaertner MR, Grauer JN. Nationwide Inpatient Sample and National Surgical Quality Improvement Program give different results in hip fracture studies. *Clin Orthop Relat Res* 2014;472(6):1672-80. doi: 10.1007/s11999-014-3559-0.
5. Houchens R, Chu B, Steiner C. Hierarchical Modeling Using HCUP Data. Rockville, MD: Agency for Healthcare Research and Quality; 2007. <http://www.hcup-us.ahrq.gov/reports/methods.jsp>. HCUP methods series report #2007-01. Published January 10, 2007. Accessed November 16, 2015.
6. Ahčan U, Arnež ZM, Bajrović F, Zorman P. Surgical technique to reduce scar discomfort after carpal tunnel surgery. *J Hand Surg* 2002;27(5):821-7.
7. Daniels AH, Arthur M, Hart RA. Variability in rates of arthrodesis procedures for patients with cervical spine injuries with and without associated spinal cord injury. *J Bone Joint Surg Am* 2007;89(2):317-23.
8. D'Apuzzo MR, Browne JA. Obstructive sleep apnea as a risk factor for postoperative complications after revision joint arthroplasty. *J Arthroplasty* 2012;27(suppl 8):95-8. doi: 10.1016/j.arth.2012.03.025.
9. D'Apuzzo MR, Pao AW, Novicoff WM, Browne JA. Age as an independent risk factor for postoperative morbidity and mortality after total joint arthroplasty in patients 90 years of age or older. *J Arthroplasty* 2014;29(3):477-80. doi: 10.1016/j.arth.2013.07.045.
10. Fineberg SJ, Ahmadinia K, Oglesby M, Patel AA, Singh K. Hospital outcomes and complications of anterior and posterior cervical fusion with bone morphogenetic protein. *Spine* 2013;38(15):1304-9. doi: 10.1097/BRS.0b013e31828f494c.
11. Fineberg SJ, Ahmadinia K, Patel AA, Oglesby M, Singh K. Incidence and mortality of cardiac events in lumbar spine surgery. *Spine* 2013;38(16):1422-9. doi: 10.1097/BRS.0b013e3182986d71.
12. Fineberg SJ, Nandyala SV, Kurd MF, et al. Incidence and risk factors for postoperative ileus following anterior, posterior, and circumferential lumbar fusion. *Spine J* 2014;14(8):1680-5. doi: 10.1016/j.spinee.2013.10.015.
13. Fineberg SJ, Oglesby M, Patel AA, Pelton MA, Singh K. Outcomes of cervical spine surgery in teaching and non-teaching hospitals. *Spine* 2013;38(13):1089-96. doi: 10.1097/BRS.0b013e31828da26d.
14. Fineberg SJ, Oglesby M, Patel AA, Singh K. Incidence and mortality of perioperative cardiac events in cervical spine surgery. *Spine* 2013;38(15):1268-74. doi: 10.1097/BRS.0b013e318290fdac.
15. Fineberg SJ, Oglesby M, Patel AA, Singh K. Incidence, risk factors, and mortality associated with aspiration in cervical spine surgery. *Spine* 2013;38(19):e1189-e1195.
16. Marquez-Lara A, Nandyala SV, Hassanzadeh H, Noureldin M, Sankaranarayanan S, Singh K. Sentinel events in cervical spine surgery. *Spine* 2014;39(9):715-20. doi: 10.1097/BRS.0000000000000228.
17. Marquez-Lara A, Nandyala SV, Hassanzadeh H, Sundberg E, Jorgensen A, Singh K. Sentinel events in lumbar spine surgery [Epub ahead of print January 29, 2014]. *Spine* 2014. doi: 10.1097/BRS.0000000000000247.
18. Ma Y, Passias P, Gaber-Baylis LK, Girardi FP, Mementsoudis SG. Comparative in-hospital morbidity and mortality after revision versus primary thoracic and lumbar spine fusion. *Spine J* 2010;10(10):881-9. doi: 10.1016/j.spinee.2010.07.391.
19. Menendez ME, Ring D. Does the timing of surgery for proximal humeral fracture affect inpatient outcomes? *J Shoulder Elb Surg* 2014;23(9):1257-62. doi: 10.1016/j.jse.2014.03.010.
20. Nandyala SV, Marquez-Lara A, Fineberg SJ, Hassanzadeh H, Singh K. Complications after lumbar spine surgery between teaching and nonteaching hospitals. *Spine* 2014;39(5):417-23. doi: 10.1097/BRS.0000000000000149.
21. Nandyala SV, Marquez-Lara A, Fineberg SJ, Singh R, Singh K. Incidence and risk factors for perioperative visual loss after spinal fusion. *Spine J* 2014;14(9):1866-72. doi: 10.1016/j.spinee.2013.10.026.
22. Oglesby M, Fineberg SJ, Patel AA, Pelton MA, Singh K. Epidemiological trends in cervical spine surgery for degenerative diseases between 2002 and 2009. *Spine* 2013;38(14):1226-32. doi: 10.1097/BRS.0b013e31828be75d.
23. Singh K, Marquez-Lara A, Nandyala SV, Patel AA, Fineberg SJ. Incidence and risk factors for dysphagia after anterior cervical fusion. *Spine* 2013;38(21):1820-5. doi: 10.1097/BRS.0b013e3182a3dbda.
24. Singh K, Nandyala SV, Marquez-Lara A, Fineberg SJ. Epidemiological trends in the utilization of bone morphogenetic protein in spinal fusions from 2002 to 2011. *Spine* 2014;39(6):491-6. doi: 10.1097/BRS.0000000000000167.
25. Zhan C, Kaczmarek R, Loyo-Berrios N, Sangl J, Bright RA. Incidence and short-term outcomes of primary and revision hip replacement in the United States. *J Bone Joint Surg Am* 2007;89(3):526-33. doi: 10.2106/JBJS.F.00952.
26. Austin PC, Tu JV, Alter DA. Comparing hierarchical modeling with traditional logistic regression analysis among patients hospitalized with acute myocardial infarction: should we be analyzing cardiovascular outcomes data differently? *Am Heart J* 2003;145(1):27-35.
27. Casals M, Girabent-Farrés M, Carrasco JL. Methodological quality and reporting of generalized linear mixed models in clinical medicine (2000–2012): a systematic review. *PLoS One* 2014;9(11):e112653. doi: 10.1371/journal.pone.0112653.
28. Randsborg P-H, Sivertsen EA, Skråmm I, Saltyt

- Benth J rat, Gulbrandsen P. The need for better analysis of observational studies in orthopedics: a retrospective study of elbow fractures in children. *Acta Orthop* 2010;81(3):377-81. doi: 10.3109/17453674.2010.487243.
29. Moverley R, Rankin KS, McNamara I, Davidson DJ, Reed M, Sprowson AP. Impact factors of orthopaedic journals between 2000 and 2010: trends and comparisons with other surgical specialties. *Int Orthop* 2013;37(4):561-7. doi: 10.1007/s00264-012-1769-1.
30. HCUP Elixhauser Comorbidity Software: Healthcare Cost and Utilization Project (HCUP). Rockville, MD: Agency for Healthcare Research and Quality. www.hcup-us.ahrq.gov/toolsoftware/comorbidity/comorbidity.jsp.
31. Alesh H, Riley LH, Skolasky RL. Insurance status, geography, race, and ethnicity as predictors of anterior cervical spine surgery rates and in-hospital mortality: an examination of United States trends from 1992 to 2005. *Spine* 2009;34(18):1956-62. doi: 10.1097/BRS.0b013e3181ab930e.
32. Banerjee D, Illingworth KD, Novicoff WM, Scaife SL, Jones BK, Saleh KJ. Rural vs. urban utilization of total joint arthroplasty. *J Arthroplasty* 2013;28(6):888-91. doi: 10.1016/j.arth.2012.09.004
33. Bekkers S, Bot AGJ, Makarawung D, Neuhaus V, Ring D. The National Hospital Discharge Survey and Nationwide Inpatient Sample: the databases used affect results in THA research. *Clin Orthop Relat Res* 2014;472(11):3441-9. doi: 10.1007/s11999-014-3836-y.
34. Bohl DD, Russo GS, Basques BA, et al. Variations in data collection methods between national databases affect study results: a comparison of the nationwide inpatient sample and national surgical quality improvement program databases for lumbar spine fusion procedures. *J Bone Joint Surg Am* 2014;96(23):e193. doi: 10.2106/JBJS.M.01490.
35. Bolognesi MP, Marchant MH, Viens NA, Cook C, Pietrobon R, Vail TP. The impact of diabetes on perioperative patient outcomes after total hip and total knee arthroplasty in the United States. *J Arthroplasty* 2008(suppl 1 pt 6):23:92-8. doi: 10.1016/j.arth.2008.05.012.
36. Browne JA, Adib F, Brown TE, Novicoff WM. Transfusion rates are increasing following total hip arthroplasty: risk factors and outcomes. *J Arthroplasty* 2013;28(suppl 8):34-7. doi: 10.1016/j.arth.2013.03.035.
37. Browne JA, Cook C, Hofmann AA, Bolognesi MP. Postoperative morbidity and mortality following total knee arthroplasty with computer navigation. *The Knee* 2010;17(2):152-6. doi: 10.1016/j.knee.2009.08.002.
38. Browne JA, Cook C, Olson SA, Bolognesi MP. Resident duty-hour reform associated with increased morbidity following hip fracture. *J. Bone Joint Surg Am* 2009;91(9):2079-85. doi: 10.2106/JBJS.H.01240.
39. Browne JA, Sandberg BF, D'Apuzzo MR, Novicoff WM. Depression is associated with early postoperative outcomes following total joint arthroplasty: a nationwide database study. *J Arthroplasty* 2014;29(3):481-3. doi: 10.1016/j.arth.2013.08.025.
40. Cook C, Hawkins R, Aldridge JM, Tolan S, Krupp R, Bolognesi M. Comparison of perioperative complications in patients with and without rheumatoid arthritis who receive total elbow replacement. *J Shoulder Elb Surg Am* 2009;18(1):21-6. doi: 10.1016/j.jse.2008.06.012.
41. Cook C, Santos GCM, Lima R, Pietrobon R, Jacobs DO, Richardson W. Geographic variation in lumbar fusion for degenerative disorders: 1990 to 2000. *Spine J* 2007;7(5):552-7.
42. Dagostino PR, Whitmore RG, Smith GA, Maltenfort MG, Ratliff JK. Impact of bone morphogenetic proteins on frequency of revision surgery, use of autograft bone, and total hospital charges in surgery for lumbar degenerative disease: review of the Nationwide Inpatient Sample from 2002 to 2008. *Spine J* 2014;14(1):20-30. doi: 10.1016/j.spinee.2012.10.035.
43. D'Apuzzo MR, Keller TC, Novicoff WM, Browne JA. CT pulmonary angiography after total joint arthroplasty: overdiagnosis and iatrogenic harm? *Clin Orthop Relat Res* 2013;471(9):2737-42. doi: 10.1007/s11999-013-3041-4.
44. Davis DE, Paxton ES, Maltenfort M, Abboud J. Factors affecting hospital charges after total shoulder arthroplasty: an evaluation of the National Inpatient Sample database. *J Shoulder Elb Surg* 2014;23(12):1860-6. doi: 10.1016/j.jse.2014.04.002.
45. Day JS, Lau E, Ong KL, Williams GR, Ramsey ML, Kurtz SM. Prevalence and projections of total shoulder and elbow arthroplasty in the United States to 2015. *J Shoulder Elb Surg* 2010;19(8):1115-20. doi: 10.1016/j.jse.2010.02.009.
46. Doro C, Dimick J, Wainess R, Upchurch G, Urquhart A. Hospital volume and inpatient mortality outcomes of total hip arthroplasty in the United States. *J Arthroplasty* 2006;21(suppl 6 pt 2):10-6.
47. Doud AN, Weaver AA, Talton JW, et al. Has the incidence of thoracolumbar spine injuries increased in the United States from 1998 to 2011? *Clin Orthop Relat Res* 2015;473(1):297-304. doi: 10.1007/s11999-014-3870-9.
48. Farjoodi P, Skolasky RL, Riley LH. The effects of hospital and surgeon volume on postoperative complications after LumbarSpine surgery. *Spine* 2011;36(24):2069-75. doi: 10.1097/BRS.0b013e318202ac56.
49. Fehring TK, Odum SM, Troyer JL, Iorio R, Kurtz SM, Lau EC. Joint replacement access in 2016: a supply side crisis. *J Arthroplasty* 2010;25(8):1175-81. doi: 10.1016/j.arth.2010.07.025.
50. Ganesh SP, Pietrobon R, Cecilio WAC, Pan D, Lightdale N, Nunley JA. The impact of diabetes on patient outcomes after ankle fracture. *J Bone Joint Surg Am* 2005;87(8):

1712-8.

51. Gonzalez Della Valle A, Chiu YL, Ma Y, Mazumdar M, Memtsoudis SG. The metabolic syndrome in patients undergoing knee and hip arthroplasty: trends and in-hospital outcomes in the United States. *J Arthroplasty* 2012;27(1):1743-9.e1. doi: 10.1016/j.arth.2012.04.011.

52. Goz V, McCarthy I, Weinreb JH, et al. Venous thromboembolic events after spinal fusion: which patients are at high risk? *J Bone Joint Surg Am* 2014;96(11):936-42.

53. Goz V, Weinreb JH, McCarthy I, Schwab F, Lafage V, Errico TJ. Perioperative complications and mortality after spinal fusions: analysis of trends and risk factors. *Spine* 2013;38(22):1970-6. doi: 10.1097/BRS.0b013e3182a62527.

54. Griffin JW, Hadeed MM, Novicoff WM, Browne JA, Brockmeier SF. Patient age is a factor in early outcomes after shoulder arthroplasty. *J Shoulder Elb Surg* 2014;23(12):1867-71. doi: 10.1016/j.jse.2014.04.004.

55. Griffin JW, Novicoff WM, Browne JA, Brockmeier SF. Obstructive sleep apnea as a risk factor after shoulder arthroplasty. *J Shoulder Elb Surg* 2013;22(12):e6-e9. doi: 10.1016/j.jse.2013.06.003.

56. Griffin JW, Novicoff WM, Browne JA, Brockmeier SF. Morbid obesity in total shoulder arthroplasty: risk, outcomes, and cost analysis. *J Shoulder Elb Surg* 2014;23(10):1444-8. doi: 10.1016/j.jse.2013.12.027.

57. Hambright D, Henderson RA, Cook C, Worrell T, Moorman CT, Bolognesi MP. A comparison of perioperative outcomes in patients with and without rheumatoid arthritis after receiving a total shoulder replacement arthroplasty. *J Shoulder Elb Surg* 2011;20(1):77-85. doi: 10.1016/j.jse.2010.03.005.

58. Iyengar JJ, Samagh SP, Schairer W, Singh G, Valone FH, Feeley BT. Current trends in rotator cuff repair: surgical technique, setting, and cost. *Arthrosc J* 2014;30(3):284-8. doi: 10.1016/j.arthro.2013.11.018.

59. Jain A, Hassanzadeh H, Strike SA, Skolasky RL, Riley LH. rhBMP use in cervical spine surgery: associated factors and in-hospital complications. *J Bone Joint Surg Am* 2014;96(8):617-623. doi: 10.2106/JBJS.M.00666.

60. Jain A, Kebaish KM, Sponseller PD. Factors associated with use of bone morphogenetic protein during pediatric spinal fusion surgery: an analysis of 4817 patients. *J Bone Joint Surg Am* 2013;95(14):1265-70. doi: 10.2106/JBJS.L.01118.

61. Jain A, Stein BE, Skolasky RL, Jones LC, Hungerford MW. Total joint arthroplasty in patients with rheumatoid arthritis: a United States experience from 1992 through 2005. *J Arthroplasty* 2012;27(6):881-8. doi: 10.1016/j.arth.2011.12.027.

62. Jain NB, Hocker S, Pietrobon R, Guller U, Bathia N, Higgins LD. Total arthroplasty versus hemiarthroplasty for glenohumeral osteoarthritis: role of provider volume. *J*

*Shoulder Elb Surg* 2005;14(4):361-7.

63. Jiang JJ, Toor AS, Shi LL, Koh JL. Analysis of perioperative complications in patients after total shoulder arthroplasty and reverse total shoulder arthroplasty. *J Shoulder Elb Surg* 2014;23(12):1852-9. doi: 10.1016/j.jse.2014.04.008.

64. Kalanithi PS, Patil CG, Boakye M. National complication rates and disposition after posterior lumbar fusion for acquired spondylolisthesis. *Spine* 2009;34(18):1963-9. doi: 10.1097/BRS.0b013e3181ae2243.

65. Kim SH, Wise BL, Zhang Y, Szabo RM. Increasing incidence of shoulder arthroplasty in the United States. *J Bone Joint Surg Am.* 2011;93(24):2249-54. doi: 10.2106/JBJS.J.01994.

66. Kurtz SM, Lau E, Ong K, Zhao K, Kelly M, Bozic KJ. Future young patient demand for primary and revision joint replacement: national projections from 2010 to 2030. *Clin Orthop Relat Res* 2009;467:2606-12. doi: 10.1007/s11999-009-0834-6.

67. Kurtz SM, Lau E, Watson H, Schmier JK, Parvizi J. Economic burden of periprosthetic joint infection in the United States. *J Arthroplasty* 2012;27(suppl 8):61-5.e1. doi: 10.1016/j.arth.2012.02.022.

68. Kurtz SM, Ong KL, Lau E, Bozic KJ. Impact of the economic downturn on total joint replacement demand in the United States: updated projections to 2021. *J Bone Joint Surg Am* 2014;96(8):624-30. doi: 10.2106/JBJS.M.00285.

69. Kurtz SM, Ong KL, Schmier J, Zhao K, Mowat F, Lau E. Primary and revision arthroplasty surgery caseloads in the United States from 1990 to 2004. *J Arthroplasty* 2009;24(2):195-203. doi: 10.1016/j.arth.2007.11.015.

70. Kurtz S, Ong K, Lau E, Mowat F, Halpern M. Projections of primary and revision hip and knee arthroplasty in the United States from 2005 to 2030. *J Bone Joint Surg Am.* 2007;89(4):780-5.

71. Li G, Patil CG, Lad SP, Ho C, Tian W, Boakye M. Effects of age and comorbidities on complication rates and adverse outcomes after lumbar laminectomy in elderly patients. *Spine* 2008;33(11):1250-5. doi: 10.1097/BRS.0b013e3181714a44.

72. Lin CA, Kuo AC, Takemoto S. Comorbidities and perioperative complications in HIV-positive patients undergoing primary total hip and knee arthroplasty. *J Bone Joint Surg Am* 2013;95(11):1028-36. doi: 10.2106/JBJS.L.00269.

73. Maltenfort MG, Rasouli MR, Morrison TA, Parvizi J. *Clostridium difficile* colitis in patients undergoing lower-extremity arthroplasty: rare infection with major impact. *Clin Orthop Relat Res* 2013;471(1):3178-85. doi: 10.1007/s11999-013-2906-x.

74. Marchant MH, Viens NA, Cook C, Vail TP, Bolognesi MP. The impact of glycemic control and diabetes mellitus

- on perioperative outcomes after total joint arthroplasty. *J Bone Joint Surg Am* 2009;91(7):1621-9. doi: 10.2106/JBJS.H.00116.
75. Matlock D, Earnest M, Epstein A. Utilization of elective hip and knee arthroplasty by age and payer. *Clin Orthop Relat Res* 2008;466(4):914-9. doi: 10.1007/s11999-008-0122-x.
76. Memtsoudis SG, Dy CJ, Ma Y, Chiu Y-L, Della Valle AG, Mazumdar M. In-hospital patient falls after total joint arthroplasty: incidence, demographics, and risk factors in the United States. *J Arthroplasty* 2012;27(6):823-8.e1. doi: 10.1016/j.arth.2011.10.010.
77. Memtsoudis SG, Hughes A, Ma Y, Chiu YL, Sama AA, Girardi FP. Increased in-hospital complications after primary posterior versus primary anterior cervical fusion. *Clin Orthop Relat Res* 2011;469(3):649-57. doi: 10.1007/s11999-010-1549-4.
78. Memtsoudis SG, Kirksey M, Ma Y, et al. Metabolic syndrome and lumbar spine fusion surgery: epidemiology and perioperative outcomes. *Spine* 2012;37(11):989-95. doi: 10.1097/BRS.0b013e31823a3a13.
79. Memtsoudis SG, Pumberger M, Ma Y, et al. Epidemiology and risk factors for perioperative mortality after total hip and knee arthroplasty. *J Orthop Res* 2012;30(11):1811-21. doi: 10.1002/jor.22139.
80. Memtsoudis SG, Vougioukas VI, Ma Y, Gaber-Baylis LK, Girardi FP. Perioperative morbidity and mortality after anterior, posterior, and anterior/posterior spine fusion surgery. *Spine* 2011;36(22):1867-77. doi: 10.1097/BRS.0b013e3181c7decc.
81. Menendez ME, Ring D. Minorities are less likely to receive autologous blood transfusion for major elective orthopaedic surgery. *Clin Orthop Relat Res* 2014;472(11):3559-66. doi: 10.1007/s11999-014-3793-5.
82. Nandyala SV, Marquez-Lara A, Fineberg SJ, Singh K. Perioperative characteristics and outcomes of patients undergoing anterior cervical fusion in July: analysis of the "July effect." *Spine* 2014;39(7):612-7. doi: 10.1097/BRS.000000000000182.
83. Nesterenko SO, Riley LH, Skolasky RL. Anterior cervical discectomy and fusion versus cervical disc arthroplasty: current state and trends in treatment for cervical disc pathology. *Spine* 2012;37(17):1470-4. doi: 10.1097/BRS.0b013e31824ee623.
84. Nuño M, Drazin DG, Acosta FL. Differences in treatments and outcomes for idiopathic scoliosis patients treated in the United States from 1998 to 2007: impact of socioeconomic variables and ethnicity. *Spine J* 2013;13(2):116-123. doi: 10.1016/j.spinee.2012.10.005.
85. Odum SM, Springer BD. In-hospital complication rates and associated factors after simultaneous bilateral versus unilateral total knee arthroplasty. *J Bone Joint Surg Am* 2014;96(13):1058-65. doi: 10.2106/JBJS.M.00065.
86. Odum SM, Springer BD, Dennon AC, Fehring TK. National obesity trends in total knee arthroplasty. *J Arthroplasty* 2013;28(suppl 8):148-51. doi: 10.1016/j.arth.2013.02.036.
87. Passias PG, Ma Y, Chiu YL, Mazumdar M, Girardi FP, Memtsoudis SG. Comparative safety of simultaneous and staged anterior and posterior spinal surgery. *Spine* 2012;37(3):247-55. doi: 10.1097/BRS.0b013e31821350d0.
88. Patil CG, Lad EM, Lad SP, Ho C, Boakye M. Visual loss after spine surgery: a population-based study. *Spine* 2008;33(13):1491-6. doi: 10.1097/BRS.0b013e318175d1bf.
89. Patil CG, Santarelli J, Lad SP, Ho C, Tian W, Boakye M. Inpatient complications, mortality, and discharge disposition after surgical correction of idiopathic scoliosis: a national perspective. *Spine J* 2008;8(6):904-10. doi: 10.1016/j.spinee.2008.02.002.
90. Ponce BA, Menendez ME, Oladeji LO, Soldado F. Diabetes as a risk factor for poorer early postoperative outcomes after shoulder arthroplasty. *J Shoulder Elb Surg* 2014;23(5):671-8. doi: 10.1016/j.jse.2014.01.046.
91. Poultsides LA, Ma Y, Della Valle AG, Chiu Y-L, Sculco TP, Memtsoudis SG. In-hospital surgical site infections after primary hip and knee arthroplasty--incidence and risk factors. *J Arthroplasty* 2013;28(3):385-9. doi: 10.1016/j.arth.2012.06.027.
92. Pumberger M, Chiu Y-L, Ma Y, Girardi FP, Mazumdar M, Memtsoudis SG. National in-hospital morbidity and mortality trends after lumbar fusion surgery between 1998 and 2008. *J Bone Joint Surg Br* 2012;94(3):359-64. doi: 10.1302/0301-620X.94B3.27825.
93. Pumberger M, Chiu YL, Ma Y, Girardi FP, Vougioukas V, Memtsoudis SG. Perioperative mortality after lumbar spinal fusion surgery: an analysis of epidemiology and risk factors. *Eur Spine J* 2012;21(8):1633-9. doi: 10.1007/s00586-012-2298-8.
94. Raikin SM, Rasouli MR, Espandar R, Maltenfort MG. Trends in treatment of advanced ankle arthropathy by total ankle replacement or ankle fusion. *Foot Ankle Int* 2014;35(3):216-24. doi: 10.1177/1071100713517101.
95. Rasouli MR, Maltenfort MG, Purtill JJ, Hozack WJ, Parvizi J. Has the rate of in-hospital infections after total joint arthroplasty decreased? *Clin. Orthop Relat Res* 2013;471(1):3102-11. doi: 10.1007/s11999-013-2949-z.
96. Rasouli MR, Maltenfort MG, Ross D, Hozack WJ, Memtsoudis SG, Parvizi J. Perioperative morbidity and mortality following bilateral total hip arthroplasty. *J Arthroplasty* 2014;29(1):142-8. doi: 10.1016/j.arth.2013.04.001.
97. Sams JD, Francis ML, Scaife SL, Robinson BS, Novicoff WM, Saleh KJ. Redefining revision total hip arthroplasty based on hospital admission status. *J Arthroplasty*



- 2012;27(5):758-63. doi: 10.1016/j.arth.2011.09.007.
98. Shah SN, Wainess RM, Karunakar MA. Hemiarthroplasty for femoral neck fracture in the elderly surgeon and hospital volume-related outcomes. *J Arthroplasty* 2005;20(4):503-8. doi: 10.1016/j.arth.2004.03.025.
99. Shamji MF, Cook C, Pietrobon R, Tackett S, Brown C, Isaacs RE. Impact of surgical approach on complications and resource utilization of cervical spine fusion: a nationwide perspective to the surgical treatment of diffuse cervical spondylosis. *Spine J* 2009;9(1):31-8. doi: 10.1016/j.spinee.2008.07.005.
100. Skolasky RL, Maggard AM, Thorpe RJ, Wegener ST, Riley LH. United States hospital admissions for lumbar spinal stenosis: racial and ethnic differences, 2000 through 2009. *Spine* 2013;38(26):2272-8. doi: 10.1097/BRS.0b013e3182a3d392.
101. Skolasky RL, Thorpe RJ, Wegener ST, Riley LH. Complications and mortality in cervical spine surgery: racial differences. *Spine* 2014;39(18):1506-12. doi: 10.1097/BRS.0000000000000429.
102. Toor AS, Jiang JJ, Shi LL, Koh JL. Comparison of perioperative complications after total elbow arthroplasty in patients with and without diabetes. *J Shoulder Elb Surg* 2014;23(11):1599-1606. doi: 10.1016/j.jse.2014.06.045.
103. Vegini JB, Steglich V, Bonilauri Ferreira AP, Gandhi M, Shah J, Pietrobon R. Do insurance and race represent independent predictors of undergoing total shoulder arthroplasty? A secondary data analysis of 3529 patients. *J Shoulder Elb Surg* 2012;21(5):661-6. doi: 10.1016/j.jse.2011.02.007.
104. Yeung SM, Davis AM, Soric R. Factors influencing inpatient rehabilitation length of stay following revision hip replacements: a retrospective study. *BMC Musculoskeletal Disord* 2010;11:252. doi: 10.1186/1471-2474-11-252.
105. Yoshihara H, Yoneoka D. Incidental dural tear in lumbar spinal decompression and discectomy: analysis of a nationwide database. *Arch Orthop Trauma Surg* 2013(11);133:1501-8. doi: 10.1007/s00402-013-1843-1.
106. Yoshihara H, Yoneoka D. Incidental dural tear in spine surgery: analysis of a nationwide database. *Eur Spine J* 2014;23:389-94. doi: 10.1007/s00586-013-3091-z.
107. Yoshihara H, Yoneoka D. Trends in the incidence and in-hospital outcomes of elective major orthopaedic surgery in patients eighty years of age and older in the United States from 2000 to 2009. *J Bone Joint Surg Am* 2014;96(14):1185-91. doi: 10.2106/JBJS.M.01126.
108. Yoshihara H, Yoneoka D. Predictors of allogeneic blood transfusion in total hip and knee arthroplasty in the United States, 2000-2009. *J Arthroplasty* 2014;29(9):1736-40. doi: 10.1016/j.arth.2014.04.026.
109. Yoshihara H, Yoneoka D. National trends in the utilization of blood transfusions in total hip and knee arthroplasty. *J Arthroplasty* 2014;29(1):1932-7. doi: 10.1016/j.arth.2014.04.029.
110. Zahir U, Sterling RS, Pellegrini VD, Forte ML. Inpatient pulmonary embolism after elective primary total hip and knee arthroplasty in the United States. *J Bone Joint Surg Am* 2013;95(22):e175. doi: 10.2106/JBJS.L.00466.
111. Zampini JM, White AP, McGuire KJ. Comparison of 5766 vertebral compression fractures treated with or without kyphoplasty. *Clin Orthop Relat Res.* 2010;468(7):1773-80. doi: 10.1007/s11999-010-1279-7.
112. Zionts LE, Zhao G, Hitchcock K, Maewal J, Ebramzadeh E. Has the rate of extensive surgery to treat idiopathic clubfoot declined in the United States? *J Bone Joint Surg Am* 2010;92(4):882-9. doi: 10.2106/JBJS.I.00819.
113. Bae HW, Rajae SS, Kanim LE. Nationwide trends in the surgical management of lumbar spinal stenosis. *Spine* 2013;38(11):916-26. doi: 10.1097/BRS.0b013e3182833e7c.
114. Bozic KJ, Kurtz S, Lau E, et al. The epidemiology of bearing surface usage in total hip arthroplasty in the United States. *J Bone Joint Surg Am* 2009;91(7):1614-20. doi: 10.2106/JBJS.H.01220.
115. Clement RC, Carr BG, Kallan MJ, Reilly PM, Mehta S. Who needs an orthopedic trauma surgeon? An analysis of US national injury patterns. *J Trauma Acute Care Surg* 2013;75(4):687-92.
116. Derman PB, Fabricant PD, David G. The role of overweight and obesity in relation to the more rapid growth of total knee arthroplasty volume compared with total hip arthroplasty. *J Bone Joint Surg Am* 2014;96(11):922-8.
117. Deyo RA, Gray DT, Kreuter W, Mirza S, Martin BI. United States trends in lumbar fusion surgery for degenerative conditions. *Spine* 2005;30(12):1444-5; discussion 1446-7.
118. Goz V, Weinreb JH, Schwab F, Lafage V, Errico TJ. Comparison of complications, costs, and length of stay of three different lumbar interbody fusion techniques: an analysis of the Nationwide Inpatient Sample database. *Spine J* 2014;14(9):2019-27. doi: 10.1016/j.spinee.2013.11.050.
119. Kurtz SM, Lau E, Ianuzzi A, et al. National revision burden for lumbar total disc replacement in the United States: epidemiologic and economic perspectives. *Spine* 2010;35(6):690-6. doi: 10.1097/BRS.0b013e3181d0fab.
120. Kurtz SM, Lau E, Schmier J, Ong KL, Zhao K, Parvizi J. Infection burden for hip and knee arthroplasty in the United States. *J Arthroplasty.* 2008;23(7):984-91. doi: 10.1016/j.arth.2007.10.017.
121. Losina E, Thornhill TS, Rome BN, Wright J, Katz JN. The dramatic increase in total knee replacement utilization rates in the United States cannot be fully explained by

- growth in population size and the obesity epidemic. *J Bone Joint Surg Am.* 2012;94(3):201-7. doi: 10.2106/JBJS.J.01958.
122. Ong KL, Villarraga ML, Lau E, Carreon LY, Kurtz SM, Glassman SD. Off-label use of bone morphogenetic proteins in the United States using administrative data. *Spine* 2010;35(19):1794-800. doi: 10.1097/BRS.0b013e3181ecf6e4.
123. Rajae SS, Bae HW, Kanim LEA, Delamarter RB. Spinal fusion in the United States: analysis of trends from 1998 to 2008. *Spine* 2012;37(1):67-76. doi: 10.1097/BRS.0b013e31820cccfb.
124. Schenker ML, Ahn J, Donegan D, Mehta S, Baldwin KD. The cost of after-hours operative debridement of open tibia fractures. *J Orthop Trauma* 2014;28(11):626-31. doi: 10.1097/BOT.000000000000078.
125. Stein BE, Hassanzadeh H, Jain A, Lemma MA, Cohen DB, Kebaish KM. Changing trends in cervical spine fusions in patients with rheumatoid arthritis. *Spine* 2014;39(15):1178-82. doi: 10.1097/BRS.0000000000000376.
126. Ziran BH, Barrette-Grischow MK, Marucci K. Economic value of orthopaedic trauma: the (second to) bottom line. *J Orthop Trauma* 2008;22(4):227-33. doi: 10.1097/BOT.0b013e31816bae67.
127. Johnson AJ, Mont MA, Tsao AK, Jones LC. Treatment of femoral head osteonecrosis in the United States: 16-year analysis of the Nationwide Inpatient Sample. *Clin Orthop Relat Res* 2014;472(2):617-23. doi: 10.1007/s11999-013-3220-3.
128. Ko LJM, DeHart ML, Yoo JU, Huff TW. Popliteal artery injury associated with total knee arthroplasty: trends, costs and risk factors. *J Arthroplasty.* 2014;29(6):1181-4. doi: 10.1016/j.arth.2014.01.007.
129. Marquez-Lara A, Nandyala SV, Fineberg SJ, Singh K. Current trends in demographics, practice, and in-hospital outcomes in cervical spine surgery: a national database analysis between 2002 and 2011. *Spine* 2014;39(6):476-81. doi: 10.1097/BRS.0000000000000165.
130. Nandyala SV, Marquez-Lara A, Fineberg SJ, Singh K. Comparison of revision surgeries for one- to two-level cervical TDR and ACDF from 2002 to 2011. *Spine J* 2014;14(12):2841-6. doi: 10.1016/j.spinee.2014.03.037.
131. Rajae SS, Trofa D, Matzkin E, Smith E. National trends in primary total hip arthroplasty in extremely young patients: a focus on bearing surface usage. *J Arthroplasty* 2012;27(10):1870-8. doi: 10.1016/j.arth.2012.04.006.
132. Sullivan MP, Baldwin KD, Donegan DJ, Mehta S, Ahn J. Geriatric fractures about the hip: divergent patterns in the proximal femur, acetabulum, and pelvis. *Orthopedics* 2014;37(3):151-157. doi: 10.3928/01477447-20140225-50.
133. Browne JA, Novicoff WM, D'Apuzzo MR. Medicaid payer status is associated with in-hospital morbidity and resource utilization following primary total joint arthroplasty. *J Bone Joint Surg Am* 2014;96(21):e180. doi: 10.2106/JBJS.N.00133.
134. Klika AK, Small TJ, Saleh A, Szubski CR, Chandran Pillai ALP, Barsoum WK. Primary total knee arthroplasty allogenic transfusion trends, length of stay, and complications: nationwide inpatient sample 2000-2009. *J Arthroplasty* 2014;29(11):2070-7. doi: 10.1016/j.arth.2014.06.018.
135. Odum SM, Troyer JL, Kelly MP, Dedini RD, Bozic KJ. A cost-utility analysis comparing the cost-effectiveness of simultaneous and staged bilateral total knee arthroplasty. *J Bone Joint Surg Am* 2013;95(16):1441-9. doi: 10.2106/JBJS.L.00373.
136. Saleh A, Small T, Chandran Pillai AL, Schiltz NK, Klika AK, Barsoum WK. Allogenic blood transfusion following total hip arthroplasty: results from the nationwide inpatient sample, 2000 to 2009. *J Bone Joint Surg Am* 2014;96(18):e155. doi: 10.2106/JBJS.M.00825.
137. Nikkel LE, Fox EJ, Black KP, Davis C, Andersen L, Hollenbeak CS. Impact of comorbidities on hospitalization costs following hip fracture. *J Bone Joint Surg Am* 2012;94(1):9-17. doi: 10.2106/JBJS.J.01077.
138. Styron JF, Koroukian SM, Klika AK, Barsoum WK. Patient versus provider characteristics impacting hospital lengths of stay following total knee or hip arthroplasty. *J Arthroplasty* 2011;26(8):1418-26.e1-e2. doi: 10.1016/j.arth.2010.11.008.
139. Jiang SL, Schairer WW, Bozic KJ. Increased rates of periprosthetic joint infection in patients with cirrhosis undergoing total joint arthroplasty. *Clin Orthop Relat Res* 2014;472(8):2483-91. doi: 10.1007/s11999-014-3593-y.

# Determining Frequency and Defining the Patient Profile of Sacral Insufficiency Fractures

Blake Obrock, DO<sup>\*a</sup>; Jeremy Wearn, MD<sup>†b</sup>; Matthew L. DeHart, MD<sup>†c</sup>;  
Paxton Gehling, BM<sup>‡</sup>; Amer M. Mirza, MD<sup>§</sup>

\*Legacy Emanuel Medical Center, Legacy Health, Portland, Oregon

†Department of Orthopaedics and Rehabilitation, Oregon Health & Science University, Portland, Oregon

‡School of Medicine, Oregon Health & Science University, Portland, Oregon

§Summit Orthopaedics, Portland, Oregon

## Changed Affiliations

<sup>a</sup>Department of Orthopaedics & Rehabilitation, The University of New Mexico Health Sciences Center, Albuquerque, New Mexico

<sup>b</sup>Tulane University Medical Center, New Orleans, Louisiana

<sup>c</sup>DeHart, MD. Legacy Emanuel Medical Center, Legacy Health, Portland, Oregon

## Abstract

*Background:* Insufficiency fractures at the sacrum represent a considerable cause of low back pain and disability within the geriatric population. However, there has never been a large-scale study examining the epidemiologic trends associated with the disease, and thus this condition has been largely under recognized.

*Methods:* This study analyzed a Nationwide Inpatient Sample (NIS) database to trend frequency and burden of sacral insufficiency fractures (SIF). All inpatient stays from 1998 to 2010 noted on the NIS were included if the case maintained at least one or more diagnostic code. A total of 257,697 unique admissions (63% women, 37% men) met our criteria.

*Results:* In 1998, there were 14,629 occurrences of SIF in the NIS population; this number steadily increased to 35,434 by 2010. This is a 142% increase in SIF frequency in a 12-year span. Congruently, there was an exponential increase in the total financial burden of SIF on the NIS healthcare institutions. In 1998, the total financial burden of SIF within the NIS database was \$581 million; this number increased to \$3.18 billion in 2010, which represents a 514% increase.

*Conclusions:* Overall, the frequency of SIF may be increasing as our population ages. Limited understanding of the disease characteristics has created a disproportionate burden on the healthcare system.

## Introduction

Stress fractures of the sacrum are typically classified into two categories: fatigue fractures and insufficiency fractures.<sup>1</sup> Fatigue fractures occur in normal bone owing to abnormally high stresses or loads. These fractures are more commonly seen in young athletes, military recruits and third trimester pregnancies.<sup>2-4</sup> Insufficiency fractures, on the other hand, occur under normal physiologic stresses in weakened bone and are an often-overlooked source of low back pain. Previously identified risk factors for sacral insufficiency fractures (SIF) include older age, osteoporosis, chronic systemic inflammatory disease, long-term corticosteroid use, and a history of pelvic radiotherapy.<sup>5-11</sup>

Patients with SIF typically present without a history of significant trauma but with acute, intractable low back and buttock pain which is worse with ambulation. These patients are often plagued by an acute and severe decline in mobility and ability to perform activities of daily living. No specific classification scheme has been developed to categorize SIF. However, using the Denis classification for stratifying risk of neurological compromise, most SIF fall into zone 1 and run a vertical course parallel to the sacroiliac joint.<sup>2</sup> Long-standing neurologic deficits are exceptionally rare with this fracture pattern, although patients may have an acute exacerbation of underlying lumbar stenosis or radiculopathy owing to altered body mechanics. Further complicating this presentation is a high association with pubic rami fractures, occurring in as many as 78% of patients,<sup>12</sup> causing poorly localized parasymphseal pain.

Findings of initial radiographs are often inconclusive, but the presence of an isolated pubic rami fracture on radiograph may be suggestive of an occult sacral injury. Advanced imaging is often required to confirm the diagnosis. Computed tomography, magnetic resonance imaging, and technetium 99<sup>m</sup> bone scintigraphy have all been used successfully.

Treatment options focus on conservative management of SIF, with liberal use of analgesics and early mobilization. Various biophysical adjunct therapies have been successful, including pulsed electromagnetic fields, low-intensity pulsed ultrasound, and extracorporeal shockwave therapy. Unfortunately, these biophysical adjuncts are significantly limited by availability in most geographic areas. Interventional sacroplasty has been used successfully to rapidly improve pain scores and time to mobilization.<sup>13</sup> Similar procedures used for vertebral insufficiency fractures have a well-established safety profile and track record, but use in treating SIF is limited owing to lack of long-term studies and concerns of polymethylmethacrylate damage to nearby nerves and vessels.<sup>1</sup> Surgical treatment has been reserved for patients with instability or neurologic deficits, and includes osteosynthesis with trans-sacral positioning bar, iliolumbar plate fixation, and screw fixation often supplemented by cement due to underlying osteoporosis.

SIF represent an important subset of sacral stress fractures, and a significant cause of low back pain and disability within the geriatric population. As the older-aged population continues to increase, a similar rise in incidence is expected. Despite improved awareness of the condition, very little information exists regarding annual frequency and the magnitude of impact that accompanies this underdiagnosed condition.<sup>13</sup> Therefore, our specific aims were to answer the following questions. First, what is the incidence of SIF nationally? Second, what patient characteristics are associated with SIF? Finally, what is the associated financial burden of managing SIF? We hypothesized that incidence of SIF would increase during the time frame examined, to mirror that of an aging population.

## Methods

By virtue of the de-identified nature of the dataset, this study was awarded an exemption from our investigative review board. We used the Agency for Healthcare Research and Quality (AHRQ) Healthcare Cost and Utilization Project (HCUP) National Inpatient Sample (NIS) database to estimate annual incidence, patient characteristics, and financial burden associated with SIF.<sup>1</sup> The NIS is the largest inpatient all-payer database in the US, representing

more than 8 million inpatient stays per year in 1000 hospitals. This approximates a 20% stratified sample of US community hospitals. The sample has grown from 24 states in 1999 to 45 states in 2011. The NIS represents a stratified probability sample of hospitals, with sampling probabilities proportional to the number of US community hospitals in each stratum. Discharge data can be implemented to create national estimates. Despite changes in numbers of states sampled, the sampling method has remained constant since 1998 to reflect the cross-sectional population of hospitals. Notably, the NIS contains discharge-level records, not patient-level records. Names and identifying information have been removed to protect privacy.

The NIS database provides information regarding the index hospital admission and includes patient demographic data; primary and secondary diagnoses (including the diagnoses for 27 types of patient comorbidities); primary and secondary procedures; hospital characteristics; and discharge information. The International Classification of Diseases, Ninth Revision (ICD-9) codes can be used to identify adult patients (aged ≥ 18 years) with a diagnosis of SIF. We analyzed the prevalence and trends since 1998 and the healthcare cost of SIF. For each year of the AHRQ HCUP NIS beginning in 1998 and ending in 2010, all inpatient stays were included if the case maintained at least one or more diagnostic ICD-9-CM code shown in Table 1. A total of 257,697 unique admissions (63% women, 37% men) met our criteria for SIF from 1998-2010.

**Table 1.** ICD-9 code used as inclusion criteria in the current study

Code	Description
805.6	Sacrum and coccyx, closed
805.7	Sacrum and coccyx, open
806.6	Sacrum and coccyx, closed
806.60	With unspecified spinal cord injury
806.61	With complete cauda equina lesion
806.62	With other cauda equina injury
806.69	With other spinal cord injury
806.7	Sacrum and coccyx, open
806.70	With unspecified spinal cord injury
806.71	With complete cauda equina lesion
806.72	With other cauda equina injury
806.79	With other spinal cord injury
806.8	Unspecified, closed
806.9	Unspecified, open

ICD-9, the International Classification of Diseases, Ninth Revision.

## Results

Overall, a 3% hospital mortality rate was associated with SIF. The 27 selected comorbidities were ranked according to their relative frequency (Table 2).

The frequency of SIF increased steadily, ranging from 14,629 in 1998 to 35,434 in 2010 (Figure 1). This represents a 142% increase in 12 years, averaging an 11.8% increase in the frequency per year.

A 21.3% increase was found in the mean age of patients who experienced SIF from 1998 to 2010 ( $P < 0.001$ ). In 1998, the mean age was 47 years; this number increased to 57 years in 2010 and maximized in 2008 with a mean age of 60 years (Figure 2). On average, there was a 10-month increase in the mean age per year followed by this study.

No significant fluctuation was noted in length of hospital stay for patients with SIF during the 12-year period. Patients stayed a median of 6 days from 1998 to 2006 and 5 days from 2006 to 2010. Mean length of stay was greater than the median by an average of 3 days. However, the mean measure of central tendency was skewed by an unacceptable amount because of the outliers in the database. For this reason, we believed that the median is a more clinically relevant measure of central tendency.

There was a steady increase in the adjusted mean total hospital charges incurred by patients diagnosed with SIF from 1998 to 2010 (Figure 3). In 1998, the adjusted mean hospital charge was \$40,424. This number increased to \$90,688 in 2010 and represented a 124% increase in charges during a 12-year span ( $P < 0.001$ ), averaging a 10.3% increase in the charges per year. The most dramatic increase occurred between 2009 and 2010, during which the mean charge grew 19.2% (\$76,065 to \$90,688;  $P < 0.001$ ). All reported cost values had been converted to 2010 dollars and were listed as the adjusted value.

The adjusted total financial burden of SIF on the NIS healthcare institutions and their patients increased by 514% (Figure 4). The adjusted total financial burden of SIF increased from \$581 million in 1998 to \$3.18 billion in 2010 ( $P < 0.001$ ). The largest increase occurred between 2009 and 2010 (\$2.23 billion to \$3.18 billion;  $P < 0.001$ ).

**Table 2.** The 27 selected comorbidities associated with sacral insufficiency fractures, ranked in order of frequency, within the National Inpatient Sample database from 1998-2010

Associated Diagnosis	Sum	Percentage (%)
Hypertension	68,480	29
Fluid and electrolyte abnormalities	39,159	17
Iron deficient anemia	25,619	11
Chronic pulmonary disease	25,482	11
Hypothyroidism	19,941	9
Diabetes	21,519	10
Uncomplicated	3657	8
Complicated	17,861	2
Depression	16,816	7
Alcohol abuse	14,612	6
Neurologic disorder	14,435	6
Congestive heart failure	12,541	5
Coagulopathy	9349	4
Recent weight loss	8578	4
Renal failure	8244	4
Drug abuse	7856	3
Psychosis	7172	3
Valvular disease	7251	3
Peripheral vascular disease	6216	3
Rheumatoid arthritis/ Collagen vascular disease	5306	2
Obesity	4434	2
Paralysis	3460	1
Chronic blood loss anemia	3339	1
Pulmonary circulatory disease	2714	1
Solid tumor with metastasis	2385	1
Liver disease	2857	1
Metastatic disease	1299	1
Lymphoma	828	< 1
Acquired immune deficiency	190	< 1

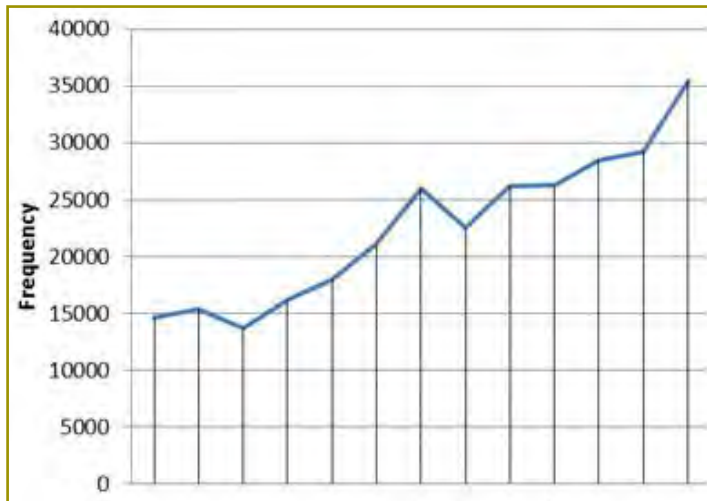


Figure 1. Yearly incidence of sacral insufficiency fractures within the National Inpatient Sample, plotted over the 12-year period.

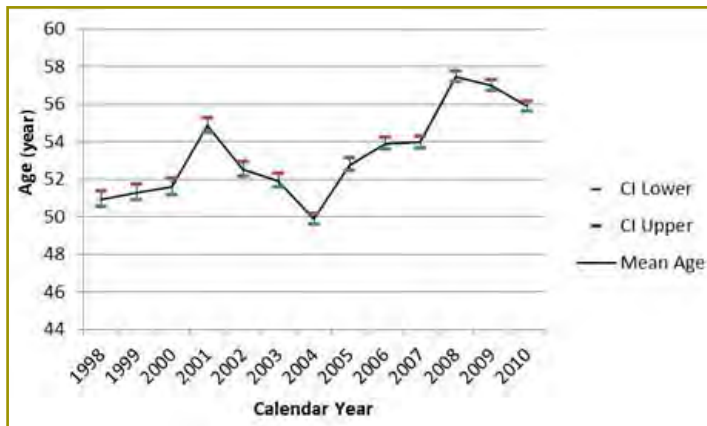


Figure 2. Mean age of patients with sacral insufficiency fractures, plotted over the 12-year period.

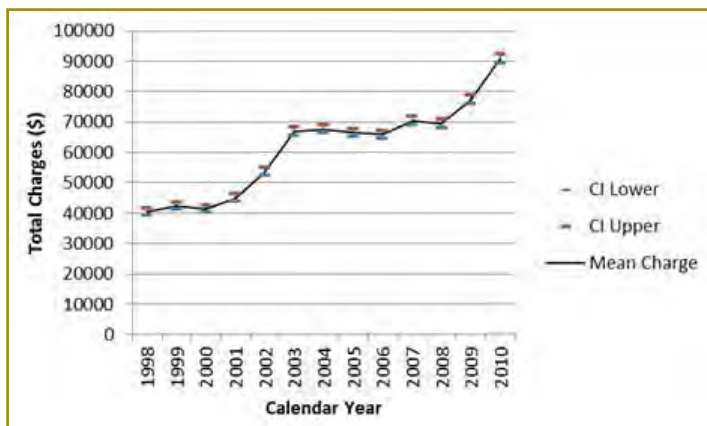


Figure 3. Inflation adjusted mean charges per year for patients with sacral insufficiency, plotted over the 12-year period.

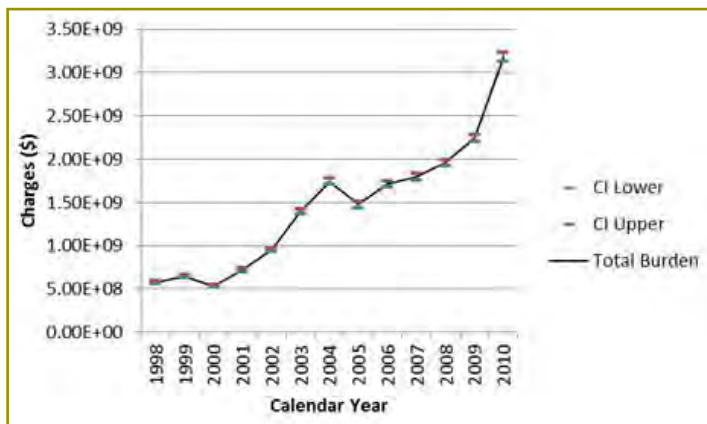


Figure 4. Total healthcare burden (incidence x median charges) for patients with sacral insufficiency fractures over the 12-year period.

## Discussion

To our knowledge, this is the largest study available that has evaluated the epidemiologic trends associated with SIF. There is a strong trend showing increasing frequency of SIF, by an average of 11.8% per year, and an increase in mean patient age at admission, by 21.3% per year. This may be because of the aging baby-boomer generation that is living longer. Women outnumbered men 2:1 in our study of SIF, which is consistent with previous reports showing an increasing age and female gender are main risk factors for SIF.<sup>5,7,8,10,11</sup>

Chronic systemic inflammatory disease and long-term corticosteroid use have been reported as independent risk factors for SIF.<sup>10,11,16</sup> This was also found in our study. Reports have indicated a baseline prevalence of 0.5% to 1% concerning rheumatoid arthritis,<sup>17</sup> although we found 2.3% of patients affected in our study. Chronic obstructive pulmonary disease (COPD) is also strongly associated with osteoporosis owing to systemic inflammation, smoking, and long-term corticosteroid use.<sup>18</sup> COPD has a baseline prevalence of 6.2% in some reports,<sup>18</sup> although we found an 11% prevalence in our study. Interestingly, the baseline prevalence of 1% to 4.6% has been described for hypothyroidism<sup>17</sup>; however, we found it present in 8.7% of our study population. There is a well-known association between hyperthyroidism and increased rates of bone resorption, making this finding somewhat counterintuitive. This finding probably reflects exogenous or iatrogenic hyperthyroidism, in which patients are over-treated with thyroid hormone replacement.<sup>19</sup> Comorbidities such as hypertension, iron-deficient anemia, diabetes, and depression were similar to national trends.

Total hospital-related costs increased by an average of 10.3% per year after adjusting for inflation. This trend is probably multifactorial but may be explained by the changing age demographic. Because the average age of patients with SIF has increased, more medical comorbidities are likely and require additional diagnostics, consultations, and therapies.

These results should be evaluated with some caution, as they represent a wide spectrum of patients, with a myriad of reasons for admission. It is impossible to know whether the coded SIF was the primary reason for admission or a secondary condition that complicated treatment. Furthermore, the cost of admission represents charges for all care related to the patient stay, not just SIF. Additionally, the nature of the current ICD-9 coding system makes it impossible to differentiate traumatic, isolated sacral fractures in patients with normal bone density from insufficiency fractures because they code identically. As a result, these non-insufficiency fractures

may skew the results and artificially lower the prevalence of the comorbidities noted in Table 2. Finally, this catchment of patients represents only the cases severe enough for inpatient admission. It is reasonable to assume that most patients who sustained an SIF did not require admission and were able to undergo conservative treatment as an outpatient; these fractures are not captured in the current study.

In summary, SIF represent an under-recognized but notable cause of low back pain and disability within the geriatric population. Furthermore, SIF imparts a disproportionate burden on our current healthcare system. As our population continues to age, the frequency and cost associated with these injuries will continue to increase. Improved understanding of the disease and prevention of osteoporosis will be key to reducing morbidity and costs associated with SIF.

## Funding

The authors received no financial support for the research, authorship, and publication of this article.

## Conflict of Interest

The authors report no conflicts of interest.

## References

1. Healthcare Cost and Utilization Project (HCUP). National Inpatient Sample [database]. Rockville, MD: Agency for Healthcare and Research Quality; 2012.
2. Aretxabala I, Fraiz E, Pérez-Ruiz F, Ríos G, Calabozo M, Alonso-Ruiz A. Sacral insufficiency fractures. High association with pubic rami fractures. *Clin Rheumatol* 2000;19(5):399-401.
3. Frey ME, Depalma MJ, Cifu DX, Bhagia SM, Carne W, Daitch JS. Percutaneous sacroplasty for osteoporotic sacral insufficiency fractures: a prospective, multicenter, observational pilot study. *Spine J* 2008;8(2):367-73.
4. Fuchs T, Rottbeck U, Hofbauer V, Raschke M, Stange R. Pelvic ring fractures in the elderly: underestimated osteoporotic fracture [in German]. *Unfallchirurg* 2011;114(8):663-70. doi: 10.1007/s00113-011-2020-z.
5. Golden SH, Robinson KA, Saldanha I, Anton B, Ladenson PW. Clinical review: prevalence and incidence of endocrine and metabolic disorders in the United States: a comprehensive review. *J Clin Endocrinol Metab* 2009;94(6):1853-78. doi: 10.1210/jc.2008-2291.
6. Iğdem S, Alço G, Ercan T, et al. Insufficiency fractures after pelvic radiotherapy in patients with prostate cancer.

- Int J Radiat Oncol Biol Phys 2010;77(3):818-23.  
doi: 10.1016/j.ijrobp.2009.05.059.
7. Kim HJ, Boland PJ, Meredith DS, et al. Fractures of the sacrum after chemoradiation for rectal carcinoma: incidence, risk factors, and radiographic evaluation. Int J Radiat Oncol Biol Phys 2012;84(3):694-9. doi: 10.1016/j.ijrobp.2012.01.021.
8. Lin J, Lachmann E, Nagler W. Sacral insufficiency fractures: a report of two cases and a review of the literature. J Womens Health Gend Based Med 2001;10(7):699-705.
9. Longhino V, Bonora C, Sansone V. The management of sacral stress fractures: current concepts. Clin Cases Miner Bone Metab 2011;8(3):19-23.
10. Nusselt T, Klingner HM, Schultz W, Baums MH. Fatigue stress fractures of the pelvis: a rare cause of low back pain in female athletes. Acta Orthop Belg 2010;76(6):838-43.
11. Pearson K. On the criterion that a given system of deviations from the probable in the case of a correlated system of variables is such that it can be reasonably supposed to have arisen from random sampling. Philos Mag 1900;50(302):157-75. doi: 10.1080/14786440009463897.
12. Pentecost RL, Murray RA, Brindley HH. Fatigue, insufficiency, and pathologic fractures. JAMA 1964;187:1001-4.
13. Rommens PM, Wagner D, Hofmann A. Osteoporotic fractures of the pelvic ring [in German]. Z Orthop Unfall 2012;150(3):e107-e118; quiz e119-20. doi: 10.1055/s-0032-1314948.
14. Shah MK, Stewart GW. Sacral stress fractures: an unusual cause of low back pain in an athlete. Spine (Phila Pa 1976) 2002;27(4):E104-8.
15. Tárraga López PJ, López CF, et al. Osteoporosis in patients with subclinical hypothyroidism treated with thyroid hormone. Clin Cases Miner Bone Metab 2011;8(3):44-8.
16. Tsiridis E, Upadhyay N, Giannoudis PV. Sacral insufficiency fractures: current concepts of management. Osteoporos Int 2006;17(12):1716-25.
17. Weber M, Hasler P, Gerber H. Sacral insufficiency fractures as an unsuspected cause of low back pain. Rheumatology (Oxford). 1999;38(1):90-1.
18. West SG, Troutner JL, Baker MR, Place HM. Sacral insufficiency fractures in rheumatoid arthritis. Spine (Phila Pa 1976) 1994;19(18):2117-21.
19. Zaman FM, Frey M, Slipman CW. Sacral stress fractures. Curr Sports Med Rep 2006;5(1):37-43.



# Radiographic Prevalence of Osteoarthritis of the Scaphotrapeziotrapezoid Joint in Patients With Carpometacarpal Osteoarthritis of the Thumb: A Retrospective Case Series

Charlotte E. Orr, MD<sup>\*a</sup>; Robert Mercer, BS<sup>†</sup>; Deana M. Mercer, MD<sup>\*</sup>;  
Drew K. Newhoff, MD<sup>\*</sup>; Matthew D. Martin, MD<sup>\*b</sup>; Moheb S. Moneim, MD<sup>\*</sup>

<sup>\*</sup>Department of Orthopaedics & Rehabilitation, The University of New Mexico Health Sciences Center, Albuquerque, New Mexico

<sup>†</sup>School of Medicine, The University of New Mexico Health Sciences Center, Albuquerque, New Mexico

## Changed Affiliations

<sup>a</sup>OrthoIndy, Indianapolis, Indiana

<sup>b</sup>Spectrum Health Butterworth Hospital, Grand Rapids, Michigan

## Abstract

**Background:** In planning operative treatment of thumb carpometacarpal (CMC) joint osteoarthritis, surgeons should consider the presence of an arthritic scaphotrapeziotrapezoid (STT) joint. We aimed to determine the radiographic prevalence of concomitant (STT) osteoarthritis with thumb CMC osteoarthritis in patients who underwent surgical treatment at our institution. We hypothesized that the prevalence of concomitant arthritis at these 2 joints (STT and CMC) would be lower than previously reported.

**Methods:** Between September 2005 and July 2012, a total of 417 patients were identified from our institution using the Current Procedural Terminology code for thumb CMC joint arthroplasty (25447). After applying exclusion criteria and identifying patients who underwent treatment, a total of 194 patients were included and 218 preoperative radiographs were available for review. Each radiograph was categorized according to the Eaton classification of thumb CMC osteoarthritis, with stage 4 involving the (STT) joint. Evaluation was performed by four reviewers independently.

**Results:** A total of 47 (21.6%) patients had varying degrees of concomitant (STT) joint osteoarthritis with the thumb CMC joint osteoarthritis. Stage 4 was reported in 6.4% (14) of the radiographs.

**Conclusions:** The radiographic prevalence of concomitant (STT) osteoarthritis with thumb CMC osteoarthritis may be lower than previously reported.

Further studies that include a similarly large sample size and additional radiographic views can help evaluate the likelihood of these conditions in patients who elect to undergo surgical treatment of thumb CMC osteoarthritis.

## Introduction

Thumb carpometacarpal (CMC) osteoarthritis can be considerably painful and disabling for patients. Radiographic prevalence of thumb CMC osteoarthritis has been described at 40% in women and 25% in men older than 75 years.<sup>1</sup> Symptoms can progress from an occasional ache to severe pain and weakness with thumb pinch and grasp. According to some studies, the scaphotrapeziotrapezoid (STT) joint can be affected in 46% to 49% of patients.<sup>2</sup> Isolated STT osteoarthritis without thumb CMC osteoarthritis can affect up to 16% of the population, mainly women older than 50 years.<sup>3,4</sup>

The Eaton classification is frequently used to describe thumb CMC osteoarthritis and can help direct treatment. Depending on the severity of joint involvement, different interventions can be considered.<sup>5</sup> In addition to nonoperative treatment such as therapy, splinting, and injections, surgeons have considered volar ligament reconstruction or metacarpal extension osteotomy for treating stages 1 and 2. Arthrodesis may be appropriate for treating stages 2 and 3 in younger, physically active patients. Implant arthroplasty is fraught with complications. Resection arthroplasty with or without ligament

interposition is currently the most commonly used procedure for treating thumb CMC osteoarthritis classified as stages 3 or 4. Partial or total trapeziectomy has also been recommended. In stage 4, complete trapeziectomy can be considered; however, complications such as thumb subsidence and instability have been noted.<sup>5,6</sup>

Despite the common occurrence of thumb CMC osteoarthritis, results of ClinicalTrials.gov and PubMed searches with and without use of the MeSH terms “thumb,” “carpometacarpal,” “arthritis,” and “scaphotrapezoidal” indicated that previous and ongoing studies have not addressed the preoperative radiographic prevalence of STT osteoarthritis occurring in conjunction with thumb CMC joint osteoarthritis. Yet diagnosis of an arthritic STT joint can help guide operative treatment. In patients with thumb CMC osteoarthritis that necessitates surgical treatment. We hypothesized that the prevalence of concomitant STT osteoarthritis would be lower than previously reported.

## Methods

Our study was approved by the Human Research Review Committee (HRRC #13-049). We searched our electronic medical records for the Current Procedural Terminology (CPT) codes relating to treatment of thumb CMC osteoarthritis (CPT, 25447) between September 2005 and July 2012, which identified 417 patients. Exclusion criteria involved previous operative treatment of thumb CMC or STT joint osteoarthritis and lack of preoperative hand radiographs. Patients were included who underwent surgical treatment of thumb CMC osteoarthritis and who also had preoperative hand radiographs available (n = 194). Because 24 of those patients underwent operative treatment of both hands, a total of 218 preoperative radiographs were available for review. Results of analysis performed before the study indicated that 200 sets of radiographs would be required to achieve statistical significance.

The 218 preoperative radiographs were reviewed independently by four individuals: an attending physician with subspecialty training in hand surgery, a fellow in hand surgery, a fifth-year resident, and a junior resident. Each reviewer classified each set of radiographs two times to allow calculation of intraobserver reliability. Interobserver reliability was also calculated.

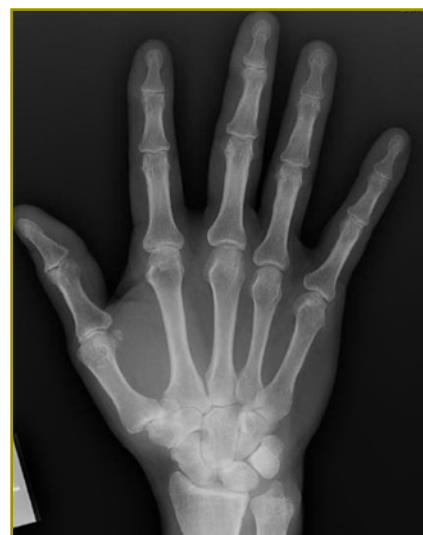Radiographs were categorized according to the Eaton classification.<sup>7</sup> Stage 1 indicates some joint widening but otherwise normal articular contours; stage 2, joint-space narrowing with minimal sclerosis and osteophytes or loose bodies less than 2 mm in diameter; stage 3, joint space narrowing to the point of being obliterated, including cysts, notable sclerosis, dorsal subluxation of the metacarpal on the trapezium, and osteophytes larger than 2 mm; and

stage 4, CMC joint is completely involved, with sclerotic or cystic changes to the STT joint.

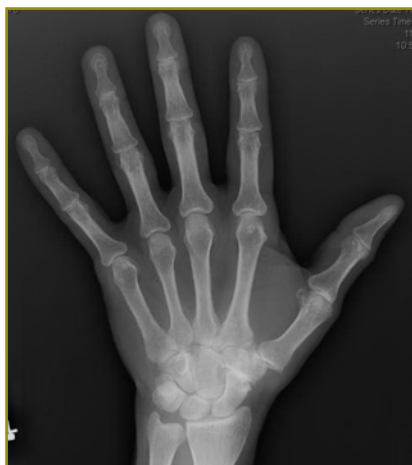## Results

Of the 218 preoperative radiographs, a total of 47 (21.6%) showed average Eaton stages of 3.5 or higher, indicating that most reviewers observed concomitant CMC and STT osteoarthritis on radiographs (Figure 1). A total of 14 radiographs (6.4%) were unanimously classified as stage 4 by our reviewers (Figure 2). The average Eaton stage (ie, the most common classification of each radiograph) was 3.03.

More experienced reviewers tended to classify lower stages (average, 2.83 and 2.95) than junior reviewers (average 3.10 and 3.24). These differences were not statistically significant, however. Interobserver reliability was fair, and Intraobserver reliability was rated as good for each individual observer (Table 1).



**Figure 1.** Radiograph of a hand, showing Eaton stage 3 classification with some involvement of the scaphotrapeziotrapezoid joint.



**Figure 2.** Radiograph of a hand, showing Eaton stage 4 classification with advanced degenerative changes of the scaphotrapeziotrapezoid joint.

**Table 1.** Inter- and intraobserver reliability data for Eaton stage classification of preoperative radiographs of the thumb carpometacarpal and scaphotrapezial joint

Reviewer #	Intraobserver reliability			Interobserver reliability
	$\kappa$	SE of $\kappa$	95% CI of $\kappa$	
1	0.837 (very good)	0.037	0.764-0.910	$\kappa = 0.278$ (fair) SE of $\kappa = 0.024$ 95% CI of $\kappa = 0.231$ to $0.325$
2	0.760 (good)	0.040	0.682-0.839	
3	0.623 (good)	0.040	0.544-0.702	
4	0.643 (good)	0.042	0.560- 0.725	

CI, confidence interval; SE, standard error;  $\kappa$  = Kappa.

## Discussion

Thumb CMC joint osteoarthritis is common and can cause considerable pain and disability in activities of daily living. Radiographic studies have described STT joint osteoarthritis at a prevalence between 27% and 59%; however, these studies often involved older patients with mean ages between 60 to 80 years.<sup>8-10</sup> The long-term effects of partial trapeziectomy on progression of osteoarthritis at the STT has been studied, with no indication of disease progression.<sup>11</sup> In the current study, our findings indicated a lower prevalence of STT osteoarthritis occurring with thumb CMC joint osteoarthritis (21.6%).

Brown et al<sup>2</sup> noted gross STT arthritic involvement in 60% of 69 cadaver specimens with thumb CMC osteoarthritis, and 39% of those specimens exhibited radiographic evidence of STT osteoarthritis. This study found a low correlation of radiographic findings with visual pathological features suggestive of STT osteoarthritis; however, the investigation did not indicate prevalence of STT osteoarthritis with concomitant thumb CMC osteoarthritis. This was, however, a cadaveric study with no inter- or intraobserver data. Routine radiographic views may have been inadequate to show the complex articulation of this joint.

Other studies have been completed to compare the accuracy of the Robert's and lateral views of staging trapeziometacarpal joint arthrosis. One study<sup>12</sup> confirmed that each of the Robert's and lateral views enhanced the ability to assess radiographic disease severity and was recommended for assessing trapeziometacarpal joint osteoarthritis. Our study indicated that the prevalence of STT osteoarthritis occurring with thumb CMC joint

osteoarthritis was 21.6%. Reviewers unanimously agreed on this in 6.4% (14) of radiographs.

The strengths of our study include an adequate number of patients for a well-powered analysis and good intraobserver reliability. Weaknesses include only fair interobserver reliability. Another limitation of our study is that routine preoperative radiographic views were used to illustrate the CMC joint. To better illustrate CMC joint articulations, we developed a new view that required minimal effort on the patient and simplified the hand positioning. This will be the subject of further evaluation.<sup>11</sup> Further studies with additional radiographic views that adequately profile this complex articulation can help evaluate the prevalence of STT osteoarthritis occurring with thumb CMC joint osteoarthritis in patients who undergo operative treatment of thumb CMC osteoarthritis.

## Funding

The authors received no financial support for the research, authorship, and publication of this article.

## Conflict of Interest

The authors report no conflicts of interest.

## References

1. Van Heest AE, Kallemeier P. Thumb carpal metacarpal arthritis. *J Am Acad Orthop Surg* 2008;16(3):140-51.
2. Brown GD 3rd, Roh MS, Strauch RJ, Rosenwasser MP, Ateshian GA, Mow VC. Radiography and visual pathology of the osteoarthritic scaphotrapezio-trapezoidal joint, and

- its relationship to trapeziometacarpal osteoarthritis. *J Hand Surg Am* 2003;28(5):739-43.
3. McLean JM, Turner PC, Bain GI, Rezaian N, Field J, Fogg Q. An association between lunate morphology and scaphoid-trapezium-trapezoid arthritis. *J Hand Surg Eur Vol* 2009;34(6):778-82. doi: 10.1177/1753193409345201.
  4. Kapoutsis DV, Dardas A, Day CS. Carpometacarpal and scaphotrapeziotrapezoid arthritis: arthroscopy, arthroplasty, and arthrodesis. *J Hand Surg Am* 2011;36(2):354-66. doi: 10.1016/j.jhsa.2010.11.047.
  5. Barron OA, Glickel SZ, Eaton RG. Basal joint arthritis of the thumb. *J Am Acad Orthop Surg* 2000;8(5):314-23.
  6. Salas C, Mercer DM, O'Mahony G, Love J, LaBaze D, Moneim MS. Thumb metacarpal subsidence after partial trapeziectomy with capsular interposition arthroplasty: a biomechanical study. *Hand (N Y)* 2016;11(4):444-9. doi: 10.1177/1558944715627994.
  7. Eaton RG, Glickel SZ. Trapeziometacarpal osteoarthritis: staging as a rationale for treatment. *Hand Clin* 1987;3(4):455-71.
  8. Scordino LE, Bernstein J, Nakashian M, et al. Radiographic prevalence of scaphotrapeziotrapezoid osteoarthrosis [published erratum in: *J Hand Surg Am* 2014;39(10):2124]. *J Hand Surg Am* 2014;39(9):1677-82. doi: 10.1016/j.jhsa.2014.05.033.
  9. Moritomo H, Viegas SF, Nakamura K, Dasilva MF, Patterson RM. The scaphotrapezio-trapezoidal joint: Part 1: an anatomic and radiographic study. *J Hand Surg Am* 2000;25(5):899-910.
  10. Bhatia A, Pisoh T, Touam C, Oberlin C. Incidence and distribution of scaphotrapezotrapezoidal arthritis in 73 fresh cadaveric wrists. *Ann Chir Main Memb Super* 1996;15(4):220-5.
  11. Noland SS, Saber S, Endress R, Hentz VR. The scaphotrapezoidal joint after partial trapeziectomy for trapeziometacarpal joint arthritis: long-term follow-up. *J Hand Surg Am* 2012;37(6):1125-9. doi: 10.1016/j.jhsa.2012.02.007.
  12. Oheb J, Lansinger Y, Jansen JA, Nguyen JQ, Porembski MA, Rayan GM. Radiographic assessment of the Robert and lateral views in trapeziometacarpal osteoarthrosis. *Hand Surg* 2015;20(2):251-9. doi: 10.1142/s0218810415500203.

# External Fixation for Treating Tibial Shaft Fractures Using a Triangular Two-Planar Frame: A Computational and Biomechanical Study

Christina Salas, PhD<sup>\*†‡</sup>; Daniel Hoopes, MD<sup>\*a</sup>; Mahmoud M. Reda Taha, PhD<sup>§</sup>; Thomas A. DeCoster MD<sup>\*</sup>

<sup>\*</sup>Department of Orthopaedics & Rehabilitation, The University of New Mexico Health Sciences Center, Albuquerque, New Mexico

<sup>†</sup>Department of Mechanical Engineering, The University of New Mexico, Albuquerque, New Mexico

<sup>‡</sup>Center for Biomedical Engineering, The University of New Mexico, Albuquerque, New Mexico

<sup>§</sup>Department of Civil Engineering, The University of New Mexico, Albuquerque, New Mexico

## Changed Affiliations

<sup>a</sup>Revere Health (formerly known as Central Utah Clinic), Lehi, Utah

## Abstract

**Background:** Construct stability is a necessary characteristic of external fixators. Many commonly used fixators are constructed as symmetric one-plane frames. We postulate that asymmetric two-plane triangular constructs provide enhanced stability with simplicity and freedom in pin placement. We hypothesized that results of finite element analysis would determine optimal geometric configuration, and findings of mechanical testing would confirm the improved stability of two-plane triangular constructs.

**Methods:** Finite element modeling was used to analyze configurations for 16 triangular designs compared to a single-rod (SR) uniplanar frame. Variables included pin axial angulation (0°, 22.5°, 45°, and 90°), connectivity of the rod-to-pin couplers, and intrafragmentary pin spacing (75mm or 100mm). Construct stiffness and interfragmentary displacement were analyzed for model selection. In a subsequent experimental test, nine synthetic composite tibiae were displaced to a maximum of 4 mm, comparing compressive load and axial stiffness of triangular construct with those of SR and pin-clamp (PC) uniplanar frames.

**Results:** Computational modeling showed that greater pin spacing results in increased stiffness ( $P < 0.001$ ), but increased interfragmentary displacement ( $P = 0.01$ ). 22.5° and 45° constructs were significantly stiffer than 0° constructs ( $P = 0.03$  and  $P = 0.01$ , respectively). Displacement was significantly less in 22.5°, 45°, and 90° than 0° constructs ( $P = 0.01$ ). Experimentally, the 22.5°

triangular multiplanar constructs were significantly stiffer with higher compressive loads than uniplanar constructs ( $P < 0.001$ ).

**Conclusions:** A two-plane triangular frame may be a more stable construct than the two symmetric uniplanar constructs tested. This configuration allows for greater adjustability than SR constructs, requiring no specialized devices as do PC constructs, while allowing simplicity and freedom of pin placement.

## Introduction

External fixators are used for temporary and definitive management of fractures. Originally developed for definitive fixation, the use of this method waned in the 1980s because internal fixation became popular.<sup>1</sup> In the 1990s, however, external fixators regained prominence in treating injuries associated with multiple traumas, frontlines of battle, third-world settings, and fractures with soft-tissue injury and subsequent high risk of infection (used as a temporizing measure).<sup>2,3</sup>

Compared to internal fixation, use of external fixators involves considerably less dissection of soft tissue and disruption of blood supply, which helps treat acute traumatic injuries in which extensive soft-tissue damage may limit or preclude the use of internal fixation devices.<sup>3,4</sup> Tibia fractures are a common indication for treatment with external fixation, including open tibia shaft fractures, distal tibia plafond fractures, and complex proximal tibia fractures with soft-tissue injury. In these regions subject

to high levels of anatomical loading, frame stability is essential to maintain reduction and limb alignment.

External fixation provides relative stability, in which endochondral healing can occur in early fracture healing.<sup>5,6</sup> Basic principles have been clearly defined and supported by numerous biomechanical studies, which support five common techniques for increasing frame stability:

- 1) increase the distance between pins within a fragment;
- 2) increase the number of pins within each fragment;
- 3) decrease the distance between the bone and frame;
- 4) add additional rods, tubes, and rings; and
- 5) use large diameter pins.<sup>3,4</sup> Some of these basic techniques have been addressed by manufacturers in developing external-fixation devices used today. Because fracture types can vary, the use of a single standardized technique may not be optimal for all surgical treatments.<sup>7</sup> A thorough understanding of basic mechanical principles and their implementation using universal and basic components of external fixation can help optimize construct design.

One of the most common frame designs in use is a simple, one-plane frame with parallel pins and a single longitudinal connecting rod or variations of that basic geometry (ie, use of specialized pin clamps).<sup>8</sup> We propose that the use of a truss design with two-plane triangular frame can increase structural stability, increase frame adjustability, and allow for controlled, interfragmentary motion while limiting the need for costly, specialized and bulky external fixation components. Even when applied to the short-term temporizing of fractures to stage future removal and placement of internal fixators, an improved stability increases the likelihood that the initial reduction will be maintained and patient comfort will be maximized.<sup>5,6</sup> The first aim of the current study was to develop a low-profile, triangular multiplanar external fixator configuration for treating tibial shaft fractures. The second aim was to experimentally compare the stiffness and compressive load (as measurements of construct stability) of the optimized multiplanar design to two commonly-used external fixators: the single rod (SR) uniplanar and pin-clamp (PC) uniplanar constructs.

## Methods

### *Computational Modeling and Validation (Aim 1)*

**Triangular multiplanar construct development.** Using computational modeling and analysis techniques, we investigated a novel, mechanically stable configuration of external fixation components for treating tibia shaft fractures. With careful measurement of each component used, we modeled Hoffmann II MRI external-fixation components (Stryker, Kalamazoo, MI) using SolidWorks

3D modeling software (Dassault Systemes, Waltham, MA). A design of experiments method was used to analyze possible configurations for the fixation components, with the general structure derived from the concept of a truss—one or more triangular units—designed to be compact yet structurally stable. The design emphasizes important biomechanical principles in external fixation and provides controlled interfragmentary motion for formation of new bone.<sup>9,10</sup> The optimal configuration would be more compact and inexpensive than uniplanar designs but provide increased structural stability and adjustability in all degrees of freedom for correction of initial malreductions, which is capable with pin-clamp and other unconstrained multiplanar constructs.<sup>11,12</sup>

There were three model variables: second and third (closest to fracture) pin axial angulation at 0°, 22.5°, 45°, and 90° from the most proximal (first) and distal (fourth) pins; connectivity of the rod-to-pin couplers of the first and fourth pins in outer or inner configuration (ie, away from or near central fracture, respectively); and pin spacing within each fragment (100 mm or 75 mm between innermost and outermost pins; Figure 1). The third variation is addressed in external fixation basic principles and is used for model validation.<sup>4</sup> Distance between frame and shaft (20 mm) and between innermost pins (ie, second and third pins; 50 mm) was minimized and kept constant.<sup>4,12</sup>

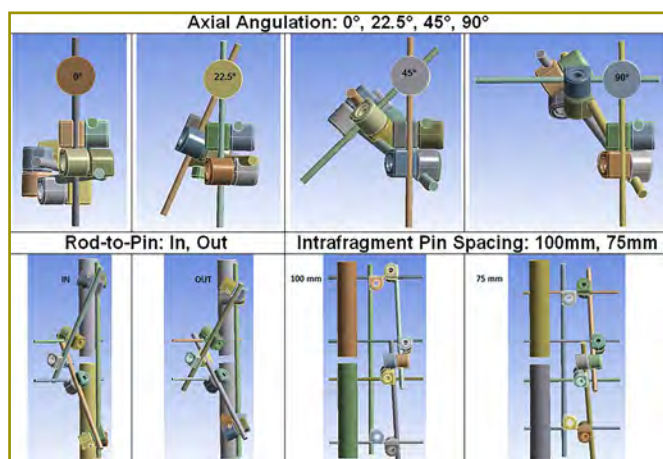
The 16 possible model configurations (treatments) are listed in Table 1. These configurations were computationally fixed to a 25.4-mm (1-inch) diameter solid cylindrical rod designed to mimic basic tibia shaft geometry. Each rod had a segment removed from the midsection to simulate a mid-shaft tibial fracture, with 10 mm of comminution. Construct stiffness and vertical interfragmentary displacement were analyzed for model selection. An ideal configuration would allow for high bone and implant construct stiffness and minimal interfragmentary displacement.

**Computational modeling parameters and boundary conditions.** ANSYS Workbench finite element software was used to analyze the models (Canonsburg, PA). Material properties were assigned to the external fixation components matching materials defined in the Osteosynthesis Hoffmann II MRI External Fixation Systems guide (Stryker, Kalamazoo, MI; stainless steel pins = 193 GPa, aluminum alloy couplers = 71 GPa, carbon fiber rods = 175 GPa). Material modulus assigned to the solid cylindrical rods matched Poplar wood used for experimental validation (10.9 GPa). Boundary conditions simulating a simplified model of single leg stance were defined. Bonded contact conditions were defined at all component interfaces, assuming that there is no loosening

of components during the simulated loading condition. The inferior aspect of the distal shaft was fully fixed to simulate a worst-case scenario of no ankle motion to limit variability in the model. A displacement-controlled stepped loading protocol was applied to the superior aspect of the proximal shaft (maximum displacement, 4 mm).

**Model comparison with single-rod uniplanar construct.**

A 3D solid model of a commonly used configuration, known as a single-rod uniplanar (SR) construct, was developed for comparison with the triangular multiplanar designs. Placement of the pins followed a technique outlined in the AO Principles of Fracture Management.<sup>4</sup> A 5-mm stainless steel pin was placed into each main fragment at the proximal and distal ends, exactly 125 mm from the osteotomy site. The two pins were connected by a single carbon fiber rod using the metal rod-to-pin connectors. An additional pin was placed on the proximal and distal fragments, 20 mm from the osteotomy site, parallel with the first pins, and subsequently connected to the rod with rod-to-pin connectors. Outcome measures from the finite element model were construct stiffness determined from load and displacement data and vertical interfragmentary displacement.



**Figure 1.** (Top) Axial view of triangular constructs, showing angulation of second and third pins at 0°, 22.5°, 45°, and 90°. (Bottom, Left) Anteroposterior view of constructs, showing inner or outer rod-to-pin clamp placement. (Bottom, Right) Medial-lateral view, showing intrafragment pin spacing at 100 mm or 75 mm.

**Table 1.** Full factorial design of experiments to observe the combined effects of varying outer pin (first and fourth) rod-to-pin coupler placement, pin spacing within fragments, and inner pin (second and fourth) axial angulation<sup>a,b</sup>

Rod-to-pin placement	Pin spacing – fragment, mm	Axial angulation, degrees			
		0	22.5	45	90
In	75	1	2	3	4
	100	5	6	7	8
Out	75	9	10	11	12
	100	13	14	15	16

<sup>a</sup> Sixteen treatments were available for analysis.

<sup>b</sup> Results of this experiment were used to select an ideal configuration for experimental testing of the triangular external fixation frame design.

<sup>c</sup> Interfragmentary spacing (10 mm), distance between frame and shaft (20 mm), and distance between innermost pins (50 mm) was kept constant.

*Experimental Testing (Aim 2)*

We experimentally compared the selected triangular configuration to two commonly used external fixator constructs—SR uniplanar and PC uniplanar—in a synthetic bone model. A power analysis was completed utilizing 5 N/mm as the clinically significant difference in stiffness, on the basis of results from preliminary testing of six triangular configurations using wood as the simulated bone material. A minimum sample size of 3 specimens per treatment group was adequate to detect this difference ( $\alpha = 0.05$  and  $\beta = 0.20$ ). Nine synthetic, fourth-generation composite tibiae (Pacific Research Laboratories, Vashon, WA) were used to compare each of the three constructs using a custom-designed test fixture.

**External fixation construct assembly.** All half-pins were inserted with an anteromedial to posterolateral trajectory, with the starting point just medial to the tibial crest, by a trained orthopaedic surgeon. A 10-mm osteotomy was created mid-shaft. A jig to guide reproducible placement of half-pins and cutting of the osteotomy was created by casting of the synthetic tibia.

The SR uniplanar construct placement follows the method in the previous section. For the PC uniplanar construct, two pins were placed in each main fragment similar to the SR uniplanar method. The proximal shaft pins were connected by a 10-hole pin clamp at the most proximal and distal clamp holes. The distal-shaft pins were connected in the same manner. We placed 30° aluminum angled posts in the two distal holes of the proximal clamp and in the two proximal holes of the distal clamp. The proximal- and distal-angled posts were connected by single

carbon fiber rods using aluminum rod-to-rod connectors.

For the optimized triangular fixation, a 5-mm stainless steel pin was placed into each main fragment at the proximal and distal metaphyses, at 125 mm from the osteotomy site. An additional pin was placed on the proximal and distal fragments, at 25 mm from the osteotomy site, with an axial angle of  $22.5^\circ$  from the first pins. Aim I computational models produced a range of values that would be acceptable for this technique (as described in Results section). The minimum angle of  $22.5^\circ$  was chosen for the experimental portion of this study because it produced the most compact structure with minimal potential for impingement of soft tissue. The most proximal and distal pins were connected by a single carbon fiber rod using the aluminum rod-to-pin connectors. The proximal and distal pins in the proximal fragment were connected by a short carbon fiber rod using aluminum rod-to-pin connectors. The same technique was used to connect the two pins in the distal fragment. A final rod-to-rod connector connected the proximal and distal short carbon fiber rods near the fracture site. SR uniplanar, PC uniplanar, and triangular two-planar constructs are shown in Figure 2.

**Testing protocol.** A custom-designed fixture was developed for experimental testing. A Mini-Bionix servohydraulic actuation system (MTS Systems, Eden Prairie, MN) was used to apply external loads simulating a single-leg stance loading condition. To accurately recreate an anatomical loading condition created by the settling and accommodation of the joints around a loaded tibia, we avoided rigid fixation of either the proximal or distal ends of the tested tibiae.<sup>13</sup> Instead, this physiological

accommodation was simulated by using a total knee arthroplasty component proximally and a universal joint distally.

The femoral component of a total knee prosthesis was attached to the actuator of the testing machine. The tibial component of the total knee prosthesis was attached to the proximal tibia using a spacer box and acrylic casting material, allowing articulation of the tibial and femoral total knee components. An automotive driveshaft universal joint was used to simulate the ankle and subtalar joints distally (Figure 2). A displacement-control protocol ramped at 1 mm/s (maximum displacement, 4 mm) was used to compare the compressive load at 4 mm and axial construct stiffness as measures of relative construct stability. Stiffness was defined as the slope of the most linear region of the load-displacement curve. A preload of 50mN was used for all tests.

### Statistical Analysis

Main effects and interactions of rod-to-pin coupler placement, pin spacing, and axial angulation from computational modeling of triangular constructs were analyzed using Minitab 16 (Minitab, State College, PA). Experimental data from all specimens were tabulated, and statistical analysis was performed in conjunction with biostatisticians. Ultimate load and stiffness between fixation constructs were compared using a one-way analysis of variance (ANOVA), with use of the Fisher least significant difference method to investigate relationships between subgroups.



**Figure 2.** External fixation constructs tested in experimental study (aim 2). (Left) Single-rod uniplanar. (Middle) Pin-clamp uniplanar. (Right) Triangular two-planar. A total-knee prosthesis was used to simulate tibial-femoral articulation. A universal joint was used to simulate the ankle and subtalar joints distally.



## Results

### Triangular Multiplanar Construct Selection

Sixteen possible model configurations were analyzed using simulated axial loads; results are listed in Table 2. The most significant factor affecting construct stiffness was pin spacing, with greater pin spacing resulting in increased construct stiffness (100-mm spacing = 126.0 N/mm [SD, 5.6 N/mm]; 75-mm spacing = 99.5 N/mm [SD, 9.6 N/mm];  $P < 0.001$ ). No significant difference in stiffness was found between constructs with inner or outer rod-to-pin coupler placement. When comparing the effects of axial angulation, stiffness was significantly higher in 22.5° and 45° than 0° constructs ( $P = 0.03$  and  $P = 0.01$ , respectively). Main effects and interaction plots for stiffness are shown in Figure 3.

**Table 2.** Results of the 16 possible model configurations analyzed using finite element modeling

Treatment	Factors included <sup>a</sup>	Vertical interfragmentary displacement, mm <sup>b</sup>	Stiffness, N/mm <sup>c</sup>
5	0°;out;100mm	2.9	124.0
13	0°;in;100mm	2.9	123.1
1	0°;out;75mm	2.5	87.5
9	0°;in;75mm	2.7	94.2
6	22.5°;out;100mm	2.4	126.4
14	22.5°;in;100mm	2.4	128.8
2	22.5°;out;75mm	2.2	96.7
10	22.5°;in;75mm	2.3	98.0
7	45°;out;100mm	2.2	129.6
15	45°;in;100mm	2.3	130.7
3	45°;out;75mm	2.2	98.4
11	45°;in;75mm	2.1	98.5
8	90°;out;100mm	2.1	131.3
16	90°;in;100mm	2.5	114.3
4	90°;out;75mm	2.1	100.7
12	90°;in;75mm	2.1	122.0

<sup>a</sup> “Out” and “in” refer to rod-to-pin clamp placement in relation to osteotomy site.

<sup>b</sup> Axial angulation and pin spacing had the most significant effects on interfragmentary displacement. In-line pins (0°) resulted in increased interfragmentary displacement.

<sup>c</sup> The most significant factor affecting construct stiffness was intrafragmentary pin spacing with greater pin spacing resulting in increased construct stiffness.

Axial angulation and pin spacing had the most significant effects on interfragmentary displacement. Displacement was significantly less in constructs with 75-mm pin spacing ( $P = 0.01$ ). Displacement was significantly less in 22.5°, 45°, and 90° than 0° constructs ( $P = 0.01$  for all). Displacement was also significantly less in 45° than 22.5° constructs ( $P = 0.02$ ). No significant difference in displacement was found between constructs with inner or outer rod-to-pin coupler placement. Main effects and interaction plots for interfragmentary displacement are shown in Figure 4.

### Model Comparison with Single-Rod Uniplanar Construct

The SR uniplanar computational model stiffness was 84.4 N/mm and the interfragmentary displacement was 2.6 mm. The SR uniplanar construct had a displacement in the range of the triangular multiplanar design (range, 2.1-2.9 mm). The stiffness of all configurations of the triangular construct exceeded that of the SR uniplanar design (87.5-131.3 N/mm). Figure 5 shows finite element displacement contour plots for the SR uniplanar and the 22.5° triangular uniplanar construct.

### Experimental Results

Results from the computational analyses showed that the 22.5° and 45° constructs, with 100-mm pin spacing and inner or outer rod-to-pin clamp placement, met optimal requirements for clinical use of an external fixation device—high stiffness and controlled interfragmentary displacement. The 22.5° configuration with 100-mm pin spacing and outer clamp placement was selected for the experimental study because high construct stiffness is important in early bone healing.<sup>6,14,15</sup> Additionally, this configuration involves the most compact design next to the single plane constructs.

In experimental tests, the 22.5° triangular multiplanar constructs (65.3 N/mm [SD, 5.0 N/mm]) were significantly stiffer than SR uniplanar (37.3 N/mm [SD, 1.6 N/mm]) and PC uniplanar (26.1 N/mm [SD, 1.6 N/mm]) constructs ( $P < 0.001$ ). Compressive load to achieve 4-mm displacement was significantly higher for triangular multiplanar constructs (271.8 N [SD, 19.4 N]) than SR uniplanar (155.4 N [SD, 6.9 N]) and PC uniplanar (109.4 N [SD, 6.4 N]) constructs ( $P < 0.001$ ).

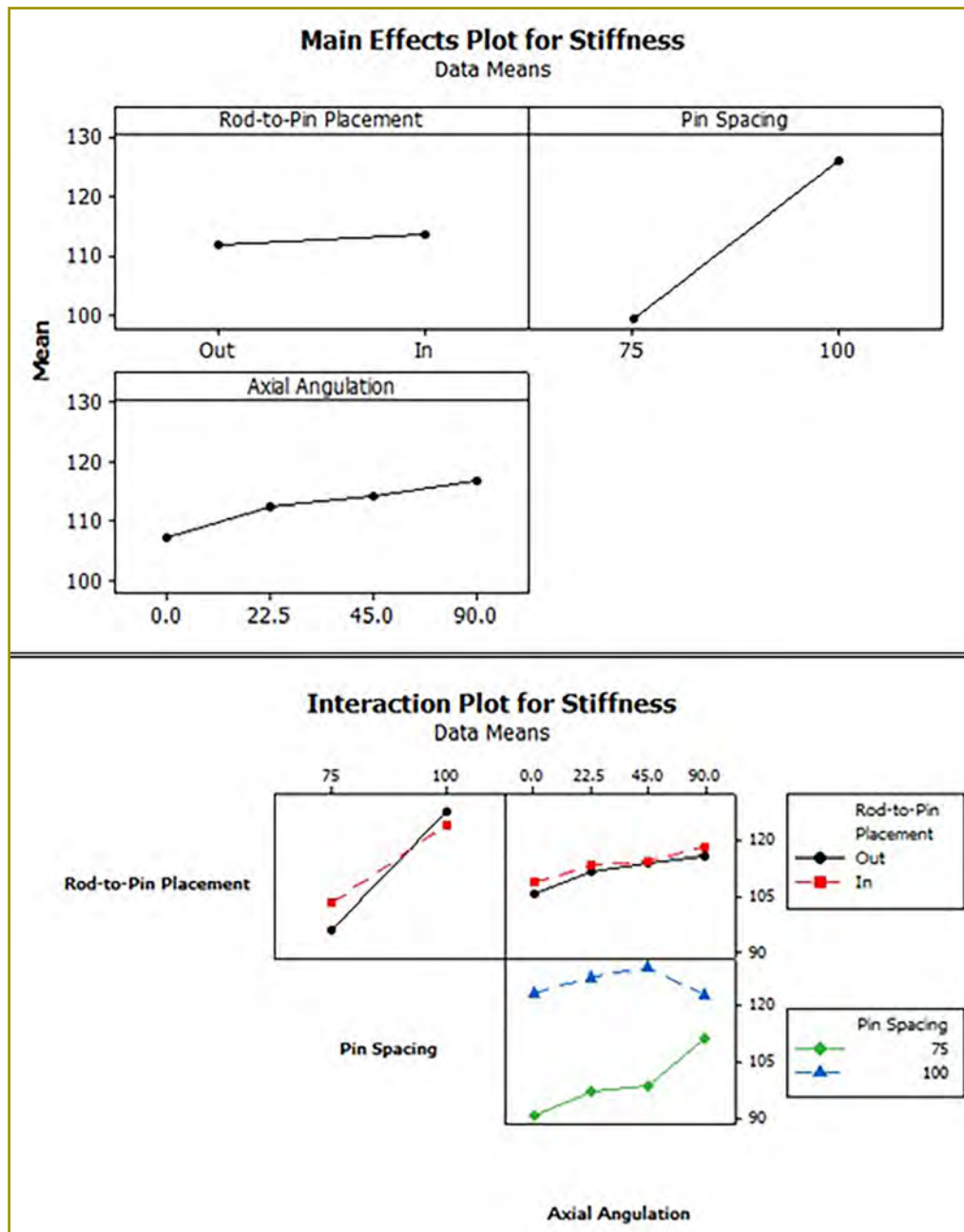


Figure 3. Mean effects (Top) and interactions (Bottom) plots for stiffness. Input variables are rod-to-pin placement, pin spacing, and axial angulation. Pin spacing was the most significant factor affecting stiffness. Greater pin spacing resulted in increased construct stiffness.

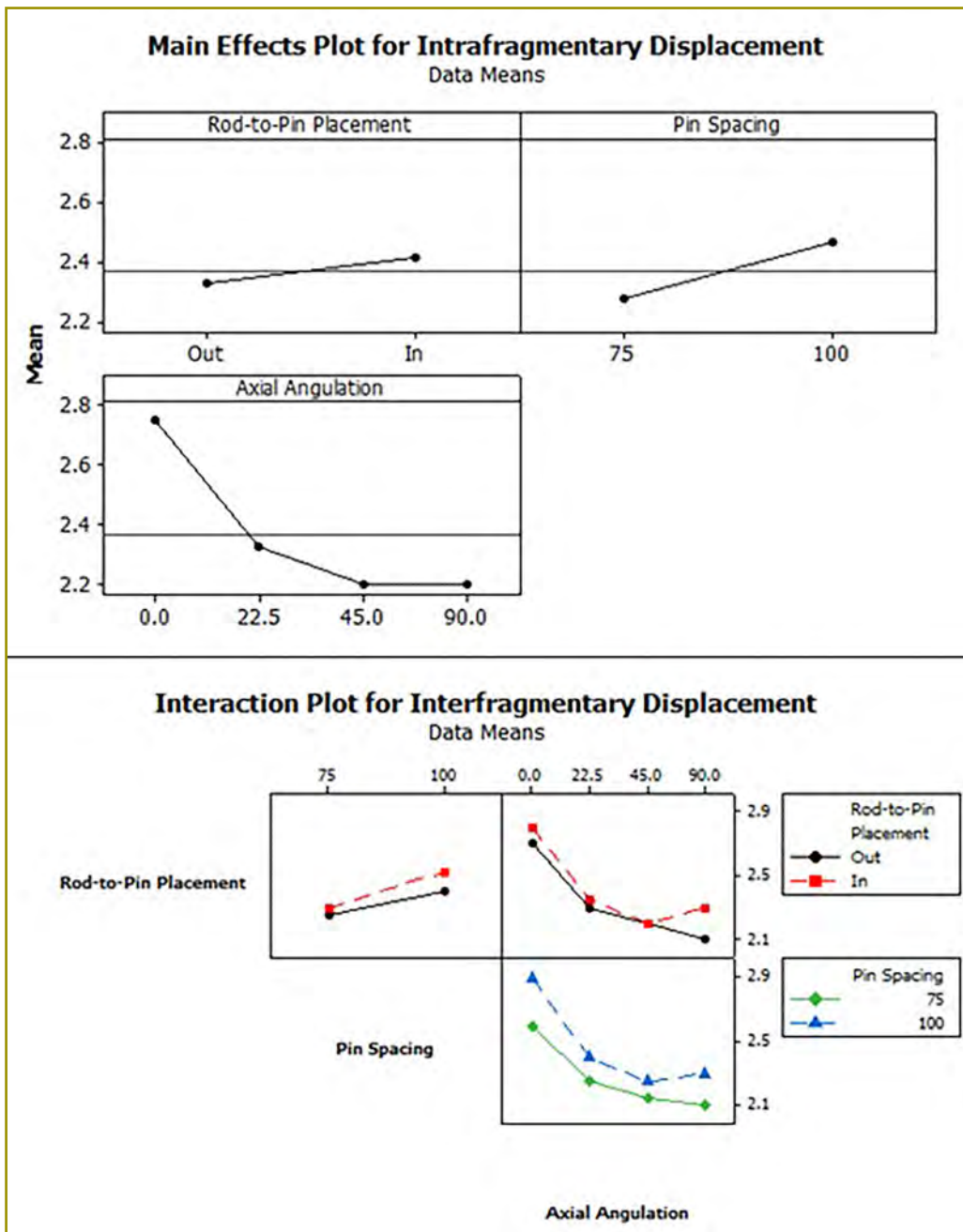
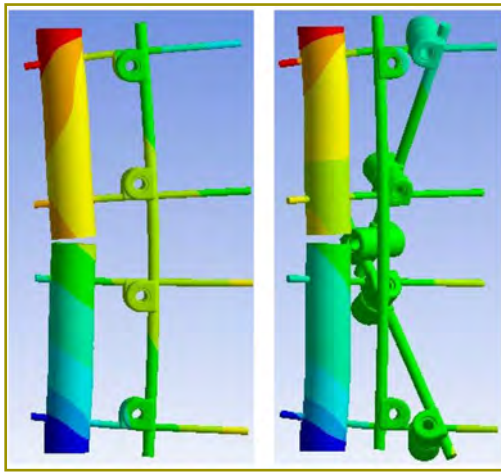


Figure 4. Main effects (Top) and interactions (Bottom) plots for interfragmentary displacement. Axial angulation and pin spacing had the most significant effects on displacement. Displacement is significantly less in constructs with 75 mm pin spacing and angulations of 22.5°, 45°, and 90°.



**Figure 5.** Displacement contour plots of single-rod uniplanar (Left) and 22.5° triangular multiplanar (Right) constructs from finite element modeling. Under the same applied conditions, the single-rod uniplanar has greater interfragmentary motion.

## Discussion

In aim 1, we analyzed 16 computational models of external fixation configurations developed to utilize the inherent benefits of the mechanical-engineering truss principle. The configurations were created using basic principles outlined by the AO foundation for increasing the structural stability of an external fixation device.<sup>4</sup> The principle of increasing the distance between pins within a fragment was used for model validation. Greater intrafragmentary pin spacing ( $P < 0.001$ ) and 22.5° or 45° inner pin axial angulation ( $P = 0.03$  and  $P = 0.01$ , respectively) significantly increased the structural stiffness of the constructs.

Our finding supports the pin-spacing principle affirmed by the AO Foundation and others, stating that increased pin spacing within a fragment increases stiffness of the construct.<sup>4,16</sup> Our results confirm that our testing method was sufficiently sensitive to detect a clinically important change in construct stability. Additionally, we found that interfragmentary displacement was significantly reduced with closer intrafragmentary pin spacing ( $P = 0.01$ ) and further reduced with 45° than 22.5° constructs ( $P = 0.02$ ).

In the current study, the 22.5° construct (with 100-mm intrafragmentary spacing and outer rod-to-pin clamp placement) was used for experimental comparison with the SR and PC uniplanar constructs because it maintained a high stiffness and was compact similar to the SR uniplanar fixation. We found 22.5° multiplanar constructs to be significantly stiffer and had significantly higher ultimate loads at 4-mm displacement compared with that of SR and PC uniplanar constructs ( $P < 0.001$ ).

The triangular two-plane construct presented in this study combines advantages of SR and PC frame designs

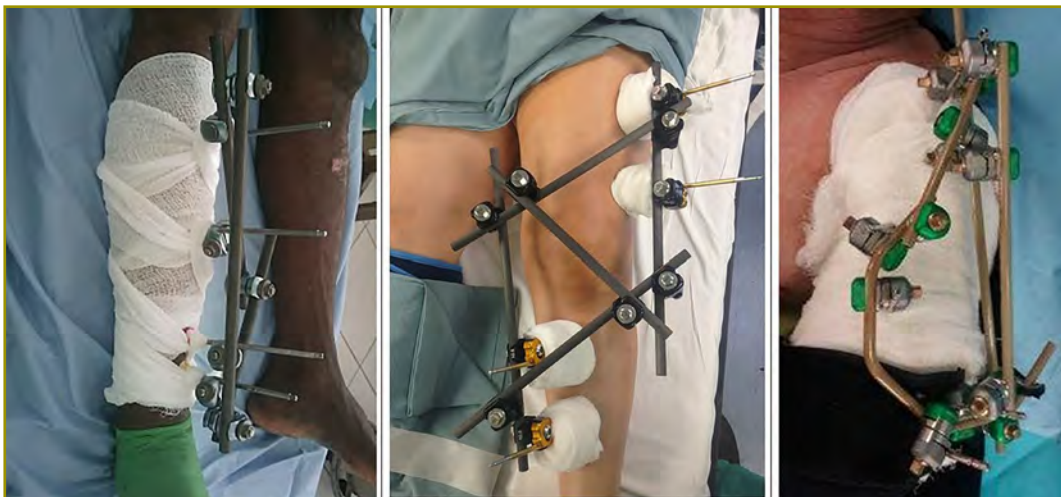
while avoiding their negatives. A main advantage includes high initial construct stiffness, with capability to easily increase or decrease stiffness by addition, removal, or adjustability of components even after the construct is fully built.<sup>6</sup> These characteristics are summarized in Table 3. A triangular external fixation configuration was proposed early by Fernández<sup>17</sup> to increase the torsional stiffness of a bilateral fixator. In his study, the triangular fixator was more than three times stiffer in torsion than unilateral, uniplanar constructs. Notably, the triangular construct was unilateral and biplanar, which would not transfix the lateral compartment. The triangular truss principle has been applied clinically at our institution for temporary and definitive treatment of tibial and humeral fractures. This technique has been employed when commonly used external fixation options have failed. Figure 6 outlines examples of the triangular principle applied in practice.

Limitations exist in the current study. Variables in the computational model were limited to three factors available to surgeons during placement (axial pin angulation, pin spacing, and clamp). Use of a multivariate probabilistic analysis may help determine definitively whether pin spacing or axial angulation (other than the points measured) affected the results, given the wide spectrum and variability from constraints of individual patient and injury characteristics. In the experimental study, the use of synthetic specimens is a limitation. Use of fourth-generation composite tibias eliminated variability attributed to bone quality in cadaveric specimens, which greatly reduced the number of specimens needed to achieve significance but did not allow us to examine how variations in bone quality may be affected by each construct type. Additionally, we compared the triangular construct to two commonly used uniplanar designs. To fully test its performance for clinical use, it would be necessary to compare this construct to commonly used hybrid and circular-ring fixators. However, in an acute trauma and temporizing application, hybrid and ring fixators are rarely used. With a biomechanical study, we can only theorize clinically relevant advantages of the triangular fixator. A controlled clinical study would allow comparison of surgical time for placement, need for guides for precise placement of half-pins, and ease of implementation.

In the current study, use of a two-plane triangular external fixation frame yielded a construct more structurally stable than the two symmetric SR and PC uniplanar comparison constructs, while also being more adjustable than single-rod constructs. The proposed two-plane triangular external fixation does not require the specialized devices necessary for PC constructs and allows simplicity and freedom of pin placement that can be helpful in settings where external fixators are important.

Table 3. Advantages and disadvantages of the triangular two-planar, single-rod uniplanar, and pin-clamp uniplanar constructs <sup>a</sup>							
Advantage (+)	Construct			Disadvantage (-)	Construct		
	Single-Rod	Pin-Clamp	Triangular		Single-rod	Pin-clamp	Triangular
Uses simple, readily available components	+		+	Loading causes bending deformation and asymmetric stimulation of cortical new bone formation	-	-	
High initial construct stiffness			+	Initial pin placement determines many aspects of final reduction	-		
Easily increase or decrease stiffness by addition or removal of components	+		+	Difficult to add pins for additional stability when used as definitive/long-term treatment		-	
Adjustable in all degrees of freedom (angular, length, rotation) even after construct fully built		+	+	Loss of stiffness with purposeful build-down as healing progresses		-	
Compact and low-profile	+		+	Constrained by placement of pins			
Forgiving pin placement/ pins may be placed with focus on safe-zones			+	Limited by rod trajectory	-		
				Limited by pin-clamp design/length		-	

<sup>a</sup> The triangular two-plane construct combines advantages of single-rod and pin-clamp frame designs while avoiding their negatives.



**Figure 6.** Clinical application of principles verified in this study. (Left) Triangular tibial external fixator investigated in this study. (Middle) Knee-spanning external fixator, showing safe femoral and tibial pin-placement. (Right) Humerus-shaft external fixator, successfully used in definitive treatment after pullout failure of a pin-clamp construct in this patient with fused shoulders.

## Funding

Supplies for this research were directly funded through a competitive educational grant from the Southwest Orthopaedic Trauma Association (SWOTA).

## Conflict of Interest

The authors report no conflicts of interest.

## Acknowledgements

Special thanks to Dr. Clifford Qualls for assistance with statistical analyses. We thank the Clinical and Translational Science Center for providing biostatistics consultation services (NIH CTSC grant #1UL1RR031977-01).

## References

1. Carroll EA, Komar LA. External fixation and temporary stabilization of femoral and tibial trauma. *J Surg Orthop Adv* 2011;20(1):74-81.
2. Manring MM, Hawk A, Calhoun JH, Andersen RC. Treatment of war wounds: a historical review. *Clin Orthop Relat Res* 2009;467(8):2168-91. doi: 10.1007/s11999-009-0738-5.
3. Fragomen AT, Rozbruch SR. The mechanics of external fixation. *HSS J* 2007;3(1):13-29. doi: 10.1007/s11420-006-9025-0.
4. Ruedi TP, Murphy WM. *AO Principles of Fracture Management*. New York, New York: Thieme Publishing Group; 2000.
5. Jagodzinski M, Krettek C. Effect of mechanical stability on fracture healing--an update. *Injury* 2007;38(suppl 1):S3-S10.
6. Claes L, Blakytyn R, Besse J, Bausewein C, Ignatius A, Willie B. Late dynamization by reduced fixation stiffness enhances fracture healing in a rat femoral osteotomy model. *J Orthop Trauma* 2011;25(3):169-74. doi: 10.1097/BOT.0b013e3181e3d994.
7. Chao EY, Aro HT, Lewallen DG, Kelly PJ. The effect of rigidity on fracture healing in external fixation. *Clin Orthop Relat Res* 1989;(241):24-35.
8. Burgers PT, Van Riel MP, Vogels LM, Stam R, Patka P, Van Lieshout EM. Rigidity of unilateral external fixators--a biomechanical study. *Injury* 2011;42(12):1449-54. doi: 10.1016/j.injury.2011.05.024.
9. Ledet, EH. Biomechanical factors in external fixation and hybrid external fixation [white paper]. *Stryker Trauma* 2004:LSA48.
10. Wu JJ, Shyr HS, Chao EY, Kelly PJ. Comparison of osteotomy healing under external fixation devices with

different stiffness characteristics. *J Bone Joint Surg Am* 1984;66(8):1258-64.

11. Dougherty PJ, Silverton C, Yeni Y, Tashman S, Weir R. Conversion from temporary external fixation to definitive fixation: shaft fractures. *J Am Acad Orthop Surg* 2006;14(spec no. 10):S124-S127.
12. Giotakis N, Narayan B. Stability with unilateral external fixation in the tibia. *Strategies Trauma Limb Reconstr* 2007;2(1):13-20. doi: 10.1007/s11751-007-0011-y.
13. Hoegel FW, Hoffmann S, Weninger P, Bühren V, Augat P. Biomechanical comparison of locked plate osteosynthesis, reamed and unreamed nailing in conventional interlocking technique, and unreamed angle stable nailing in distal tibia fractures. *J Trauma Acute Care Surg* 2012;73(4):933-8. doi: 10.1097/TA.0b013e318251683f.
14. Lewallen DG, Chao EY, Kasman RA, Kelly PJ. Comparison of the effects of compression plates and external fixators on early bone-healing. *J Bone Joint Surg Am* 1984;66(7):1084-91.
15. Williams EA, Rand JA, An KN, Chao EY, Kelly PJ. The early healing of tibial osteotomies stabilized by one-plane or two-plane external fixation. *J Bone Joint Surg Am* 1987;69(3):355-65.
16. Briggs BT, Chao EY. The mechanical performance of the standard Hoffmann-Vidal external fixation apparatus. *J Bone Joint Surg Am* 1982;64(4):566-73.
17. Fernández AA. External fixation of the leg using unilateral biplanar frames. *Arch Orthop Trauma Surg* 1985;104(3):182-6.

# Evaluation of Content and Accessibility of Orthopaedic Trauma Fellowship Websites

Travis M. Hughes, BS<sup>\*a</sup>; Bobby Dezfuli, MD<sup>†b</sup>; Kimberly J. Franke, MD<sup>†</sup>;  
Jordan L. Smith MD<sup>†</sup>; John T. Ruth, MD<sup>†</sup>

<sup>\*</sup>College of Medicine, University of Arizona Medical Center, Tucson, Arizona

<sup>†</sup>Department of Orthopaedic Surgery, University of Arizona Medical Center, Tucson, Arizona

## Changed Affiliations

<sup>a</sup>T. M. Hughes, MD. Department of Orthopaedics & Rehabilitation, The University of New Mexico Health Sciences Center, Albuquerque, New Mexico

<sup>b</sup>Woodland Hills Medical Center – Kaiser Permanente, Woodland Hills, California

## Abstract

**Background:** Residents frequently use the internet to find material on fellowship programs. The Orthopaedic Trauma Association (OTA) website serves as a central hub for information on an orthopaedic trauma fellowship (OTF). This study aims to evaluate the accessibility, content, and perceived importance of OTF websites.

**Methods:** We reviewed the 49 OTFs accredited by the OTA fellowship database as of January 2014. We searched for corresponding OTF websites by using the provided OTA hyperlinks and conducting a separate Google search of program location and institution. Links to websites of general orthopaedic programs were not counted. Content of OTF websites was analyzed by noting the presence or absence of specific items in fellow education (11 items) and recruitment (5 items).

**Results:** Of 49 OTFs, a total of 39 (80%) websites specific to the fellowship were identified by searching the OTA database and Google browser. Seven (14%) programs listed on the OTA database provided links directly to fellowship programs. Most programs (28; 57%) did not provide links to specific OTFs or provided non-functional links on the OTA website. Of the 39 accessible OTF websites, a total of 24 (61%) had complete information regarding recruitment and 14 (36%) provided complete details on education.

**Conclusions:** Most accredited OTFs do not adequately use the internet to provide easily accessible and complete information. Further details (especially regarding the role, education, and schedule) would help prospective candidates in thoroughly evaluating programs. The discrepancy in content and accessibility can hinder prospective fellows from appropriately investigating fellowship programs.

## Introduction

The Orthopaedic Trauma Association (OTA) website<sup>1</sup> serves as the central hub for information about the orthopaedic trauma fellowship (OTF). As of January 2014, the database listed a total of 49 programs supported by the Accreditation Council for Graduate Medical Education (ACGME) and other OTA-accredited organizations. The OTA website offers detailed information about each OTF, including contact information and links to program websites.

Most research that evaluates the websites of graduate medical programs and online program resources is specific to residency programs. Nevertheless, the similarities in match process and program overlap allow these studies to be generalized. In 1999, Winters and Hendey<sup>2</sup> surveyed 60 emergency medicine residents and showed that 82% had visited the program website before submitting their application. More recently, results of a 2011 study by Chu et al<sup>3</sup> showed that 98% of 210 anesthesia residents routinely visited residency program websites during the application process. Participants indicated the quality and content of the websites directly affected decisions about application submission.

Several studies have explored residency program websites and their effect on the match process across various fields of medicine.<sup>2-8</sup> However, to our knowledge, the only investigation on orthopaedic surgery fellowships was conducted by Mulcahey et al<sup>9</sup> in 2013. This study evaluated the content and accessibility of websites for fellowship programs in sports medicine accredited by the American Orthopaedic Society for Sports Medicine (AOSSM). The study concluded that the fellowship program websites did not provide adequate links to

fellowship pages, and some fellowship programs lacked functional websites altogether. In comparing the data to similar studies, the researchers concluded that AOSSM fellowship programs were underusing the web as a resource for programs.<sup>3,5,8,9</sup>

Mulcahey et al<sup>9</sup> also evaluated fellowship program websites for specific content items related to fellow education and recruitment. In a similar study, Mahler et al<sup>7</sup> found that geographic location was the only factor reported to be more important to applicants than an easily navigable and complete residency program website. Accessibility to application information was as influential to residency program related decisions as input from fellow students and mentors. Kumar et al<sup>5</sup> came to similar conclusions regarding pediatric residency program websites, in that programs with higher match rates tended to have more user-friendly websites. Ease of navigation was highly regarded across studies, whereas site aesthetics were not found to be significantly regarded in any of the studies evaluated.<sup>4,5,9</sup>

We aimed to evaluate OTA-accredited program websites for content and accessibility in a similar manner to that of Mulcahey et al.<sup>9</sup> Our goal was to expand on their results and additionally evaluate the perceived importance of fellowship program websites by distributing a survey to fellowship program coordinators. The objectives of this study were (1) to evaluate the links to fellowship program websites as listed on the OTA website; (2) review the content on the fellowship program websites; (3) assess results of surveys to determine any perceived importance of the internet as a communication tool for fellowship programs; and (4) compare our data with that of previous research to relate two different orthopaedic fellowships.

## Methods

The OTA website is easily navigable. The homepage provides the “Fellowship Match & Resources” tab, serving as the main database. The fellowship directory and information were accessed in February 2014, though the date of the most recent update was not provided. The 49 OTFs listed had individual pages of contact and descriptive information. The data gathered included website links, contact information of program coordinators or directors, and university affiliation information.

The fellowship programs were evaluated for accessibility by using three methods: a direct website search, a Google search of the program name, and another Google search of the institution. The websites were initially located with the links provided on the OTA website. Additionally, a Google search was conducted using keyword phrases of “{program name} + Orthopaedic Trauma Fellowship” and, if

necessary, “{associated institution} + Orthopaedic Trauma Fellowship.” The websites linked directly from the OTA database were divided into three categories: fellowship information, general orthopaedic program information, or non-functional links. For the Google searches, the first 30 results (three pages) were analyzed individually, with a similar evaluation as done with those listed on the OTA website. Search results that linked to general program websites (without any reference to the trauma fellowship) were not counted. The searches using associated institutions were conducted if no fellowship information was obtainable by the previous two. No unique websites were found using these methods; thus, websites were analyzed for content only. Google searches were conducted on January 25, 2014.

Fellowship program websites were evaluated for content in several areas established as important to residency applicants.<sup>2,7,8</sup> The criteria used were adapted from those described by Mulcahey et al,<sup>9</sup> which evaluate program websites based on two categories: fellow education and recruitment. To maximize objectivity, the presence or absence of content items was noted and no evaluation of quality or validity of information was done. The presence of the following items was independently evaluated for each website: didactic instruction, journal club, research requirements, rotation schedule, call responsibilities, team coverage, outpatient and clinic, research listing, common case descriptions, links to major orthopaedic societies, and the role of the fellows. Information pertaining to these items was considered present if any mention of the items was noted on the fellowship program website or linked pages. Information more likely to be directed toward fellow recruitment was analyzed by the same method. The items evaluated in this category included description of program, application information such as links and information referring to San Francisco (SF) Match,<sup>10</sup> salary, current or former fellows, and current faculty members.

Using contact information provided by the OTA website and searchable links if necessary, we contacted the fellowship program coordinators or directors to determine the perceived importance of the website as a recruitment tool. Initially, all program coordinators listed on the OTA website were emailed a brief survey. Some email addresses were non-functional. These programs were contacted by phone twice throughout the week of April 31, 2014, once in the morning and once in the afternoon. The questions asked were as follows: (1) What is the best way for fellow applicants to obtain information about your program? (2) Does your program maintain a fellowship program website? (3) How often is your program website updated? (4) How important is the website as a recruiting priority on a scale of 1-10 (10 being very important)?



## Results

The OTA provided a central database that contained links for 28 of the 49 programs (57%). The remaining 21 programs did not provide links. Of these 28 programs with links, a total of seven (25%), fourteen (50%), and seven (25%), respectively, linked directly to fellowship websites, orthopaedic program websites, and non-functional websites (Figure 1).

Results of a Google search for the 49 listed OTFs located 37 (76%) programs. Of these searchable programs, a total of 29 (78%) were the first result listed, with the remaining eight sites in the top 10 (first page) of results. Two of the fellowship websites could only be located through extensive navigation in the program website, with no mention of the fellowship on the first 30 Google results (first three pages). These websites were considered unsearchable. Of the 28 programs with functional links on the OTA directory, a total of 18 websites (64%) could be located within the first 10 results of a Google search (Figure 2).

The 39 fellowship program websites found from the OTA database and using Google searches were analyzed for content in two categories: fellow education and recruitment. Of the 11 education content items analyzed, the websites contained on average 6.4 items (median, 6). Almost all websites provided common case descriptions (95%), information on research requirements (90%), and discussed the role of fellows in the program (87%; Figure 3). Although the large majority (90%) discussed the program research requirements, only 18 programs (46%) listed current or past research and 10 programs (26%) mentioned journal club meetings. Didactic instruction was referenced by 22 (56%) of the websites. Most fellowship program websites discussed the role of outpatient clinic (69%), whereas less than half mentioned a rotation schedule (46%), team coverage (44%), or call

responsibilities (33%). Seventeen programs (44%) provided links to important orthopaedic societies, such as the OTA or AAOS.

Websites were also evaluated for content specific to fellow recruitment (Figure 4). The websites were searched for 5 related items, with an average of 3.7 items (median, 4) found. All 39 of the fellowship program websites provided a description of the program. Thirty-five programs (90%) listed information about current faculty members, and 20 (54%) listed current or former fellows. Of the recruitment items, fellow salary was found on the fewest number of websites (51%). Application information, including links to the OTA or SF Match, was present on 30 websites (77%).

All 49 programs were contacted for participation in this study. Sixteen program coordinators (33%) responded to the emailed questionnaire or were reached by phone. When asked about the best way for applicants to obtain further information, a total of eight (50%) directed applicants to a specific website, whereas the other 50% directed applicants to online resources provided by the governing bodies of the match. Five fellowship program coordinators (31%) referred potential applicants to the OTA website for further information. Three coordinators (19%) referred applicants to the SF Match website for further information. Coordinators with functional websites were asked how often the fellowship program website was updated. Seven (44%) were updated on an annual basis and three (19%) were updated several times or on a rolling basis. The rest of the respondents either did not have websites or did not know the frequency of updates. Coordinators were also asked to rate the importance of their program website as a recruiting priority for their program, with use of a scale of 1 to 10. The average response between all respondents was 8.5 (median, 8; range, 7-10).

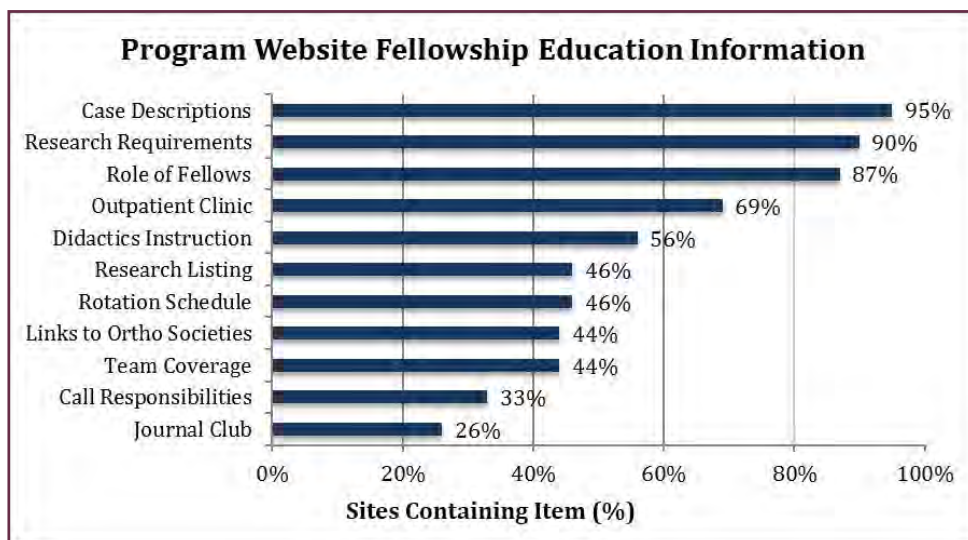


Figure 1. Flowchart detailing the accessibility of fellowship program websites from links listed on the Orthopaedic Trauma Association website.

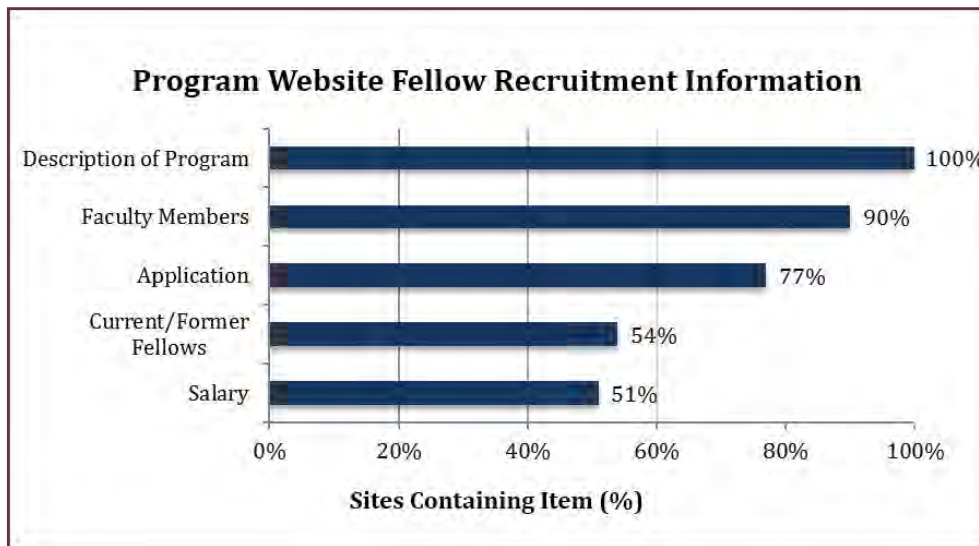


Figure 2. Flowchart detailing accessibility of fellowship program websites that were identified using the Google search engine.

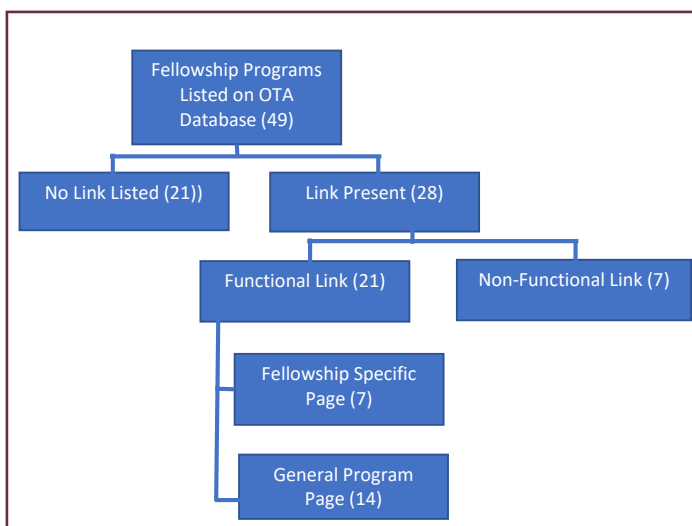


Figure 3. Percentage of fellowship program websites containing fellow education specific content items (n = 39).

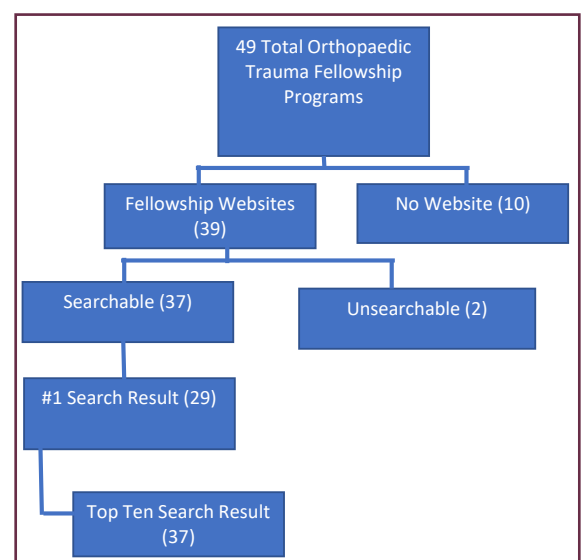


Figure 4. Percentage of fellowship program websites containing fellow recruitment specific content items (n = 39).

## Discussion

Prospective applicants for accredited OTFs need to be able to easily find accurate and up-to-date information about fellowship programs of interest. The OTA website serves as the central database that is home to a directory listing information for the 49 accredited fellowship programs, which is easily accessible without any login or credentialing information. In the current study, both the SF Match website<sup>10</sup> and most fellowship program coordinators directed individuals seeking further information to this central database.

Results of our study found that the OTA database provided functional links to websites of 43% of the accredited programs. Of these functional links, one-third linked to fellowship material. A Google search for

the same information provided fellowship information for 76% of the programs listed on the OTA website. All websites were found within the first page of search results (top 10), and 78% of the searchable websites were the first result listed. This may indicate that many more fellowship program websites exist that are not linked on what is considered to be the most complete source of information regarding the OTF match. Although surprising, this lack of easily obtainable updated information does not seem to be an isolated problem. Numerous studies have shown deficiencies in residency program websites.<sup>6-8</sup> Results of a more recent study showed that the AOSSM website, which serves as the central database for the sports medicine fellowship match, only contained functional links for 44% of accredited programs.<sup>9</sup>

Results of previous studies<sup>2-4,8,9</sup> have indicated that websites for graduate medical education programs are becoming increasingly important tools both for recruitment by programs and information gathering by applicants. Applicants competing for coveted positions are disadvantaged by lack of information.<sup>10</sup> The competitive nature of the match and individuality of each program speaks to the need for easily obtainable and accurate information about the fellowship program.<sup>1,10</sup>

In addition to being able to locate a specific program website, recent studies have explored the importance of more specific details about quality and content of residency program websites, which are similar in use to fellowship program websites.<sup>4,5,7,9</sup> Our study showed that although all fellowship program websites analyzed provided program descriptions, few provided adequate information regarding schedule and curriculum. Besides program description, current faculty information was present on the highest number of websites (90%). It has been reported that a current faculty listing is overall unimportant to prospective residents,<sup>4</sup> although faculty caliber may be more important to fellow applicants. Less than half of fellowship program websites mentioned the rotation schedule (46%), and fewer noted call responsibilities or team coverage. Overall, fellowship program websites were more likely to list information related to recruitment than fellow education, which was consistent with previous research of AOSSM fellowship programs, although this could be owing to the information (ie, faculty listing and application information) being more readily available and consistent over time.

It is possible that those in charge of fellowship programs do not find it necessary to maintain up-to-date information for potential applicants, or that the limited information present on the OTA website is deemed sufficient. The average reported level of importance was 8.5 on a 10-point scale, with no coordinator scoring the importance less than a seven. Furthermore, most respondents (82%) directed those looking for further information about their program to the OTA or fellowship program website. When asked how often their sites were updated, most coordinators estimated yearly, whereas one respondent answered “not often enough.” Based on our data, this perceived importance of the internet, OTA website, and fellowship program websites as adequate resources for fellowship applicants seems incompatible.

There are limitations to the current study. The OTA website was accessed in a month, and the Google searches were performed on a single day. The information or search results obtained may have changed during this time; however, the reported yearly updates for most websites suggests a limited significant effect on results. Additionally, only one search engine was used, which could

affect the variety of results obtained. The items were also only analyzed in terms of presence or absence, without any analysis of quality or detail. Improving on previous research and further validating concerns by Mulcahey et al,<sup>9</sup> we analyzed the top 30 results and found no additional benefit compared to limiting the study to the top 10. Additionally, since initial data was collected, three more trauma fellowships have been accredited, and those are not included in the current study.

Results of the current study showed that the OTA website provides direct links to fellowship information for 14% of accredited programs. As other possible sources of fellowship program details, SF Match and program coordinators mainly defer to the OTA for such information. Fellowship information could be easily obtained for more than 80% of programs using web searches. This would indicate that such information regarding programs and links exist but are not present in an easily accessible central database.

Our study also showed that many accessible fellowship program websites did not provide much information regarding the trauma fellowship, and even fewer provided the information most relevant to applicants. Future studies would benefit from elucidating information most vital to the decision making of fellowship applicants. This information could be used to provide a standard form or template that the programs could either provide on their own websites or that could be reflected on the OTA database. Improvement of accessibility and content of individual fellowship program websites and the OTA database is already viewed as a priority by program coordinators.

Inherent challenges and costs exist associated with maintaining an updated central database that requires information from institutions around the country. However, with the ease of access and communication, it seems feasible and overall beneficial to maintain an information portal. It is a worthwhile endeavor to streamline the application process for potential fellows and more adequately and efficiently dispense vital information to those dependent on such details.

## Funding

The authors received no financial support for the research, authorship, and publication of this article.

## Conflict of Interest

The authors report no conflicts of interest.

## References

1. Orthopaedic Trauma Association. Fellowship Match and Resources. <http://ota.org/fellowship/fellowship-match-and-resources/>. Updated 2016. Accessed March 2014.
2. Winters RC, Hendey GW. Do web sites catch residency applicants? *Acad Emerg Med* 1999;6(9):968-72.
3. Chu LF, Young CA, Zamora AK, et al. Self-reported information needs of anesthesia residency applicants and analysis of applicant-related web sites resources at 131 United States training programs. *Anesth Analg* 2011;112(2):430-9. doi:10.1213/ANE.0b013e3182027a94.
4. Gaeta TJ, Birkhahn RH, Lamont D, Banga N, Bove JJ. Aspects of residency programs' web sites important to student applicants. *Acad Emerg Med* 2005;12(1):89-92.
5. Kumar A, Sigal Y, Wilson E. Web sites and pediatric residency training programs in the United States. *Clin Pediatr (Phila)*. 2008;47(1):21-4.
6. Kutikov A, Morgan TM, Resnick MJ. The impact of residency match information disseminated by a third-party website. *J Surg Educ* 2009;66(4):212-5. doi: 10.1016/j.jsurg.2009.03.034.
7. Mahler SA, Wagner MJ, Church A, Sokolosky M, Cline DM. Importance of residency program web sites to emergency medicine applicants. *J Emerg Med* 2009;36(1):83-8. doi: 10.1016/j.jemermed.2007.10.055.
8. Reilly EF, Leibrandt TJ, Zonno AJ, Simpson MC, Morris JB. General surgery residency program websites: usefulness and usability for resident applicants. *Curr Surg* 2004;61(2):236-40.
9. Mulcahey MK, Gosselin MM, Fadale PD. Evaluation of the content and accessibility of web sites for accredited orthopaedic sports medicine fellowships. *J Bone Joint Surg Am* 2013;95(12):e85. doi:10.2106/JBJS.L.00785.
10. SF Match Residency and Fellowship Matching Services. SF Match website. Updated 2016. <https://www.sfmatch.org/>. Accessed March 2014.

# Suturing Workshop for Third-Year Medical Students: A Modern Educational Approach

Mary E. Logue, BS\*; Ryan D. Lurtsema, BS\*; Yuridia Leyva, BS\*; Tyler J. Hough, BS\*; Kelly M. Harrington, BS\*; Deana M. Mercer, MD<sup>†</sup>

\*School of Medicine, The University of New Mexico Health Sciences Center, Albuquerque, New Mexico

<sup>†</sup>Department of Orthopaedics & Rehabilitation, The University of New Mexico Health Sciences Center, Albuquerque, New Mexico

## Abstract

*Background:* This study sought to determine if developing suturing workshops based on modern educational theory would lead to a significant increase in third-year medical students' confidence and preparedness as compared to before the workshop.

*Methods:* A group of pre-clinical, third-year medical students (n = 20) were voluntarily recruited. The workshop consisted of an interactive didactic session, a hands-on suturing session, and a question-answer session with surgeons. The nine-point Likert scale surveys were given pre- and post-workshop to 17 participants. Total scores of "confidence" and "preparedness" were analyzed using the Student t-test. Results of Q-Q plot and normality tests were used to validate the normality assumption. All analysis was conducted using SAS Software 9.4 (Cary, North Carolina).

*Results:* A statistically significant increase in both confidence and preparedness was found between results of pre- and post-workshop surveys. Average total scores in confidence increased by 19.7 points, from 19.3 to 39 (95% CI: 15.0-24.4; *P* value < 0.001). For scores in preparedness, the total score increased by an average of 18.4 points, from 22.8 to 41.2 (95% CI: 14.1-22.8; *P* value < 0.001).

*Conclusions:* These findings suggest that a structured course based on modern educational theory can increase both the confidence and preparedness of third-year medical students who are matriculating into their hospital-based clerkships.

## Introduction

Suturing is an important practical skill that allows physicians to close skin incisions and lacerations to facilitate optimal wound healing. Skilled suturing approximates the skin edges, minimizes the dead space, and allows the wound to heal by primary intention with minimal scarring.<sup>1</sup>

There is no national standardized curriculum for suturing, thus it is taught variably between medical schools. The most common method utilizes the "see one, do one, teach one" format, also known as the "master-apprentice" system. This method generally includes student observation of a more highly trained individual, then personal attempt performing the skill, and finally peer education. This commonly used method, though helpful in certain settings, has some limitations. There are financial, time, and ethical constraints for students to learn new skills on patients especially without standardization.<sup>2</sup> Studies have shown that simulation improves student suturing skills.<sup>3</sup> Furthermore, it has been shown that a variety of simulation materials can successfully approximate the look and feel of human skin; pig skin has been deemed the optimal tissue substitute.<sup>3,4</sup> While appropriate simulation is an important part of medical training, it alone may not sufficiently address the integration of knowledge, dexterity, and adeptness.

Successful student suturing requires knowledge of choosing the correct instrument and knowing how to hold it, choosing the optimal suture, and proper handling of skin flaps.<sup>5</sup> Furthermore, understanding the choice of closure (ie, interrupted simple stitch versus running subcuticular stitch) requires a solid baseline knowledge of wound healing.<sup>5</sup> Additional baseline knowledge should include: wound classification, types of suture materials, and modes of wound healing.<sup>6</sup> Given the time constraints of the "master-apprentice system", there often is not time for this baseline knowledge to be imparted in a way that promotes retention by the medical student. With that said, it is rarely expected medical students have mastered these skills. This study focuses on the potential benefit of an educational, theory-based suturing workshop to create more confidence and preparedness among participants.

Medical student suturing sessions at The University of New Mexico School of Medicine currently consist of incoming third-year medical students receiving a brief

demonstration from a senior medical student followed by a block of time where the student can practice on synthetic skin. This process is sometimes overseen by a resident or attending who can answer individual questions. There is otherwise no formal suturing for students to learn or practice leaving a gap in baseline knowledge among students entering third year rotations. Studies have shown that this model is likely not the most effective way to teach suturing skills in a way that fosters confidence and retention for medical students.<sup>7</sup>

A pilot study by Thomas<sup>6</sup> found that integration of Robert Gagne's Nine Events of Instruction into suturing workshops led to an improved quality of education. We sought to expand upon this study by further assessing the effects of this approach in two unique domains: confidence and preparedness.

## Methods

Approval from our Human Research Review Committee was obtained for this study (HRRC #16-093). A power analysis for a two-sided comparison of means between matched pairs was conducted, and a target sample size of 16 participants was established. Study participants were recruited based on enrollment status: The University of New Mexico School of Medicine third-year medical students entering their first hospital-based clerkships. The first 20 individuals to respond to the recruitment email, which included HRRC-approved consent information, were subsequently enrolled in the workshop. Five of the 20 enrolled students did not attend, and two members of the "wait list" were subsequently contacted and invited to attend. Our HRRC approved verbal consenting given by students for study participation with the return of surveys.

The framework for the workshop was based on Gagne's Nine Events of Instruction. To start, students were given a pre-workshop nine-point Likert scale survey assessing their current levels of confidence and preparedness with suturing, ranging from "absolutely disagree" to "absolutely agree." Students were then given a brief, formal presentation on various aspects of suturing: types of wounds, reasoning for suturing, types of instruments/suture, and various techniques often employed in suturing. This presentation opened with attention-grabbing pictures demonstrating the adverse effects of poor suture technique, provided students with the objectives for the day, engaged students in a question-answer (Q&A) session that would stimulate their preexisting knowledge, and ultimately taught the material in an engaging manner that elicited student participation and provided pictures and videos related to suturing. After this formal presentation, students were led to a separate room where workstations were set up

(four students per station, each with their own instruments, suture, and pig skin). Students worked independently on the previously taught suturing techniques while an instructional video played on repeat at each station. During this time, three fourth-year medical students, two surgical residents, and one surgical attending physician walked amongst the students to offer feedback and instruction. Finally, the workshop ended with a Q&A panel and the post-workshop survey, which was identical to the pre-workshop survey.

Analysis was conducted on 17 participants who served as their own controls in this paired-study design; this included 15 of the initial 20 recruits, plus two recruits from the study's wait list. The power analysis performed at the 5% significance level suggested a total sample size of 16 participants, producing a power of 80% for a medium-large effect size of 0.65. For pre- and post-workshop surveys, total scores were constructed for each student based on responses to the survey questions for each of two domains regarding suturing: preparedness and confidence. The nine-point Likert scale survey responses ranged between "absolutely disagree" and "absolutely agree," contributing between one and nine points per question to the total score. Total scores for each domain therefore had a possible range between five and 54 points per domain. To determine if the mean differences between the pre- and post-workshop surveys were statistically significant, paired Student t-tests were performed for each domain ( $\alpha = 0.05$ ). A Q-Q plot of difference was used to validate the normality assumption of the data. Statistical analysis was completed using SAS Software 9.4 (Cary, North Carolina).

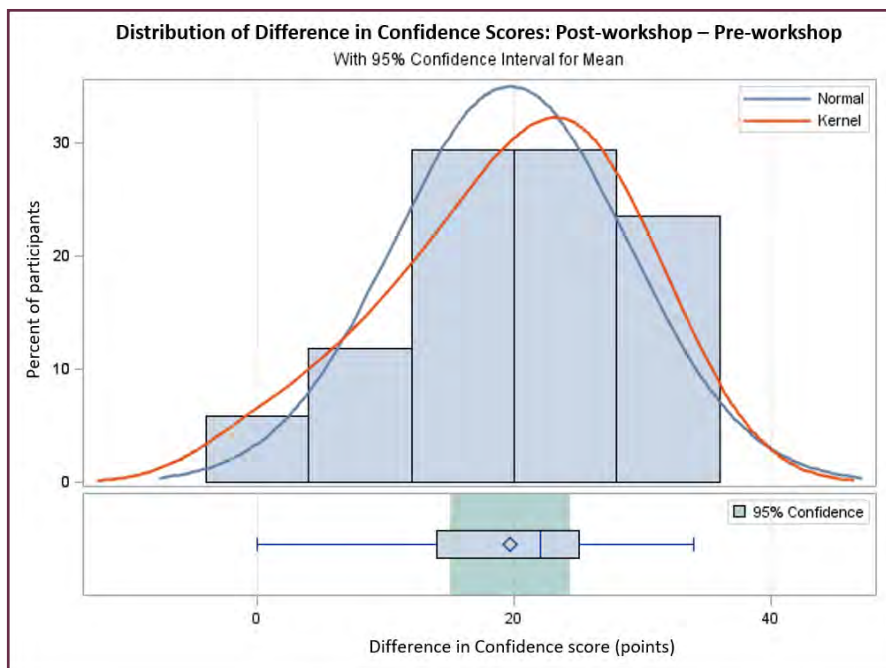
## Results

For the confidence domain, pre-workshop surveys' mean total score was 19.3, compared to a post-workshop mean total score of 39. For the preparedness domain, pre-workshop surveys' mean total score was 22.8, compared to a post-workshop mean total score of 41.2, as shown in Table 1. Students reported feeling significantly more "confident" with successful suturing after the workshop compared to before. On average, students' total scores increased by 19.7 points (95% CI: 15.0–24.4;  $P$  value <0.001) between pre- and post-workshop surveys (Figures 1 and 2). Students reported feeling significantly more "preparedness" with successful suturing after the workshop compared to before. On average, students' total scores increased by 18.4 points (95% CI: 14.1–22.8;  $P$  value <0.001) between pre- and post-workshop surveys (Figures 3 and 4).

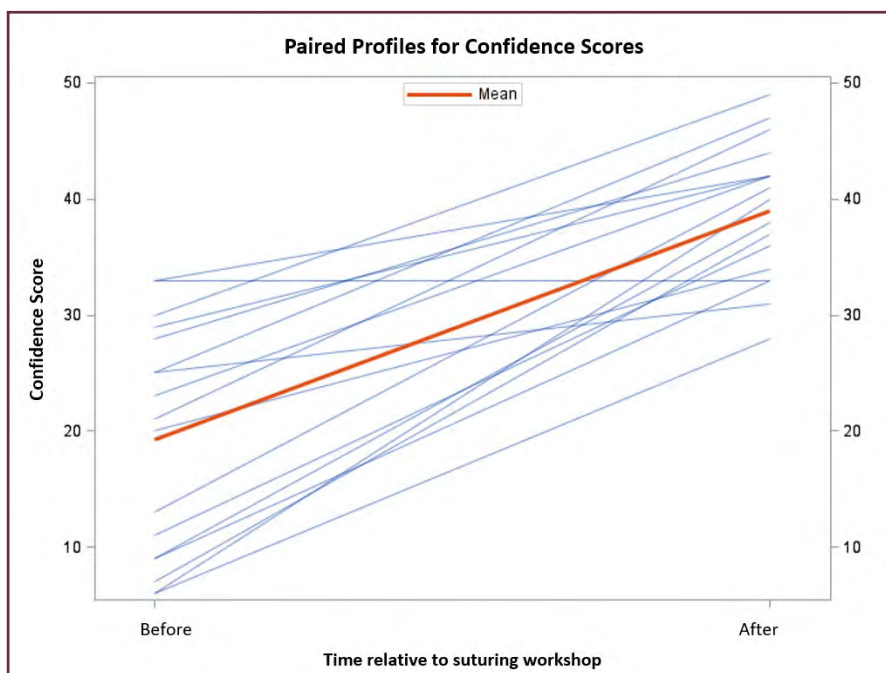**Table 1.** Score results from Likert-scale surveys given to 17 participants before and after the workshop

Domain	Pre-workshop score (n = 54 points)	Post-workshop score (n = 54 points)	P value
Confidence			<0.001
Mean (SD)	19.3 (9.9)	39.0 (6.0)	
95% CI	14.2-24.4	35.9-42.1	
Preparedness			<0.001
Mean (SD)	22.8 (8.7)	41.2 (6.5)	
95% CI	18.3-27.3	37.8-44.5	

CI, confidence interval.



**Figure 1.** Normally distributed differences between pre-workshop and post-workshop confidence scores for participants (n = 17). Notably, the mean confidence score (denoted by diamond symbol in boxplot) increased by 19.7 points between pre- and post-workshop surveys (P value < 0.001) and almost all individual scores increased.



**Figure 2.** Paired profiles for confidence scores before and after suturing workshop for each participant (n = 17). Bold red line represents the sample mean confidence score before and after the suturing workshop. Notably, confidence scores increased after the workshop for all but one participant.

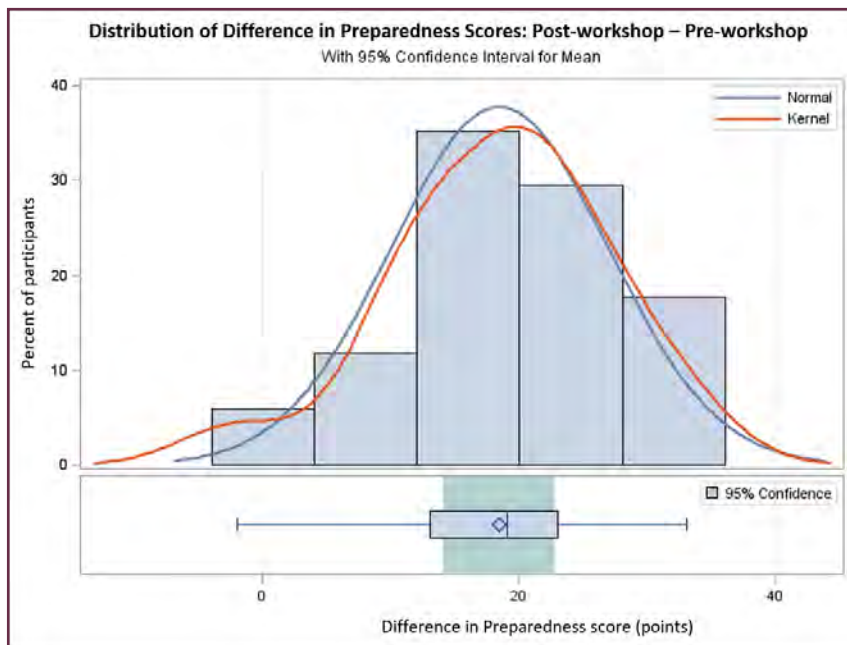


Figure 3. Normally distributed differences between pre-workshop and post-workshop preparedness scores for participants ( $n = 17$ ). Notably, mean preparedness score (denoted by diamond symbol in boxplot) increased by 18.4 points after the suturing workshop ( $P < 0.001$ ) and almost all individual preparedness scores increased.

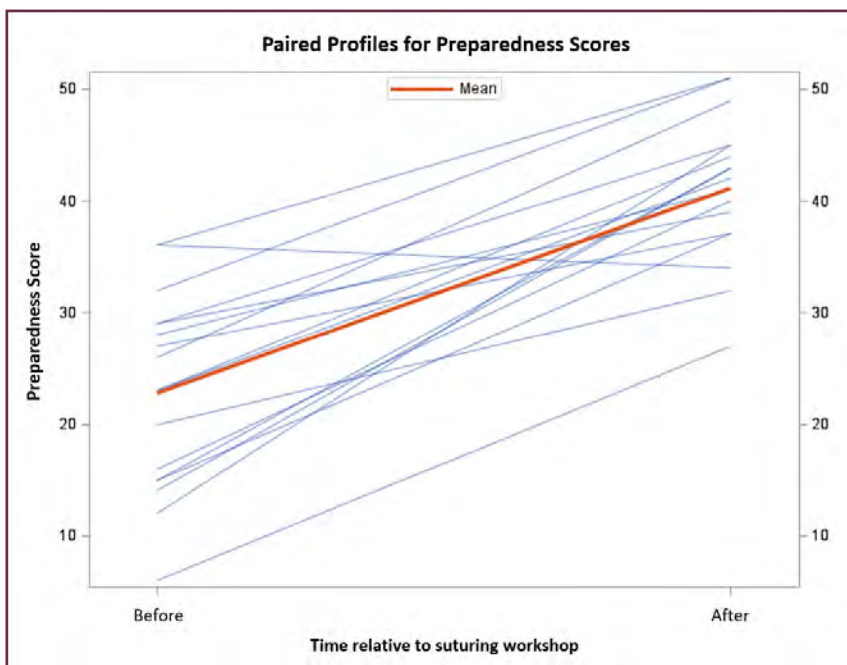


Figure 4. Paired profiles for preparedness scores before and after suturing workshop for each participant ( $n = 17$ ). The bold red line represents the sample mean confidence score before and after the suturing workshop. Notably, confidence scores increased after the suturing workshop for all but one student.

## Discussion

On the basis of our results, this study suggests that second-year students transitioning into third year may benefit from a suturing workshop incorporating modern educational theory. In both domains, confidence and preparedness, the cohort showed a significant increase in their abilities between the pre-workshop survey and the post-workshop survey. Our study cohort additionally demonstrated a slightly greater increase in confidence than preparedness, which may be attributable to our question categories defining confidence largely as a willingness to attempt the

skill in the hospital versus preparedness being defined as a current assessment of baseline knowledge and ability.

Of note, 16 of the 17 study participants showed individual increases in pre- to post-workshop confidence and preparedness. As we did not collect subjective, qualitative data, it is hard to interpret the results of the one student whose confidence score remained the same and preparedness score dropped from pre- to post-surveys and thus qualify this result as an outlier.

Finally, although our study is limited to 17 participants, they account for greater than 15% of the total class body, which provides a relatively generalizable number to work



with (particularly concerning the third-year medical student population at The University of New Mexico). However, we recognize that some selection bias may have resulted from sampling students using a recruitment email. It is possible that students with an anticipated specialty involving suturing (eg, surgery, emergency medicine, and obstetrics or gynecology) were more likely to participate in the workshop than students interested in different specialties that do not involve suturing, including allergy- and asthma-related specialties. We acknowledge that our study is limited to The University of New Mexico, and given the moderate variation of curriculums across institutions, these results may only carry weight at institutions with similar suturing curriculum deficits.

Overall, we believe the integration of modern educational theory into practical skill workshops, such as suturing, for transitioning medical students is an effective method for facilitating an effective and efficient learning environment for the retention of skills and knowledge related to suturing.

## Funding

The authors received no financial support for the research, authorship, and publication of this article.

## Conflict of Interest

The authors report no conflicts of interest.

## Acknowledgements

The authors would like to express their appreciation for The University of New Mexico Departments of Orthopaedics & Rehabilitation and Plastic Surgery; namely Drs. Deana Mercer, Dustin Larson, Tony Pedri, Christopher Demas, and Anil Shetty. We would also like to thank the UNM Orthopaedic Interest Group, Sahar Freedman, Julia Bowers (passed away), and Joy Van Meter for their assistance in coordinating the study's workshop.

## References

1. Khan MS, Bann SD, Darzi A, Butler PE. Assessing surgical skill. *Plast Reconstr Surg* 2003;112(7):1886-9.
2. DiMaggio PJ, Waer AL, Desmarais TJ, et al. The use of a lightly preserved cadaver and full thickness pig skin to teach technical skills on the surgery clerkship--a response to the economic pressures facing academic medicine today. *Am J Surg* 2010;200(1):162-6. doi: 10.1016/j.amjsurg.2009.07.039.
3. Tokuhara KG, Boldt DW, Yamamoto LG. Teaching suturing in a workshop setting: a comparison of several models. *Hawaii Med J* 2004;63(9):258-9.
4. Adams CC, Marquart JD, Nicholas LL, Sperling LC, Meyerle JH. Survey of medical student preference for simulation models for basic dermatologic surgery skills: simulation platforms in medical education. *Dermatol Surg* 2014;40(4):427-35. doi: 10.1111/dsu.12445.
5. Khan MS, Bann SD, Darzi A, Butler PE. Suturing: a lost art. *Ann R Coll Surg Engl* 2002;84(4):278-9.
6. Thomas I. Improving suturing workshops using modern educational theory. *Clin Teach* 2012;9(3):137-42. doi: 10.1111/j.1743-498X.2011.00526.x.
7. Bauer F, Rommel N, Kreutzer K, et al. A novel approach to teaching surgical skills to medical students using an ex vivo animal training model. *J Surg Educ* 2014;71(4):459-65. doi: 10.1016/j.jsurg.2014.01.017.

# Intradepartmental System of Allocating Operating Room Block Time and its Financial Impact at The University of New Mexico Department of Orthopaedics & Rehabilitation: A Preliminary Report

Dustin L. Richter, MD\*; Gail Case\*; Nicholas White\*; Mary A. Jacintha<sup>†</sup>; Robert C. Schenck Jr, MD\*

\*Department of Orthopaedics & Rehabilitation, The University of New Mexico Health Sciences Center, Albuquerque, New Mexico

<sup>†</sup>Health System, The University of New Mexico Health Sciences Center, Albuquerque, New Mexico

## Abstract

*Background:* Within a hospital, the operating room (OR) is one of the most critical and expensive resources. Labor productivity is maximized by filling allocated surgical block time with as many hours of cases as possible. We have found that the intradepartmental block time release system at our institution has improved access to operating time, resulting in a substantial financial advantage within the department.

*Methods:* The annual charges and collections produced by the pick-up of intradepartmental released block time during the past 4 fiscal years (July 1-June 30) was assessed at both the main hospital and an outpatient surgical center.

*Results:* There is a general, year-over-year trend of increasing charges and collections from the intradepartmental release of OR time. The average gross collection rate for OR pick-up time is 30%, which matches the average collection rate of about 30% for our department. At the main inpatient hospital, the orthopaedic spine service typically comprises the most-released OR block time. In the outpatient setting, typically the orthopaedic hand service captures the most released OR block time.

*Conclusions:* The early release of allocated block time on an internal level may help schedule patients in an easier manner, with decreased patient wait times than other methods, and maintain the overall revenue within the department. Further studies that quantify surgeon satisfaction would help strengthen the use and validation of this system.

## Introduction

Healthcare systems are constantly being challenged to deliver high-quality care with limited resources. Within a hospital, the operating room (OR) is one of the most critical and expensive resources.<sup>1</sup> In addition to the cost of supplies, payroll expense (eg, nursing and anesthesia staff) accounts for most OR costs.<sup>2</sup> With increasing pressure to minimize the costs of caring for surgical patients, one successful strategy is to maximize labor productivity by employing the fewest full-time nurses and anesthesiologists necessary to adequately cover patients undergoing elective procedures. Personnel scheduling needs can be better anticipated when there is a definitively scheduled day of operative treatment. Alternatively, these scheduled days can be planned for days on which a full complement of OR personnel would be available.<sup>3,4</sup>

A common method to provide surgeons with access to sufficient OR time to complete their elective cases and match caseload with OR staffing is to allocate OR “block time.”<sup>5-7</sup> With block scheduling, OR time is assigned to a surgeon, surgical group, or surgical department for their exclusive use up to some designated time before the day of treatment (ie, 10 working days before the scheduled block day of the treatment). Labor productivity is maximized by filling the block time with as many hours of cases as possible. A key factor in filling block time is to forecast accurately how much block time to allocate to each surgeon or group of surgeons who share a block. The surgical group needs sufficient block time to complete elective cases. On the other hand, it is also important to avoid allocating too much time that ends up going unfilled,

leading to OR staff who are being paid with no cases to cover. These goals require accurate forecasts of each surgical group's needed time to complete respective elective cases.<sup>4</sup>

Often in surgical systems management, the problem is when and how to release allocated OR block time. One method is making the block time available to any surgical specialty (in any surgical department) within the organization, with an established deadline—that is, about 2 weeks before the operative procedure. This strategy may involve a release of surgical time if cases are not scheduled by the predetermined deadline; additionally, the method can include a release of surgical time if the surgeon is planning to be absent on professional leave or vacation.

In the current study, we examined a different method of allocating OR block time employed by our department: intradepartmental release of block time to be used by other colleagues of orthopaedic surgeons within our group. We aimed to determine whether the use of the intradepartmental strategy resulted in overall financial advantage within our department.

## Methods

We instituted the intradepartmental model in 2012. In our current model, surgeons are allocated block time for use in scheduling operative cases. However, there are many instances every month when the surgeons are either gone on professional leave, vacation, are clinically slow, or are providing coverage for our orthopaedic trauma room concept and thus unable to utilize their allocated OR block time. To optimize our departmental allotted block time

and minimize the potential effect of lost revenue from unutilized time, we initiated an internal, intradepartmental release of block time with associated data collection and administrative assistant responsibility. In this system, surgeons identify unusable OR block time immediately, and a central coordinator is emailed who makes the time available to other orthopaedic surgeons in the department who wish to schedule cases in the released block time.

## Results

The first complete year for financial evaluation of the systemic approach was fiscal year 2013 (July 1, 2012–June 30, 2013). The annual charges and collections produced by the pick-up of intradepartmental released block time during the past 4 fiscal years (July 1, 2012–June 30, 2016) is shown in Figure 1. The average gross collection rate for OR pick-up time was 30%, which matches the average collection rate of about 30% for all the department.

Figures 2A and 2B show the OR pick-up time charges and collections, respectively, by specialty for the most recent fiscal year 2016 (July 1, 2015–June 30, 2016). This breakdown also represents the percent of block time that was picked up by each specialty at both the main hospital and in the outpatient surgical unit. At the main inpatient hospital, the orthopaedic spine service typically accounts for the service that captures the most released OR block time. In the outpatient setting, typically the orthopaedic hand service captures the most released OR block time. Figure 3 illustrates these charges and collections by location (main hospital OR versus satellite clinic OR).

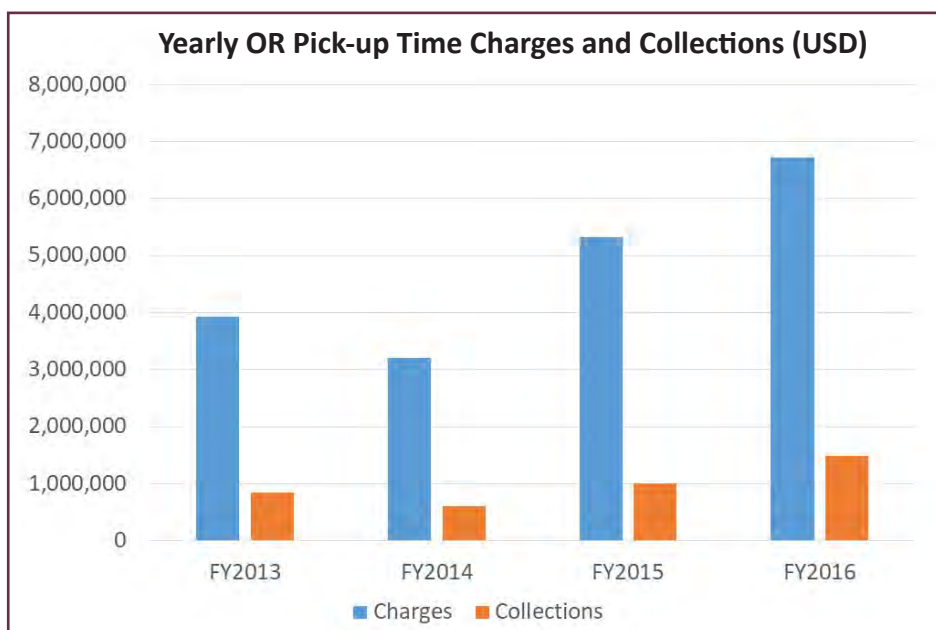


Figure 1. Charges and collections in USD, yielded from the pick-up of intradepartmental released operating room block time during the past 4 fiscal years (July 1, 2012 through June 30, 2016).

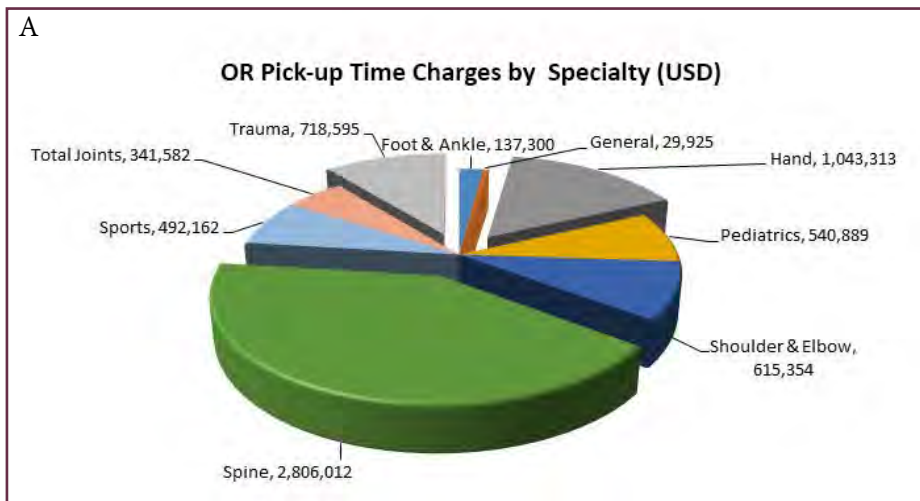


Figure 2. Charges (A) and collections (B) in USD, listed by orthopaedic specialty from the pick-up of released operating room block time for fiscal year 2016 (July 1, 2015 through June 30, 2016).

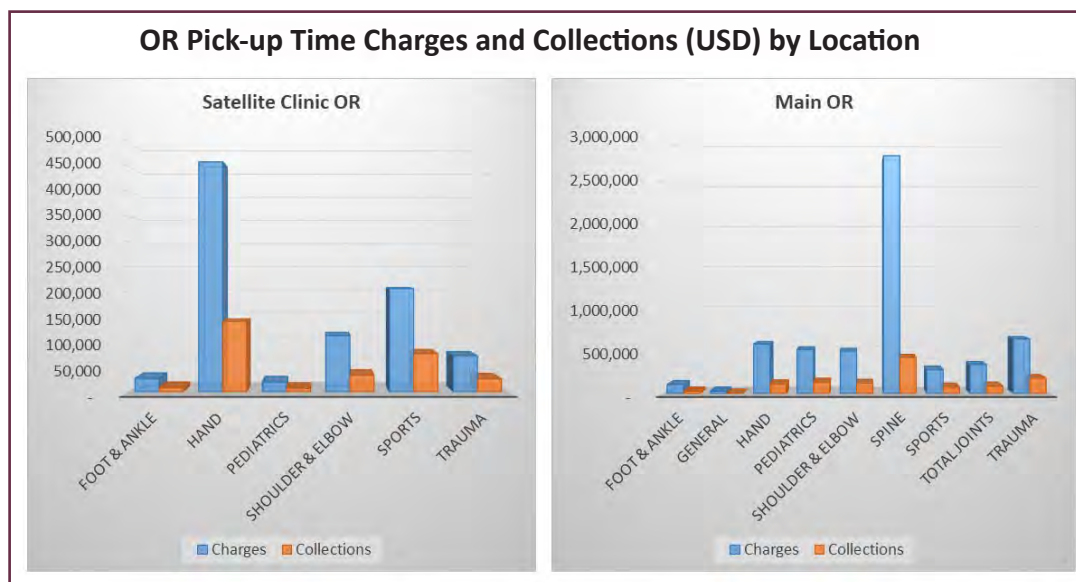
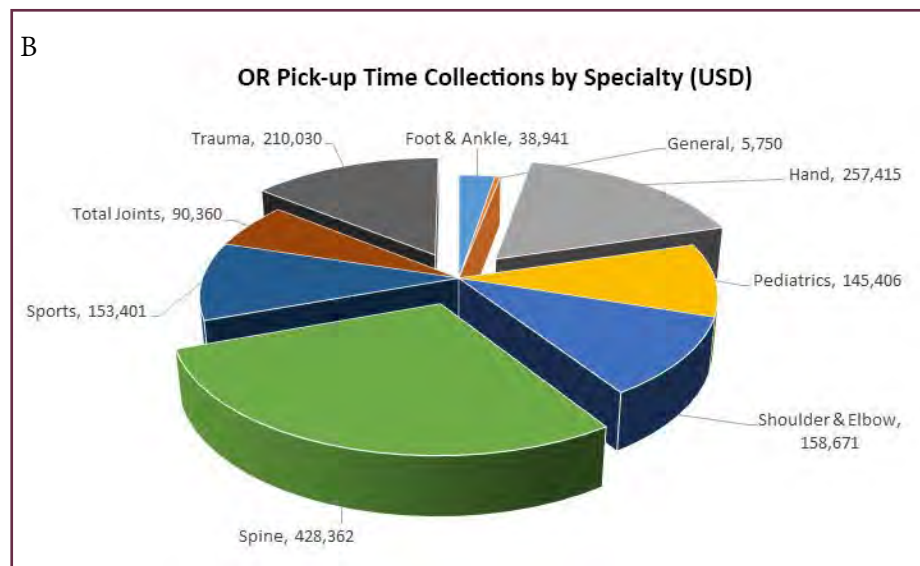


Figure 3. Charges and collections in USD listed by location (main hospital or satellite clinic) from the pick-up of released operating room block time for fiscal year 2016 (July 1, 2015 through June 30, 2016).

## Discussion

Surgical planning and scheduling can be complex tasks owing to multiple stakeholders with conflicting interests and limited resources. A survey on OR management in Switzerland showed that hospital management and employees are not satisfied with the current surgical scheduling practices; in fact, only 26% of the survey interviewees are somewhat happy with the scheduling systems.<sup>8</sup> In another study performed at the University of Iowa, the investigators surveyed patients on what was considered an acceptable time to wait for elective operative treatment. Half of the patients considered 2 weeks to be the longest acceptable wait time for elective operative treatment.<sup>9</sup> The OR manager must balance patients' desires not to wait for treatment versus the fact that OR utilization and collection rate will increase as waiting time increases.

Prior to implementation of our current model, the unused block time was viewed as lost revenue. By capturing intradepartmental released block time, this is an additional revenue stream seen as a distinct financial advantage for the department that was not previously accounted for. Since the use of the intradepartmental model, we have noticed a positive change in the department's charges and collections with the system. Our department's use of a new model of allocating block time by offering it internally has led to shorter wait times and better utilization. With a shorter lead time from scheduling to operative treatment, we also speculate that this translates into a positive clinical benefit for our patients, allowing them a quicker path to recovery and return to sport or work.

This study has several limitations. First, this report is not meant to be a detailed cost-analysis study. We have only shared our overall experience and general trends related to the intradepartmental release of block time and have not performed a detailed cost-analysis, comparing the revenue and expenses in the past 4 years to those before implementing the system. Second, although we hypothesize that a shorter patient waiting time for surgery positively affects the clinical results for some patients, this has not been directly assessed in this study. Owing to the multiple variables related to how, when, and where patients are scheduled for surgical treatment, an objective number for the actual days of shortened lead time is not available. Lastly, although a thorough extraction of the data and costs for the past 4 fiscal years was performed, it is possible that some released OR time was not accounted for or identified in this report.

Compared with similar systems, the departmental release of allocated block time can help busy orthopaedic surgeons with scheduling patients, create less waiting-time for patients, and keep the same revenue in the department.

## Funding

The authors received no financial support for the research, authorship, and publication of this article.

## Conflict of Interest

The authors report no conflicts of interest.

## References

1. Macario A, Vitez TS, Dunn B, McDonald T. Where are the costs in perioperative care? Analysis of hospital costs and charges for inpatient surgical care. *Anesthesiology* 1995;83(6):1138-44.
2. Dexter F, Macario A. Applications of information systems to operating room scheduling. *Anesthesiology* 1996;85(6):1232-4.
3. Dexter F, Macario A, Lubarsky DA, Burns DD. Statistical method to evaluate management strategies to decrease variability in operating room utilization: application of linear statistical modeling and Monte Carlo simulation to operating room management. *Anesthesiology* 1999;91(1):262-74.
4. Dexter F, Macario A, Qian F, Traub RD. Forecasting surgical groups' total hours of elective cases for allocation of block time: application of time series analysis to operating room management. *Anesthesiology* 1999;91(5):1501-8.
5. Geuder DL, Banschbach SK. Effective block scheduling strategies [published erratum in: *Best Pract Benchmarking Healthc* 1996;1(5):270]. *Best Pract Benchmarking Healthc* 1996;1(3):134-9.
6. Strum DP, Vargas LG, May JH, Bashein G. Surgical suite utilization and capacity planning: a minimal cost analysis model. *J Med Syst* 1997;21(5):309-22.
7. Strum DP, Vargas LG, May JH. Surgical subspecialty block utilization and capacity planning: a minimal cost analysis model. *Anesthesiology* 1999;90(4):1176-85.
8. Sieber TJ, Leibundgut DL. Operating room management and strategies in Switzerland: results of a survey. *Eur J Anaesthesiol* 2002;19(6):415-23.
9. Dexter F, Macario A, Traub RD, Hopwood M, Lubarsky DA. An operating room scheduling strategy to maximize the use of operating room block time: computer simulation of patient scheduling and survey of patients' preferences for surgical waiting time. *Anesth Analg* 1999;89(1):7-20.

# Understanding Radiocarpal Rotation Through In Vivo Pronation and Supination of the Hand: A Single Case Study

Jorge L. Orbay, MD<sup>\*</sup>; Joshua M. Romero, BS<sup>†</sup>; Neal Wostbrock, BS<sup>‡</sup>;  
Deana M. Mercer, MD<sup>§</sup>

<sup>\*</sup>The Miami Hand & Upper Extremity Institute, Miami, Florida

<sup>†</sup>School of Medicine, The University of New Mexico Health Sciences Center, Albuquerque, New Mexico

<sup>‡</sup>Department of Mechanical Engineering, The University of New Mexico, Albuquerque, New Mexico

<sup>§</sup>Department of Orthopaedics & Rehabilitation, The University of New Mexico Health Sciences Center, Albuquerque, New Mexico

## Abstract

*Background:* Studies have not clearly defined the motion of the distal radius in relation to the carpus in vivo. We hypothesized that 1) with the hand fixed by grasping a handle to prevent hand and wrist motion, the resulting load in torsion generated by extrinsic muscle in vivo would create motion at the radiocarpal joint; and 2) the motion measured will be between the distal radius and the proximal row of the carpus.

*Methods:* The data was acquired from the senior author external to our institution; in the current study, we quantify the resulting radiocarpal motion. A K-wire was placed into the second metacarpal, and a second wire was placed in the distal radius. The shoulder was abducted to 90° and the hand was pronated, held stationary gripping a fixed object. The forearm was pronated and supinated to simulate radiocarpal rotation. Photographs were obtained at three points: 1) initial position showing the wire in vertical alignment; 2) same perspective in maximum internal radiocarpal rotation; and 3) same perspective in maximum external radiocarpal rotation. ImageJ (open source) was used to quantify the angle between the wires.

*Results:* Superimposition of the three photographs in vivo allowed us to approximate two angle measurements. The measurements with maximal internal and external rotations were 16° and 24°, respectively.

*Conclusions:* Radiocarpal rotation should be considered in addition to flexion and extension motions and radial ulnar deviations when treating degenerative changes in the wrist.

## Introduction

The kinematics of the wrist were first studied in 1896 when MB Bryce used “New Photography” to understand the articulations within the wrist joint.<sup>1</sup> Numerous studies have since investigated the kinematics of the wrist.<sup>2-8</sup> Advancements in technology have also helped quantify wrist motion, and studies have described up to 24 distinct movements of the wrist.<sup>9</sup> Furthermore, findings of dynamic computed tomography (CT) scans have revealed variations in morphological features of the carpal bone, which can affect wrist kinematics.<sup>10</sup> Additionally, the mechanical axis of the wrist has shown to be oriented along the dart-thrower’s plane.<sup>9</sup> The wrist may be predisposed to a dart thrower’s motion owing to the orientation of the muscle insertions.<sup>11</sup> The principal orientation of the circumduction that envelopes at the wrist is along this dart-thrower’s-motion path,<sup>9,12</sup> and the thrower’s motion and circumduction may be associated with performance of functional tasks in healthy patients.<sup>13</sup>

New imaging techniques have increased understanding of the wrist joint. Findings of magnetic resonance imaging (MRI) and CT have shown 6°-of-freedom kinematics in the carpal bones,<sup>4,14-17</sup> and the use of 4D CT and MRI has helped study the dynamic motion of the carpus.<sup>18-21</sup> These imaging techniques have also assessed wrist injury and arthritis.<sup>22</sup> Despite the increasing research into wrist kinematics, more clarification is needed in describing movement of the wrist, particularly in the field of wrist arthroplasty implant design.

The purpose of our study was to further investigate the kinematics of the wrist by describing and quantifying radiocarpal rotation through in vivo experimental testing. Radiocarpal rotation considerably affects the kinematics



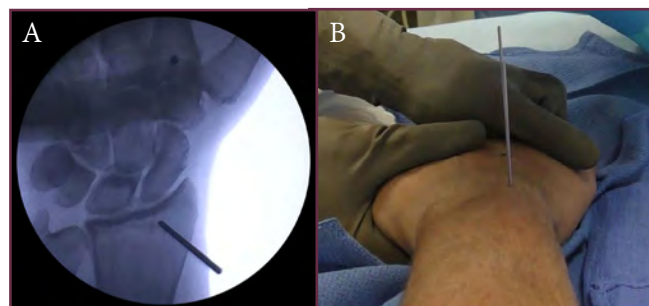
of the wrist during day-to-day activities. A better understanding of this movement can help improve the treatment, early detection, and prevention of degenerative changes in the wrist.

## Methods

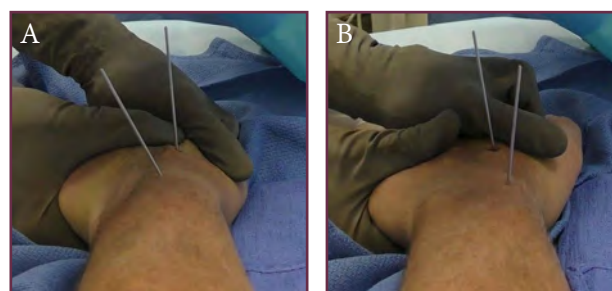
The current study was classified as “Non-Human Research” by our Human Research Review Committee (#16-108) because the data came into our acquisition after the study was completed external to our institution. We conducted the analysis to quantify that motion.

To quantify radiocarpal rotation about the long axis of the forearm, K-wires were placed into the wrist of the participant (senior author) who was under regional anesthetic. The first wire was placed into the second metacarpal, in a posterior-to-anterior direction, parallel to the long axis of the forearm. The second wire was placed into the distal radius, parallel to the metacarpal wire, with the hand in the pronated orientation and normal to the long axis of the forearm (Figure 1A). The participant laid in supine position on an operating table. His shoulder was abducted to 90°, and his hand was placed on a table beside the bed. The hand was pronated and held stationary, palm down, on the table by gripping a fixed object. The participant pronated and supinated his forearm to simulate radiocarpal rotation, with the hand in this fixed position. Attempted pronation was defined as internal radiocarpal rotation, whereas attempted supination was defined as external radiocarpal rotation.

Photographs were obtained at three points. The first point showed the wires in vertical alignment, proximal to distal, along the forearm (Figure 1B). The second point showed the same perspective but in maximum internal radiocarpal rotation (Figure 2A). The third point showed the same perspective but in maximum external radiocarpal rotation (Figure 2B). These photographs were overlaid using GIMP (GNU Image Manipulation Program, open source), with the base of the metacarpal wire defined as our reference point and Figure 1B defined as the initial wire position. ImageJ, an open-source image processing software, was used to quantify the angle between the wires, about the long axis of the forearm. The distance from the camera to each wire was held constant. The software was calibrated using the known diameter of the K-wire used for pinning.



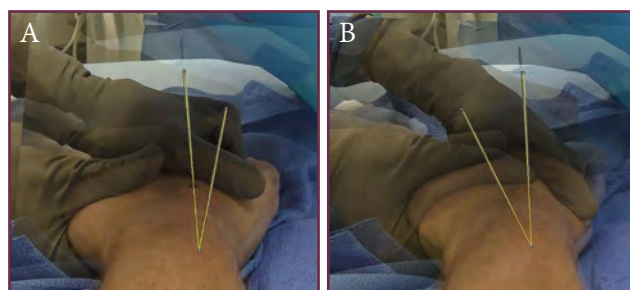
**Figure 1.** (A) Radiograph of the hand, showing wire placement in the distal radius. (B) Coronal view along the long axis of the forearm, showing the K-wires placed in the distal radius and second metacarpal. Notably, the wires are placed parallel to one another; thus, the second metacarpal wire is blocked from view by the distal radius wire.



**Figure 2.** Coronal view along the long axis of the forearm, showing the K-wires placed in the distal radius and second metacarpal. (A) Maximum internal radiocarpal rotation. (B) Maximum external radiocarpal rotation.

## Results

Superimposition of the three photographs in vivo allowed us to approximate two angle measurements which correspond to the degree of radiocarpal motion with internal and external rotations about the long axis of the forearm (Figures 3A and 3B). With maximum internal rotation, the measured radiocarpal rotation was 16°. With maximum external rotation, the radiocarpal rotation was 24°.



**Figure 3.** Superimposed images showing maximum rotations of the forearm, with the hand fixed to allow radiocarpal motion only and to negate forearm rotation. (A) Internal rotation (pronation) of the forearm. (B) External rotation (supination) of the forearm.

## Discussion

Our study has allowed us to quantify radiocarpal rotation in vivo. We demonstrated this motion by quantifying the degree of radiocarpal rotation with internal and external rotations using images taken from an awake patient with wires inserted into the base of the second metacarpal and the distal radius. This radiocarpal motion was notable and ranged between 16° and 24°. In replicating wrist kinematics, which can be observed in radiocarpal implant designs used in arthroplasty, this motion must be considered to ensure a stable implant that does not loosen and fail postoperatively.

The contribution of carpal motion at the midcarpal and radiocarpal joint has been previously measured during extension and flexion of the wrist and radial and ulnar deviation. The potential effects of ligament laxity on these movements have been described.<sup>4,6,8,16,22-24</sup> Our study provided quantification of in vivo radiocarpal motion when native muscles are loaded with the hand in a fixed position. This motion is observable when turning a screw driver or a door knob forcibly.

Further, cohort studies that considered variation in different patient demographics would better quantify radiocarpal rotation and assess the range of radiocarpal motion. Results of the current study revealed a range of degrees of motion in vivo, which can help investigate this concept using less invasive techniques such as imaging modalities (eg, 4D CT or MRI). Findings of 4D CT and MRI have been used in previous studies to investigate wrist kinematics and offer precise analysis of carpal-bone motion during movements of the wrist.<sup>8</sup>

We acknowledge that the implications of our study are limited. The current study included one patient and therefore did not offer a large sample size from which sufficient data can be extrapolated and applied to the general population. Our angle generation relied on the superimposition of three images, which has the potential for measurement error of angle estimation. However, we expected a range of motion and not an absolute number.

Findings of our study suggest that radiocarpal rotation does occur. Subsequently, this motion should be considered in addition to the better understood flexion, extension, radial, and ulnar deviations. We plan to further study and quantify this motion for consideration during wrist arthroplasty and design of wrist implants.

## Funding

The authors received no financial support for the research, authorship, and publication of this article.

## Conflict of Interest

The authors report no conflicts of interest.

## References

1. Bryce TH. Certain points in the anatomy and mechanism of the wrist-joint reviewed in the light of a series of Röntgen ray photographs of the living hand. *J Anat Physiol* 1896;31(pt 1):59-79.
2. Macconail MA. The mechanical anatomy of the carpus and its bearings on some surgical problems. *J Anat* 1941;75(pt 2):166-75.
3. Fisk GR. Carpal instability and the fractured scaphoid. *Ann R Coll Surg Engl* 1970;46(2):63-76.
4. Kobayashi M, Berger RA, Nagy L, et al. Normal kinematics of carpal bones: a three-dimensional analysis of carpal bone motion relative to the radius. *J Biomech* 1997;30(8):787-93.
5. Horii E, Garcia-Elias M, An KN, et al. A kinematic study of luno-triquetral dissociations. *J Hand Surg Am* 1991;16(2):355-62.
6. Ruby LK, Cooney WP 3rd, An KN, Linscheid RL, Chao EY. Relative motion of selected carpal bones: a kinematic analysis of the normal wrist. *J Hand Surg Am* 1988;13(1):1-10.
7. Kamal RN, Rainbow MJ, Akelman E, Crisco JJ. In vivo triquetrum-hamate kinematics through a simulated hammering task wrist motion. *J Bone Joint Surg Am* 2012;94(12):e85. doi: 10.2106/JBJS.J.01644.
8. Rainbow MJ, Wolff AL, Crisco JJ, Wolfe SW. Functional kinematics of the wrist. *J Hand Surg Eur Vol* 2016;41(1):7-21. doi: 10.1177/1753193415616939.
9. Crisco JJ, Heard WM, Rich RR, Paller DJ, Wolfe SW. The mechanical axes of the wrist are oriented obliquely to the anatomical axes. *J Bone Joint Surg Am* 2011;93(2):169-77. doi: 10.2106/JBJS.I.01222.
10. Bain GI, Clitherow HD, Millar S, et al. The effect of lunate morphology on the 3-dimensional kinematics of the carpus. *J Hand Surg Am* 2015;40(1):81-9.e1. doi: 10.1016/j.jhsa.2014.09.019.
11. Braidotti F, Atzei A, Fairplay T. Dart-Splint: an innovative orthosis that can be integrated into a scapho-lunate and palmar midcarpal instability re-education protocol. *J Hand Ther* 2015;28(3):329-34; quiz 335. doi: 10.1016/j.jht.2015.01.007.
12. Singh HP, Brinkhorst ME, Dias JJ, Moojen T, Hovius S, Bhowal B. Dynamic assessment of wrist after proximal row carpectomy and 4-corner fusion. *J Hand Surg Am* 2014;39(12):2424-33. doi: 10.1016/j.jhsa.2014.09.005.



13. Franko OI, Lal S, Pauyo T, Alexander M, Zurakowski D, Day C. Validation of an objective device for assessing circumductive wrist motion. *J Hand Surg Am* 2008;33(8):1293-300. doi: 10.1016/j.jhsa.2008.03.012.
14. Crisco JJ, McGovern RD, Wolfe SW. Noninvasive technique for measuring in vivo three-dimensional carpal bone kinematics. *J Orthop Res* 1999;17(1):96-100.
15. Feipel V, Rooze M, Louryan S, Lemort M. Bi- and three-dimensional CT study of carpal bone motion occurring in lateral deviation. *Surg Radiol Anat* 1992;14(4):341-8.
16. Moojen TM, Snel JG, Ritt MJ, Kauer JM, Venema HW, Bos KE. Three-dimensional carpal kinematics in vivo. *Clin Biomech (Bristol, Avon)*. 2002;17(7):506-14.
17. Moritomo H, Viegas SF, Elder KW, et al. Scaphoid nonunions: a 3-dimensional analysis of patterns of deformity. *J Hand Surg Am* 2000;25(3):520-8.
18. Choi YS, Lee YH, Kim S, Cho HW, Song HT, Suh JS. Four-dimensional real-time cine images of wrist joint kinematics using dual source CT with minimal time increment scanning. *Yonsei Med J* 2013;54(4):1026-32. doi: 10.3349/ymj.2013.54.4.1026.
19. Edirisinghe Y, Troupis JM, Patel M, Smith J, Crossett M. Dynamic motion analysis of dart throwers motion visualized through computerized tomography and calculation of the axis of rotation. *J Hand Surg Eur Vol* 2014;39(4):364-72. doi: 10.1177/1753193413508709.
20. Leng S, Zhao K, Qu M, An KN, Berger R, McCollough CH. Dynamic CT technique for assessment of wrist joint instabilities. *Med Phys* 2011;38(suppl 1):S50. doi: 10.1118/1.3577759.
21. Zhao K, Breighner R, Holmes D 3rd, Leng S, McCollough C, An KN. A technique for quantifying wrist motion using four-dimensional computed tomography: approach and validation. *J Biomech Eng* 2015;137(7). doi: 10.1115/1.4030405.
22. Wolff AL, Garg R, Kraszewski AP, et al. Surgical treatments for scapholunate advanced collapse wrist: kinematics and functional performance. *J Hand Surg Am* 2015;40(8):1547-53. doi: 10.1016/j.jhsa.2015.04.035.
23. Garcia-Elias M, Ribe M, Rodriguez J, Cots M, Casas J. Influence of joint laxity on scaphoid kinematics. *J Hand Surg Br* 1995;20(3):379-82.
24. Goto A, Moritomo H, Murase T, et al. In vivo three-dimensional wrist motion analysis using magnetic resonance imaging and volume-based registration. *J Orthop Res* 2005;23(4):750-6.

# 3D Bioprinter + Electrospinner for Bone-Ligament Tissue Engineering

Sherif H. Aboubakr, MS<sup>\*†</sup>; Steven Nery, BS<sup>\*‡</sup>; Lauren Long, BS<sup>\*</sup>; Christopher A. Buksa, BS<sup>\*§</sup>; Chanju Fritch, BS<sup>\*¶</sup>; Christina Salas, PhD<sup>\*§¶</sup>

<sup>\*</sup>Department of Orthopaedics & Rehabilitation, The University of New Mexico Health Sciences Center, Albuquerque, New Mexico

<sup>†</sup>Department of Civil Engineering, The University of New Mexico, Albuquerque, New Mexico

<sup>‡</sup>Department of Electrical Engineering, The University of New Mexico, Albuquerque, New Mexico

<sup>§</sup>Department of Mechanical Engineering, The University of New Mexico, Albuquerque, New Mexico

<sup>¶</sup>School of Medicine, The University of New Mexico Health Sciences Center, Albuquerque, New Mexico

<sup>¶¶</sup>Center for Biomedical Engineering, The University of New Mexico, Albuquerque, New Mexico

## Abstract

Modern 3D bioprinters have been shown to allow for precise control of structural geometry to build patient-specific scaffolds for tissue regeneration—primarily non-load-bearing tissue. However, 3D bioprinting is limited by cell viability, polymer cross-linking characteristics, and poor tensile properties. In comparison, electrospinning has been used to form fibrous structures with accelerated cellular maturation properties, improved growth and migration of cells, and increased tensile properties. Conversely, the mostly uncontrolled deposition of electrospun fibers can limit pore size and cell infiltration. In our Orthopaedic Biomechanics & Biomaterials Laboratory, a custom 3D Bioprinter + Electrospinner hybrid system (E-Spin Printer) was designed to merge the positive aspects of both technologies to allow for hierarchical, functionally-graded scaffolds with high load-bearing characteristics. This hybrid system was made from open-source components and is customizable to meet the accuracy, resolution, and repeatability of high-end bioprinters and electrospinning, at a cost of less than \$10,000. We introduce this technology and provide a broad description of one application for its use.

## Introduction

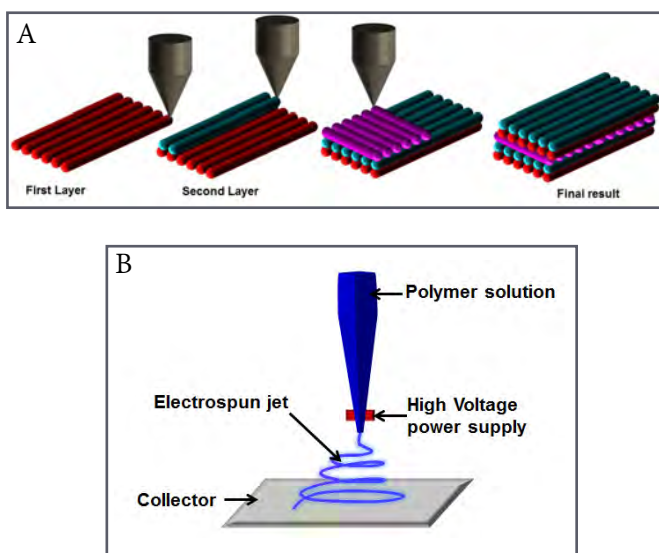
3D bioprinting can be defined as the printing of biopolymer and high-concentration cell solutions. Typically, 10 to 1000  $\mu\text{m}$  resolution is required to form tissue-like structures, with higher-viscosity materials often providing structural support for the printed structure and lower-viscosity materials providing a suitable environment for maintaining

cell viability and function. Laboratories across the world have designed and created 3D bioprinters to fabricate replacement human-scale tissues and organs, often with structural integrity and biological function similar to native tissues. These printed structures have been shown to be stable and amenable to revascularization, making them ideal for application in replacement of injured tissue. At this time, few bioprinter systems have been targeted toward fabricating tissue with high tensile and compressive strength requirements.

The main steps in the 3D bioprinting process are imaging and digital design, selection of materials and cells, and printing of the scaffolds.<sup>1-6</sup> Imaging such as computed tomography (CT) and magnetic resonance imaging (MRI) are essential to replicate the complex, heterogeneous architecture of functional tissues. Further segmentation, surface rendering, and stereolithographic editing can provide a full volumetric description of the specific tissue examined. Computer-aided design and computer-aided manufacturing (CAD-CAM) tools and mathematical modeling techniques can then be used to collect and digitize the complex tomographic and architectural information. This is followed by deposition and patterning of materials in successive layers as directed by the CAD-CAM software, wherein each deposited layer serves as a foundation for the following layers until the 3D structure is patterned and completed (Figure 1A). Inkjet, micro-extrusion, and laser-assisted printing can all be used for deposition and patterning tissue materials.<sup>1-6</sup>

The electrospinning fabrication technique uses high voltage (5 to 30 kV) to create an electric field between a droplet of polymer solution (typically at the tip of a syringe needle) and a metallic collector plate (Figure 1B). The main

forces acting on the polymer droplet are the electrostatic field and the electrostatic repulsion of charges. These forces are opposed by the surface tension of the droplet, and the viscoelastic forces of polymer. When electrostatic repulsion charges exceed the surface tension, stretching (ie, elongating at very high strain rates) of the polymer droplet occurs, and a continuous fiber is ejected toward the collector plate. Polymer solution viscosity, surface tension, electrical conductivity, and dielectric constant are key parameters for the electrospinning process controllable by solution selection and optimization. Applied voltage, flow rate of solution, collector material properties, diameter of the needle, and distance between applicator and collector are other key parameters of the electrospinning process controllable by hardware setup, selection, and design. Temperature, humidity, and pressure should also be considered.<sup>7,8</sup>



**Figure 1.** (A) Representative example of 3D bioprinting using multiple bioinks deposited from their respective syringe deposition systems. (B) Representative schematic describing the primary characteristics of an electrospinner.

Traditionally, electrospinning processes have control over microstructural porosity, density, and tensile strength while lacking macroscale geometric control. Porosity and density control has been shown to enable cellular migration, elongation, and proliferation needed for differentiation of mesenchymal stem cells to ligament fibroblasts. The tensile strength characteristics will enable properties closer to that of native ligament than other biomanufacturing techniques. Electrospinner characteristics contrast to those of the 3D-bioprinting process that allows for geometric control but lacks a process to vary microstructural properties. Shortcomings of 3D bioprinting are especially limiting when tissues must be attached to bone; the materials

that contain properties amenable to extrusion and cellular viability do not adhere to rigid structures without considerable material modifications. The geometric control allowed by 3D printing will enable patient-specific reproductions of the hard and regeneration of soft tissue. The cost of isolated electrosp spinners ranges from \$25,000 to \$50,000 with electro spray capabilities. Entry-level 3D bioprinters commercially range from \$75,000 to \$500,000 with multiple nozzles and additional features for polymerization of materials.

We introduce the development of a low-cost, modular 3D Bioprinter + Electrospinner hybrid system (E-Spin Printer) for targeted fabrication of scaffolds of the bone, ligament, and bone-ligament interface. This system aims to merge the positive aspects of each technology. We present a summary of the developed technology and describe an application for its use. All fabrication and experimental validation was completed our Orthopaedic Biomechanics & Biomaterials Laboratory.

## Design

The design of our technology is presented henceforth. It is important to note that while we describe specific materials used in development of the first prototype, the design is universal such that similar materials from different manufacturers may serve the same purpose.


### *Stepper Motor Controller*

The printer is controlled by a Smoothieboard 5x, a low cost (< \$200), open source stepper motor controller with flexible software configuration (Uberclock, Gold Hill, OR). The controller runs five stepper motors simultaneously, with up to 2.5 amps of current when powered with a 24-volt power supply. Our printer uses five motors in its current design: three for X, Y, Z motion and two to drive custom syringe pumps (one for printer, one for electrospinner). The other inputs of the Smoothieboard could also run several cooling fans and multiple heated beds, and the inputs are compatible with most open-source software. The controller was chosen for its flexible hardware and software configurations and extensive online documentation. As additional print heads or other items are added to the system, it may be necessary to add a larger controller or additional controllers to handle the added components.

### *Linear Stages*

For X, Y, and Z axis movement, we purchased several Newmark eTrack linear stages for their specified resolution,

accuracy and repeatability (Newmark Systems Inc, Rancho Santa Margarita, CA). Each stage was fitted with a NEMA 17 stepper motor rated at 1.2 amps. The leadscrew configuration of the linear stages allows for more precise movement over belt-driven stages at the cost of speed. The X stage is 300-mm long, whereas the Y and Z stages are 200 mm and 150 mm, respectively. The X stage enables positioning of the build plate under the 3D bioprinter or electrospinner deposition heads, respectively. The Y stage is mounted orthogonally to the X stage for front-to-back plate positioning. The Z axis is vertically mounted to the frame of the printer, allowing for height control of the print nozzle. Newmark rails range from \$782 (50 mm) to \$962 (300 mm). The selected rails have a 0.24-mm resolution, an accuracy of 0.0006 mm/mm, and a max speed of 150 mm/s. Figure 2 shows the X, Y, and Z rails mounted in the frame of the E-Spin Printer.



**Figure 2.** Early embodiment of our E-Spin Printer hybrid system. X, Y, and Z linear stages are noted with arrows showing axis of travel.

### Print Bed

The custom print bed was designed as a surface for printed material and an electrical conductor for the electrospinner of the system. The print bed is a layered system of acrylonitrile-butadiene-styrene (known as ABS) plastic, rubber, nylon, aluminum, and glass supported by three leveling screws (Figure 3). The aluminum layer is machined to allow insertion of a 4- by 6-inch heated polychlorinated-biphenyl (PCB) bed. To help reduce unwanted conductivity from the electrified print bed during electrospinning, a 1-inch air gap was designed between the print bed and Y-linear stage. Additionally, the print bed is attached to the linear stage using nylon screws to further reduce unwanted electrical charge throughout the system.



**Figure 3.** Close-up view of an early embodiment of our hybrid system showing the build plate (asterisk), bioprinter syringe pump (left arrow), and electrospinner syringe pump (right arrow).

### Syringe Pumps


The extrusion system consists of two custom syringe pumps that were constructed using 3D-printed nylon and off-the-shelf hardware (Figure 3). The design borrows and improves on the open-source OpenPump system and is one of the most cost-effective ways to create a syringe pump. To reduce torsion during syringe deposition, the end-mounts were redesigned to attach directly to a custom base plate that fixed to the Z axis of the printer frame. The fixture that holds the syringe plunger was modified to allow easy access to slide bearings and improve grip on the plunger of the syringe during deposition. Each pump was fitted with a NEMA 17 stepper motor controlled by the Smoothieboard. The hardware consists of an M5 threaded rod, M8 smooth rods, couplers and slide bearings.

### Electrospinner

The electrospinner consists of a steel syringe tip, the aluminum plate of the print bed, and a low-cost (\$250) 5- to 30-kV variable high-voltage power supply purchased from Information Unlimited (Amherst, NH). The power supply was chosen for its low cost and safety features, specifically, a current limiting feature to reduce risk of shock or injury, which lowers amperage to safe levels (700  $\mu$ A at 35 kV). In operation, the negative lead of the power supply clamps directly to the aluminum plate of the build plate, and the positive lead connects directly to the steel needle of the mounted syringe. As voltage is increased, an electric field is created between the syringe needle and print bed. Solution exiting the syringe becomes charged and quickly collects on the glass surface of the negatively-

charged build plate (Figure 4).

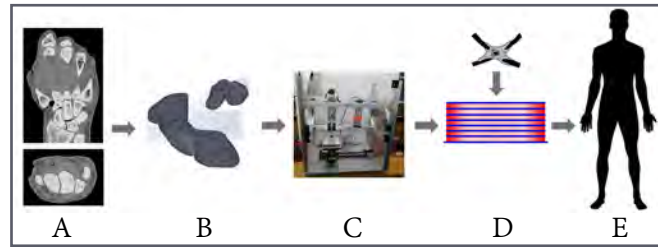
Our system also includes a modification to allow for aligned fiber spinning. For this, the negative lead is replaced by two negative leads, each is connected to a single extruded metal bar positioned on either side of the desired print surface, near the target area. The negative leads are triggered in an alternating fashion to direct flow of the solution exiting the syringe, back and forth depending on the activated lead.



**Figure 4.** Close-up view of electrospun fiber deposition on build-plate (white). Note the white lead at the bottom that provides a negative charge to the plate.

### 3D-Modeling Software

All initial 3D modeling was created using OpenSCAD, an open-source CAD program. The program was free under the General Public License and allowed for rapid modeling and stereolithography file exporting. When moving toward patient-specific modeling of hard and soft-tissue scaffolds, we will use Mimics (Materialise, Leuven, Belgium) CT and MRI to 3D-modeling software and MedCad (Dallas, TX) for integrating the scaffolds with surrounding hard tissue. A flowchart of the planned steps for fabrication are shown in Figure 5. In short, a torn ligament would be identified through CT or MRI (A). The data can be exported to a medical imaging software to develop a 3D model of the bone and insertion points (B). The software can be used to simulate native tissue replacement. Solid files can be exported and read by the E-Spin Printer and converted to G-code for fabrication (C). The scaffold is built and cells are seeded for growth (D). The scaffold can be immediately implanted into a patient, or the tissue can be grown fully before implantation (E).



**Figure 5.** Flowchart showing representative process for moving from computed tomography and magnetic resonance imaging (MRI) to implantation.

### Slicing Software

Our printer currently uses the open-source program Slic3r to generate G-code for construction. Slic3r was chosen because, with some code modification, it allows the user to assign extruders (ie, syringe pumps) to each material to be printed or spun. This feature was exploited to allow our machine to alternate between our syringe pumps (each holding different materials). By exploiting this feature, we are also able to create a gradient between materials in all directions (X, Y, Z). More on material deposition is described in subsequent sections. Currently, popular open-source 3D slicing software is not optimized for bioprinting. Future embodiments of our technology will require advanced customization of the Slic3r software to allow for use of three or more bioinks and electrospun filament.

### Potential Fabrication Materials

**3D bioprinter—synthetic and natural bioinks.** Alginate was chosen as a suitable hydrogel to validate our 3D-bioprinting technology. An alginate-based bioink was printed, and hydroxyapatite (HAp) bioceramic particles were added to enhance mechanical properties to ensure a functionally graded bone-ligament interface transition. Notably, alginate requires mixture with calcium ions for polymerization. Thus, this material may not be suitable for use in mammals owing to calcium ion leaching that would surely occur. Thus polyethylene (glycol) diacrylate (known as PEG-DA) with a photoinitiator has been selected as a new printing material to control viscosity by addition of exfoliated clay<sup>9</sup> or HAp nanoparticles. Note that the current design is not limited to any polymer type, but some polymers may require implementation of additional materials or hardware to aid in polymerization. e.g. A photoinitiator and UV lighting system may be required for polymerization. It is important to also note that cells can be included in the composition of the bioink. The cell-infused bioink is transported via syringe pumps through the system. When cells are included, further optimization of the syringe pump control will be needed to maintain

cellular viability. Additionally, we are working with a collaborator for printing of cell-encapsulating proteins that would aid in direct-cell printing.

**Electrospinner—synthetic and natural polymers.** Polycaprolactone (PCL) was chosen as a primary test material because it has been shown to be a suitable, biocompatible polymer for electrospinning.<sup>10,11</sup> However, collagen will be used in future iterations because of its function as a component of extracellular matrix (ECM) in connective tissues.<sup>12</sup> This makes it a more suitable choice for electrospun connective-tissue scaffolds. Collagen fiber alignment is essential for scaffold architecture and mechanical properties. Moreover, the use of collagen fiber diameter has been critical in the design of scaffolds because it is deterministic of scaffold mechanical properties, cell proliferation, matrix production, and differentiation regulation.<sup>13</sup>

## Application

As a first application of our technology, we aim to print a patient-specific bone-ligament scaffold for regeneration of the scapholunate ligament.

### *Problem*

The scapholunate ligament has been identified as the most commonly injured hand ligament by the American Society for Surgery of the Hand.<sup>14</sup> Ligament healing is not common owing to a reduced number of cells and blood vessels that exist in and around the soft tissue. Healing, usually in partial tears of the ligament, is often a result of scar-tissue formation. For full ligament ruptures, the most common surgical treatment is ligament reconstruction, usually with a tendon harvested from the upper extremity. Unfortunately, autografts have been shown to cause donor-site morbidity and do not match the mechanical properties of the native tissue. Therefore, orthopaedic-related research has focused on strategies to improve and accelerate the healing process through tissue-engineered scaffolds.<sup>15-18</sup>

### *Notable Considerations in Tissue Engineering*

When designing and assessing a scaffold for use in tissue engineering, the following six factors should be considered: 1) Biocompatibility: scaffolds should be biocompatible for cells to adhere, function, and migrate onto the surface and through the scaffold. Scaffold implantation must evoke a negligible immune reaction to prevent any excessive inflammatory responses. 2) Biodegradability: scaffolds are not intended to be permanent implants and should

eventually be replaced by native tissue. The scaffold degradation byproducts should not be cytotoxic. 3) Mechanical properties: scaffolds should have mechanical properties (ie, strength and stiffness) consistent with the anatomical site into which it is to be implanted. Moreover, scaffolds should be practically strong enough to allow for manual manipulation during surgical procedures. 4) Mechanical integrity: scaffolds should have sufficient mechanical integrity to function from the time of implantation to completion of the remodeling process of native tissue. 5) Scaffold architecture: scaffolds should accommodate cellular penetration and adequate diffusion of nutrients and waste products to and from cells. 6) Fabrication technology: scaffolds should be cost effective and patient specific to be commercially and clinically viable.<sup>1,18</sup>

### *Scaffold Fabrication Process*

The introduced E-Spin Printer system allows for a functionally-graded (laterally), alternating layer (vertically) deposition method. The novelty of our technology, using a single X-Y rail system underlying the 3D bioprinter and electrospinner syringe pumps, respectively, allows for this unique deposition method. The functionally-graded characteristic will allow a gradual transition, horizontally, from the bone phase to ligament phase then back to bone phase using bioinks from multiple syringes—each with a varying concentration of HAP nanoparticles and other necessary material modifiers. The bulk scaffolds will vary vertically made from alternating layers of PEGDA-based bioink (or other) and PCL (collagen, or other) electrospun fibers (Figure 6).

The bioinks will be tuned to serve as a viable ECM environment to support cell migration, growth, and proliferation. To aid in this, some bioinks will be fabricated from decellularized human tissue such that the ECM environment is maintained to support desired cellular activity. The electrospun fibers will be tuned to support high tensile loads such as those experienced by the native ligament; these fibers provide most of the mechanical stability and strength of the bulk scaffold. Multiscale material and structural optimization will be required to control microstructure, mechanical properties, and biodegradation rates of the scaffold.

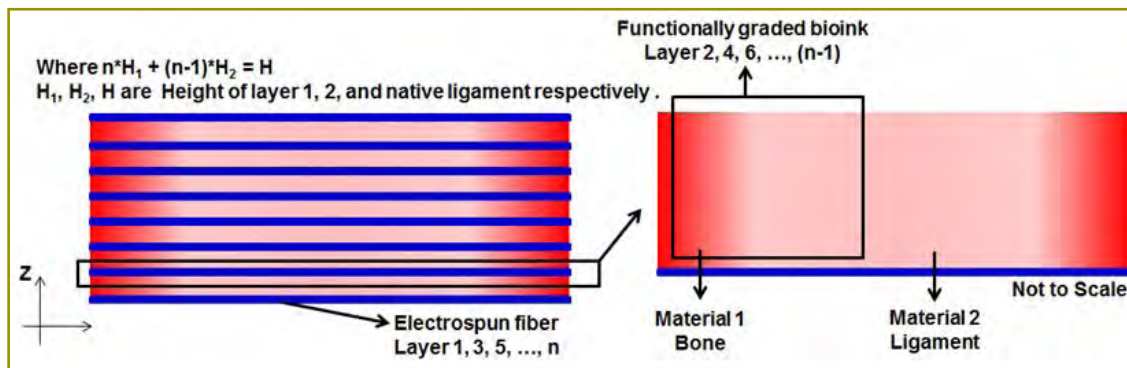


Figure 6. Schematic representation of the (Left) hierarchical and (Right) functionally-graded composite scaffold targeted with this technology.

## Conclusion

The current article introduces our custom E-Spin Printer hybrid system and provides broad details on one application for this new technology. This system combines state-of-the-art digital composite fabrication tools of 3D-bioprinting and electrospinning to target fabrication of hierarchical, 3D scaffolds for regeneration of bone, ligament, and the bone-ligament transition region. By starting with the scapholunate ligament to validate our technology, this hybrid system has broad and notable application in all areas of tissue engineering, particularly those areas with high tensile (ie, ligaments and tendons) and compressive (ie, meniscus and cartilage) load-sustaining requirements. The 3D printing aspect of the system will further allow for targeted implantation and customization for tissue replacement at any anatomical region. Furthermore, the open-source, modular nature of our hybrid technology was achieved at a cost less than \$10,000—which was nearly \$100,000 less than any commercially-available 3D bioprinter with the same capabilities—and \$15,000 less than the least expensive electrospinner.

## Funding

The authors received support from a basic science research grant from the American Foundation for Surgery of the Hand and a faculty-development award from Advance@UNM, a National Science Foundation (NSF)-funded project at The University of New Mexico (UNM). Additional financial support was provided by UNM Department of Orthopaedics & Rehabilitation.

## Conflict of Interest

The authors report no conflicts of interest.

## Acknowledgments

Special thanks to Dr. Mahmoud Reda Taha and Dr. Nick Carroll in The University of New Mexico Department of Civil Engineering and Department of Chemical and Biological Engineering, respectively, for their cooperation and support.

## References

- O'Brien FJ. Biomaterials & scaffolds for tissue engineering. *Mater Today (Kidlington)*;14(3):88-95. doi: 10.1016/S1369-7021(11)70058-X.
- Murphy SV, Atala A. 3D bioprinting of tissues and organs. *Nat Biotechnol* 2014;32(8):773-85. doi: 10.1038/nbt.2958.
- Zhu W, Ma X, Gou M, Mei D, Zhang K, Chen S. 3D printing of functional biomaterials for tissue engineering. *Curr Opin Biotechnol* 2016;40:103-12. doi: 10.1016/j.copbio.2016.03.014.
- Dodziuk H. Applications of 3D printing in healthcare. *Kardiochir Torakochirurgia Pol* 2016;13(3):283-293.
- Zhang X, Zhang Y. Tissue engineering applications of three-dimensional bioprinting. *Cell Biochem Biophys* 2015;72(3):777-82. doi: 10.1007/s12013-015-0531-x.
- Hözl K, Lin S, Tytgat L, Van Vlierberghe S, Gu L, Ovsianikov A. Bioink properties before, during and after 3D bioprinting. *Biofabrication* 2016;8(3):032002.
- Teo WE, Ramakrishna S. A review on electrospinning design and nanofiber assemblies. *Nanotechnology* 2006;17(14):R89-R106. doi: 10.1088/0957-4484/17/14/R01.
- Reneker DH, Yarin AL. Electrospinning jets and polymer nanofibers. *Polym* 2008;49(10):2387-425.
- Hong S, Sycks D, Chan HF, et al. 3D printing of highly stretchable and tough hydrogels into complex, cellularized structures. *Adv Mater* 2015;27(27):4035-40. doi: 10.1002/adma.201501035.
- Croisier F, Duwez AS, Jérôme C, et al. Mechanical testing of electrospun PCL fibers. *Acta Biomater* 2012;8(1):218-24. doi: 10.1016/j.actbio.2011.08.015.

11. Kang X, Xie Y, Powell HM, et al. Adipogenesis of murine embryonic stem cells in a three-dimensional culture system using electrospun polymer scaffolds. *Biomaterials* 2007;28(3):450-8.
12. Mienaltowski MJ, Birk DE. Structure, physiology, and biochemistry of collagens. *Adv Exp Med Biol* 2014;802:5-29. doi: 10.1007/978-94-007-7893-1\_2.
13. Erisken C, Zhang X, Moffat KL, Levine WN, Lu HH. Scaffold fiber diameter regulates human tendon fibroblast growth and differentiation. *Tissue Eng Part A* 2013;19(3-4):519-28. doi: 10.1089/ten.tea.2012.0072.
14. Wolfe SW. Scapholunate instability. *J Am Soc Surg Hand* 2001;1(1):45-60. doi: 10.1002/adma.201501099.
15. Hogan MV, Kawakami Y, Murawski CD, Fu FH. Tissue engineering of ligaments for reconstructive surgery. *Arthroscopy* 2015;31(5):971-9. doi: 10.1016/j.arthro.2014.11.026.
16. Yilgor C, Yilgor Huri P, Huri G. Tissue engineering strategies in ligament regeneration. *Stem Cells Int* 2012;2012:374676. doi: 10.1155/2012/374676.
17. Sapir-Lekhovitser Y, Rotenberg MY, Jopp J, Friedman G, Polyak B, Cohen S. Magnetically actuated tissue engineered scaffold: insights into mechanism of physical stimulation. *Nanoscale* 2016;8(6):3386-99. doi: 10.1039/c5nr05500h.
- 18: Rodrigues MT, Reis RL, Gomes ME. Engineering tendon and ligament tissues: present developments towards successful clinical products. *J Tissue Eng Regen Med* 2013;7(9):673-86. doi: 10.1002/term.1459.



# Automated Device to Enable Passive Pronation and Supination Activities of the Hand for Experimental Testing with Cadaveric Specimens: A Collaboration Between The University of New Mexico and New Mexico Institute of Mining and Technology

Jodie Gomez, BS<sup>\*†</sup>; Jakub Mroczkowski, BS<sup>†</sup>; Lauren Long, BS<sup>\*</sup>; Christopher A. Buksa, BS<sup>\*†</sup>; Deana M. Mercer, MD<sup>\*</sup>; Christina Salas, PhD<sup>\*†§</sup>; David I. Grow, PhD<sup>\*‡</sup>

<sup>\*</sup>Department of Orthopaedics & Rehabilitation, The University of New Mexico Health Sciences Center, Albuquerque, New Mexico

<sup>†</sup>Department of Mechanical Engineering, The University of New Mexico, Albuquerque, New Mexico

<sup>‡</sup>Department of Mechanical Engineering, New Mexico Institute of Mining and Technology, Socorro, New Mexico

<sup>§</sup>Center for Biomedical Engineering, The University of New Mexico, Albuquerque, New Mexico

## Abstract

In cadaveric research, reproducing physiological conditions under which the specimens would be loaded in vivo is essential to achieve clinical applicability. This is a collaborative study bringing together engineers from The University of New Mexico and New Mexico Institute of Mining and Technology. We describe development of an automated device to enable *passive* pronation and supination of the hand (rotation achieved through direct manipulation) for use in cadaveric experimental testing of the hand, wrist, forearm, or elbow. We present a brief motivation for development of this device, design details, an overview of one possible application, and ways to use this device for *active* pronation and supination activities (rotation achieved through tendon loading). We aim to provide the necessary information for reproduction of this device by other institutions for similar testing purposes.

## Introduction

When conducting experimental tests on cadavers, it is essential to reproduce physiological conditions under which the specimens would be loaded in vivo. For example,

when performing tests on a femur, it is important to apply a combination of axial, torsional, and bending loads that would normally be applied to the bone while a person walks or runs. These loads can be applied with custom-made testing fixtures that represent the acetabulum and tibial plateau for simulated articulation with the hip and tibia, respectively. Custom fixtures can be attached to a load frame programmed to provide the loading conditions. In the case of the human hand and forearm, the reproduction of physiological motion can be challenging owing to the various bones and soft tissue that allow the hand to move in a variety of ways.

We were tasked with developing an automated system that enabled pronation and supination motions of a cadaveric hand. The device would be used in a study on the contribution of the interosseous membrane and annular ligament to the stability of the radial head.

The goals of the system were as follows: 1) control pronation and supination activities of the hand through an automated mechanism; 2) hold the arm at a 90° elbow-flexion angle while subjecting the forearm to a simulated load through the long axis of the forearm and a load through the biceps brachii tendon attachment on the radius, in line with the muscle pull; 3) enable

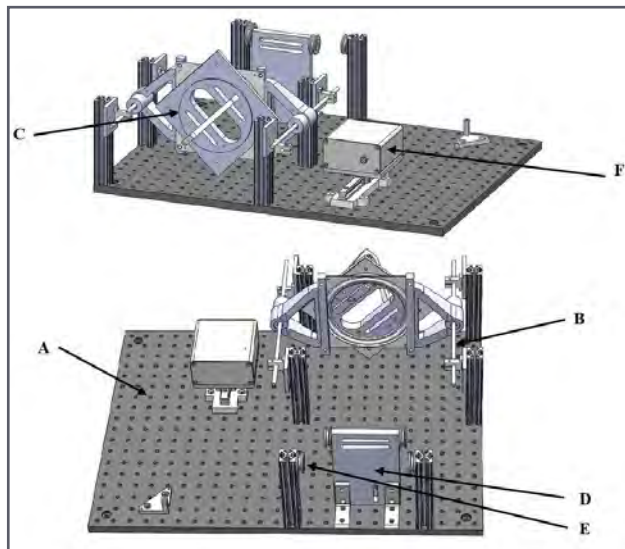
high-resolution motion capture of the specimen through strategically placed retroreflective markers; and 4) allow correlation of the motion data at all angles from 45° of pronation to 45° of supination of the hand with the use of frame mounted markers.

## Design

We designed a modular and adjustable testing fixture capable of dynamic motion. Multiple pieces immobilized the arm as necessary, controlled specific motions to simulate arm movement, and collected the desired data outputs. These pieces included: a rigid base plate; a linear rail system for adjustability and axial movement; a hand-rotation assembly for guiding pronation and supination activities; a fixation plate for stabilizing the humerus; a pulley system for applied external loads; a high-resolution, motion capture system for determining rotations and translations of specified bones; and a belt-drive system for pronation and supination motions of the hand.

### Rigid Base Plate


The rigid base plate consists of a grid of threaded holes that enables adjustments and relocation of the fixture components to accommodate the anatomical variations of each specimen (Figure 1). This allows the fixture to be customized based on the length and width of each specimen. The plate was bolted to a table to ensure rigid and consistent placement of the fixture during testing.



**Figure 1.** Two oblique views of the full device. Each component is coded by letter and referenced in the body of the article: A, rigid base plate; B, linear rail system; C, hand rotation assembly; D, humerus fixation plate; E, pulley system; and F, motor control system.

### Linear Rail System

The linear rail system is fixed to the rigid base plate and hand-rotation assembly. It supports the weight of the hand and forearm, holding them above the base plate (Figures 1, 2A, and 2B). The parallel positioning of the linear rail system enables low-friction movement of the hand-rotation assembly during axial loading (longitudinally).




**Figure 2.** (A) Solid model of linear rail assembly positioned on the base plate. (B) Oblique view of the rail assembly showing parallel positioning on either side of the forearm. These rails allow for suspension of the arm with the hand rotation assembly. Axial compressive forces can be applied to the forearm by loading the hand rotation assembly so that it compresses the forearm toward the humerus fixation plate.

### Hand-Rotation Assembly

The hand-rotation assembly consists of multiple parts including a rotation turntable (gray), side extensions (orange), and a front face (white and light blue; Figure 3A). The rotation turntable has a stationary half and a rotating half. The stationary half connects to the linear rails using the extensions on either side of the turntable through bushings. These extensions were computer-modelled and 3D-printed in acrylonitrile butadiene styrene (ABS). This design aligns the long axis of the specimen with the linear rails of the fixture and supports the weight of the specimen. The extensions were fixed to and hold up the stationary half of the turntable.

Between the stationary and rotating halves of the turntable is an array of roller bearings that allow for low-

friction rotation. On the rotating front face, a 3D-printed nylon part supports the hand through a slot and allows fixation of the hand using a K-wire; this part renders rotational motion from the turntable to the hand and forearm (Figure 3B). The design allows for pinning of multiple hand sizes, complete immobilization of wrist flexion, and rotations between full pronation and supination. Extending from the front face of the rotating turntable is a circular shoulder that provides the surface for a rubber belt to be adhered and interfaced with the motor-control system. It also features four locations, where motion capture markers are placed for tracking the angular position of the rotating turntable. The linear rail system and hand-rotation assembly collectively allow for rotation of the forearm and hand about the long-axis of the forearm.

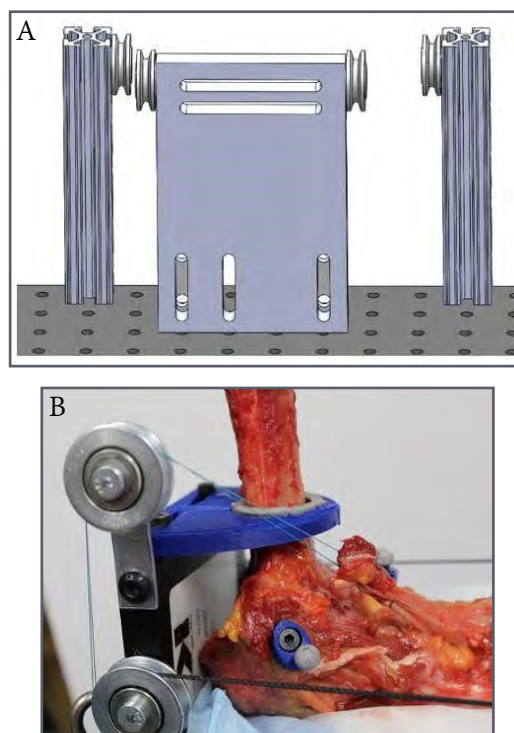


**Figure 3.** Hand rotation assembly. (A) Solid model. (B) 3D-printed device with hand inserted to describe attachment of the hand to the device.

#### *Humerus Plate*

The humerus plate allows for the elbow to be flexed at 90° and raised off the rigid base plate to ensure the motion capture markers move in space without restrictions and remain visible to the motion capture cameras. Option one (Figure 4A): the humerus of the specimen can be bolted to the humerus plate through slots that allow for translation and elevation of the humerus and elbow so that they are aligned with the forearm and hand (within the hand-rotation assembly). The humerus fixture also includes a

pulley to route a constant load on the biceps brachii tendon toward the proximal-medial side of the specimen. Notably, there is one pulley mounted on each side of the plate to account for left and right hands. Option two (Figure 4B): the humerus can be attached to the fixation plate through a top mounted piece that surrounds the distal diaphyseal and metaphyseal regions of the bone. This option is fully adjustable, but some pivoting about the top plate can occur if the bone is not seated against the wall of the humerus plate. The pivoting can be corrected by printing a taller top-mounted piece to encapsulate a greater portion of the diaphysis.



**Figure 4.** (A) Humerus fixation plate (ie, option one) allowing for fixation of the humerus to the plate through bolts. (B) Option two, allowing for adjustable fixation of the humerus through a top adjustable piece that surrounds the bone.

#### *Pulley System*

A series of pulleys are positioned at the back of the fixture, mounted to the rigid base plate (Figure 5). These pulleys divert an axial load applied to the specimen through a Y-weight distributor attached to free-hanging weights. The weights are hung from a cable tied through small holes on either side of the hand-rotation assembly so that the axial load is distributed across the hand-rotation assembly and onto the specimen.



**Figure 5.** Pulley system showing cables routed through Y-weight distributor for axial loading of the forearm.


### Motor-Control System

The motor-control system integrates with the hand-rotation assembly for rotational manipulation of the hand through a full range of pronation and supination angles. Revolution is transmitted through a belt-drive system, where a precision (stepper) motor (NEMA 17, US National Electrical Manufacturers Association, Arlington, Virginia) delivers accurate and repeatable rotations to achieve the targeted position. The device uses an Arduino Uno (Arduino, Ivrea, Italy) programmed to the desired interface through a physical controller.

The main device is housed in a compact assembly positioned on crossed linear rails for belt tightening (x) and for belt alignment with the moving hand-rotation assembly (y; Figure 6A). The device allows for control of the hardware from a distance (3.7-m [12-ft] cable), which enables personnel who are not assisting with the apparatus-end of the study to adjust the position of the forearm. For simplification, the controller includes an analog joystick to control all movement of the device and includes a liquid-crystal display (LCD) screen that displays the status of the forearm's position (Figure 6B). The user can increase or reduce speed of positioning when moving the joystick completely over in one direction (full speed) or only partially over (reduced speed) for a ramped approach. Pushing down on the analog stick returns the motor to its origin or neutral position. Computer code was written that rotates the motor clockwise (while holding the analog right) and counterclockwise (when holding it left). Instead of predesigned increments, the LCD displays the changing angle into both pronation and supination motions in real time and maintains the position until the user stops. The controller plugs into the circuit of the microcontroller and

powers both the LCD and analog stick.

Selecting the appropriate motor driver required understanding the device deliverables. Because speed nor force (except enough to exert rotation of the forearm) were critical factors, minimizing the size of the unit was considered along with available precision capabilities. The Mercury SM-4BYG011-25 stepper motor (Mercury Industry, China) with 11.5:1 gear ratio was chosen, effectively allowing 2.645 Nm of torque to be applied to the arm with angular resolution of  $0.0049^\circ$  per step. The control architecture includes an Arduino Uno microcontroller and a DRV8834 stepper motor driver (Pololu Corp, Las Vegas, NV). The selected motor driver allows *microstepping* of up to 1/32-step to allow improved angular resolution of 200 steps per revolution.



**Figure 6.** (A) Main motor positioned on crossed linear rails to allow for belt tensioning (x-direction) and alignment with the moveable hand rotation assembly (y-direction). (B) Remote motor controller for positioning of the hand at any angle of pronation or supination. It is connected to the main motor through a 3.7-m (12-ft) cable.

### Motion Capture System

The motion capture system is a high-resolution, optical camera tracking system (OptiTrack, NaturalPoint, Corvallis, OR). The system contains 12 cameras, six camera stands, six camera mounts, multiple infrared reflective markers, a control box, and a computer interface and processing system (Motive Software, OptiTrack, NaturalPoint, Corvallis, OR). The cameras are strategically placed in the testing area to capture all views of the rigid body markers placed on the specimen.

The specimen is tracked by seven sets of 3D-printed, ABS-rigid body markers: five located at various positions

of interest on the arm, one on the rigid base plate, one on the humerus plate, and one on the front plate of the hand-rotation assembly. Calibrations of the cameras involve establishing a capture volume of the testing area, establishing a ground plane of the testing surface, and defining the rigid body marker sets for accurate tracking. Using motion capture technology in cadaveric testing helps create 3D modeling of motions with sub-millimeter accuracy. This subsequently allows for capturing the motions of multiple bodies in real time.

### Validation Experiments

Overall, the main goal of the device is to deliver precise measurements of rotation, in a repeatable manner, without needing recalibration. To test the accuracy of the final design, calibrations were performed using three methods of angle measurement: a digital-angle gauge, the motion capture system, and the motor-control system (Figures 7A-7C and Figure 8). The digital-angle measurement was based on the tilt of the front 3D-printed nylon part of the hand-rotation assembly. The motion capture system gathered rotational information about the long axis of the specimen through the three retroreflective markers positioned on the front of the assembly. The motor-control system measured the angle of the hand-rotation assembly as defined by the user when positioning the joystick.

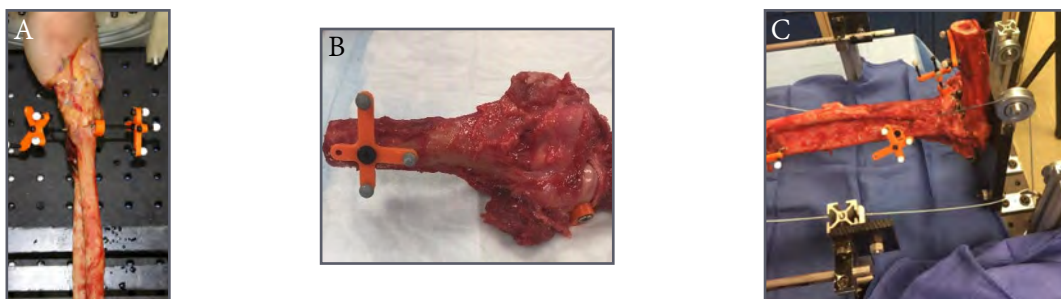
We used the specified rotation angle from the motor-control system as our baseline measurement. Output data

from the three measures are shown in Table 1. We found a 2.2% error between the motor-control system and the digital-angle gauge and a 6.0% error between the motion capture system and the digital-angle gauge. Notably, this calibration was completed without a hand positioned in the device. When a hand was inserted, we noted increased resistance on the drive belt, which may cause a greater difference in error between the motor control system and the angle gauge. To accommodate this increase in torque resistance, it may be possible to increase the current to the NEMA 17 motor or upgrade to a NEMA 23 motor.


**Table 1.** Output data showing a comparison of the OptiTrack motion capture hand rotation assembly marker data, motor-control system, and digital-angle gauge.<sup>a</sup>

Position	OptiTrack	Motor Control	Digital Angle Gauge
Neutral	0	0	0
Pronation	19.28	20	20.3
	38.75	40	42.6
	59.25	60	60.7
Neutral	0	0	0.7
Supination	17.36	20	19.8
	37.26	40	39.6
	57.94	60	58.6
Neutral	0	0	0.4

<sup>a</sup> Motor control was used as the baseline data from which to compare the other two systems.



**Figure 7.** Various images of the forearm, showing positioning of the retroreflective markers on the 3D printed rigid bodies. (A) Distal radius and ulna. (B) Fixed humerus. (C) Proximal radius and ulna.




**Figure 8.** A digital angle gauge positioned on the top surface of the rotating face plate used for validation of the motion capture and motor control systems.

In the passive configuration of this technology, the forearm rotated but only after rotations were applied to the hand. Owing to delays in carpometacarpal- and radiocarpal-load transmissions, there is a slight difference in angle between that of the hand and forearm. If the desired outcome is to examine these joints or interventions to these joints on upper-extremity motions, this device would be ideal in its current configuration. However, if the desire is to examine effects of intervention at the radio-humeral joint, distal or proximal radioulnar joint, or interosseous membrane, it may be preferable to apply active loads to the primary and secondary pronator and supinator tendons to produce pronation and supination motions of the forearm without lag effects caused by carpometacarpal or radiocarpal motions. With few modifications, the current technology can serve this purpose.

To change to an active control system, the baseplate, rail system, hand-rotation assembly, motion capture system, pulley system, and humerus plate would maintain their existing function. Only two modifications would be needed:

- 1) Isolation of the pronator teres, pronator quadratus (PQ), and supinator tendons (including the already isolated biceps brachii tendon) for active loading. Cable clamps can be attached to the tendons. Cables can be routed from the clamps through pulleys added to the baseplate, to apply direct loads to the tendons in the direction of their muscle pull. The secondary tendons (ie, PQ and supinator) can be loaded with constant weight corresponding to the desired load configuration method. For example, when pronation is desired, active tensile load can be applied to the pronator teres. A constant weight can be added to the PQ and supinator, with greater magnitude of weight on the PQ to simulate the force of muscle pull during pronation. The lighter weight on the supinator and biceps brachii simulates antagonistic muscle forces.

- 2) Remove the belt-drive system from around the hand-rotation assembly. This system could be placed proximal to the baseplate for applied loading. Alternatively, the system could be replaced with a linear-drive motor based on user preference. If the belt-drive system is maintained, the primary tendons (pronator teres and biceps brachii) could be coupled through their cable clamp systems. In this way, a desired rotation in pronation would result from an applied load to the pronator teres while the biceps brachii is unloaded. Similarly, a desired rotation in supination would result from an applied load to the biceps brachii while the pronator teres is unloaded. Figures 9A and 9B show an example of the active pronation and supination configuration possible with this technology.



**Figure 9.** (A) Example of the device in active pronation/supination configuration. Yellow arrows show line of action of pull of the pronator teres and biceps brachii tendons during loading. (B) Placement of the linear motor system proximal to the baseplate to apply loads to the tendons while keeping the motor and associated electronic hardware clean from the cadaver testing.

## Conclusion

When attempting to reproduce experimental results from other institutions, it is often difficult to achieve similar findings, partly because it is difficult to reproduce external testing methods. While technical details such as rate and direction of loading are often cited, most studies do not described details of their experimental setup.

This manuscript provides information on the development of a device to enable pronation and supination motions of a hand for use in cadaveric experimental studies. We provided a general overview of each component of the technology to enable an understanding of how each piece is essential to immobilizing the arm, controlling specific motions to simulate arm movement, and collecting the desired data outputs. This device may be used or adapted for use by institutions conducting similar research, so that the contributions to our field stem from an equivalent baseline of experimentation.

## Funding

The authors received no financial support for the research, authorship, and publication of this article.

## Conflict of Interest

The authors report no conflicts of interest.

# Pilot Study Investigating the Use of 3D Printing in Designing Upper-Extremity Prosthetics for Children: A Progress Report

Lauren Long, BS<sup>\*</sup>; Christina Salas, PhD<sup>\*\*‡</sup>; Deana M. Mercer, MD<sup>\*</sup>; Selina R. Silva, MD<sup>\*</sup>; Jared Knigge<sup>§</sup>

<sup>\*</sup>Department of Orthopaedics & Rehabilitation, The University of New Mexico Health Sciences Center, Albuquerque, New Mexico

<sup>†</sup>Department of Mechanical Engineering, The University of New Mexico, Albuquerque, New Mexico

<sup>‡</sup>Center for Biomedical Engineering, The University of New Mexico, Albuquerque, New Mexico

<sup>§</sup>Hope Christian School, Albuquerque, New Mexico

## Abstract

The availability and cost-effectiveness of functional prototypes and designs has increased considerably over the last decade because of 3D printing. The growing field of biomedical engineering is expanding on 3D-printing technology to make low-cost, upper-extremity prosthetics. This pilot study reports on the potential use of 3D printing for low-cost, upper-extremity prosthetics, specifically prosthetic hands for children. We start by characterizing existing open-source, 3D-printed upper-extremity prosthetics to determine their mechanical strength, statically and dynamically. Based on outcomes from these early tests, we optimize the existing designs to develop a new prosthetic. The prosthetic design, fabricated in The University of New Mexico Orthopaedic Biomechanics & Biomaterials Laboratory, will consist of 3D-printed parts optimized for function, adjustability, and cost effectiveness. The design will be clinically and mechanically tested to assure optimization of all outcome measures. Our goal is that the optimized 3D-printed, upper-extremity prosthetic can be used as an alternative option to the current available prosthetics, superior function, greater adjustability, and adequate strength, all at a lower cost.

## Introduction

The incidence of congenital limb deficiency is between 5% and 10% per 10,000 live births, with a 3:1 ratio of upper to lower limbs. There is also an increase in children sustaining injuries requiring amputation.<sup>1</sup> In New Mexico, more than 307,000 children from low-income families are covered through Medicaid and an additional 22,000 are uninsured.<sup>2</sup> Children in these categories are limited

by Medicaid guidelines for the type of prosthetic they can receive (usually non-functional or claw-type) and limited on the ability to receive a replacement of their prosthesis in the event of outgrowth, damage, loss, or theft. Furthermore, more than half of the non-elderly population of New Mexico resides in a rural part of the state without easy access to a prosthetic for refitting, replacement, or adjustments.<sup>3</sup> These statistics support the need for improved pediatric prosthetics that allow for hand functionality equivalent to that of expensive myoelectric prosthetics, at a price less than hook-type or purely cosmetic options.

Additionally, these prosthetics should allow for adjustability or low-cost replacement as the child grows. With the invention of 3D printing, the availability and cost-effectiveness of functional prototypes and designs has increased notably in the past decade. Its popularity has evolved from a simple rapid prototyping technology to a technology capable of serving as a fabrication tool for end-products. This evolution became possible as the cost of hardware and software decreased and as the potential for 3D-printed materials became more diverse. In the construction industry, 3D printing of cement has enabled low-cost housing options in developing countries.<sup>4</sup> In the automotive industry, 3D printing of carbon fiber filament has enabled fabrication of vehicle bodies and interior components.<sup>5</sup> In the medical field, 3D-printed biological materials enable advancements in tissue engineering.<sup>6</sup> More recently, 3D-printed prosthetic upper-extremity devices have been introduced as low-cost alternatives to traditional prosthetics.<sup>7</sup> Using open-source designs, an inexpensive 3D printer, and a few materials, individuals can create prosthetics in-house.

The application of 3D printing for prosthetic design





may have a considerable global impact. Currently available prosthetics for pediatric populations can be expensive and un-adaptable as the children grow. Purely cosmetic hands cost \$5000 on average.<sup>8</sup> Functional claw-type hands can average \$10,000. A low-cost, functional, myoelectric hand can start at \$20,000. These costs are problematic for families in low-income communities around the world, particularly when the child may outgrow the device at an accelerated pace. There is a crucial need for low-cost, adaptable, patient-specific, fully functional, and comfortable 3D-printed prosthetic hands for children.

Although designs of 3D-printed prosthetics are easily accessible from the internet, most have not been optimized for activities of daily living. None have been mechanically characterized to assess the feasibility of offering this option in a clinical setting. We report on the progress of our pilot study regarding potential use of 3D printing in creating upper-extremity prosthetics for children.

## Methods


The methods outlined were performed in The University of New Mexico Orthopaedic Biomechanics & Biomaterials Laboratory (UNM OBBL). The proposed pilot study has five aims. 1) We begin with a currently available, open-source 3D-printed hand known as the Cyborg Beast (e-NABLE) (Figure 1A).<sup>6</sup> We mechanically test this prosthetic to characterize each component's strength until failure (bulk material and joint locations). 2) Using data collected from aim 1, we modify the design of the existing prosthetic to optimize each component to withstand loads that may be introduced by young users. 3) The resulting design from aim 2 will be mechanically and clinically tested to prove feasibility for clinical use. 4) We will investigate modification of the Kyriakopoulos open-source design (Open Bionics, Bristol, United Kingdom) as a 3D-printed prosthetic option. This "hand" is currently made as a robotic manipulator for low-load manipulations by robotic arms. We wish to adapt this system as a prosthetic medical-device option. 5) Simultaneously, we will be investigating the Cyborg Beast and Kyriakopoulos systems for use with myoelectric interfaces to enable electronic actuation.

## Progress

The pilot study introduced in this article was recently initiated. This section provides a brief description of the progress made toward each of the five aims.

### *Aim 1: Mechanical Testing of Cyborg Beast*

The Cyborg Beast was printed in our laboratory (Figure 1B) using an Ultimaker 2+ Extended 3D printer (Ultimaker North America, Cambridge, MD). All 3D-printed parts were made from acrylonitrile-butadiene-styrene (ABS) polymer filament and joined together with aluminum bolts and nuts as suggested by e-NABLE. The cables, which are meant to simulate tendon loading on the fingers, were made from high tensile-strength fishing wire and high-strength suture. The finger attachments, gauntlet, palm, and pin connections are being tested in a uniaxial tensile loading condition to evaluate failure strength (Figure 2). Components will be loaded at a rate of 1 mm/s until failure, defined as the point of yield on the stress-strain curve. The whole hand will also be tested under cyclic loading conditions to simulate long-term use.



**Figure 1.** (A) 3D-printed Cyborg Beast prosthetic hand by e-NABLE, printed in our laboratory. (B) Cyborg Beast during printing with the Ultimaker 2+ Extended printer using blue acrylonitrile-butadiene-styrene polymer.



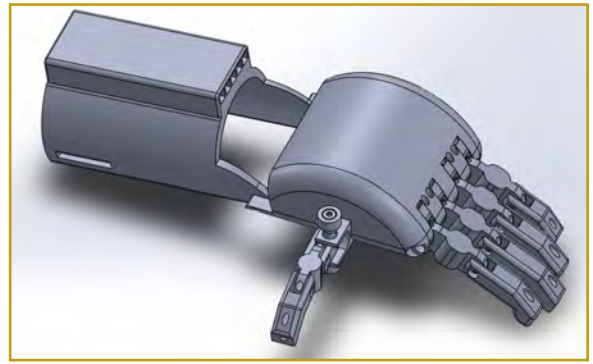
**Figure 2.** 3D-printed distal phalange undergoing uniaxial tensile testing to evaluate failure strength at the proximal interphalangeal joint of the prosthetic.

### *Aim 2: Optimization of the Cyborg Beast Model*

Although the mechanical testing is underway, some areas of improvement have been discussed with clinicians. We have begun implementing the suggestions in the new design: “tendon” cable-system protection and thumb reposition.

The cable system lies over the top of the prosthetic device and is susceptible to early failure owing to wear induced by sharp edges. We have replaced the fishing wire and suture with flexible braided Kevlar to minimize the potential for cable failure. Additionally, the exposed cables are seen as a likely area for failure or loosening if acted upon by an external force. The first iteration of re-design includes a housing over the top surface of the prosthetic to protect the cables from external factors. The current design can be seen in Figure 3.

The thumb position in the Cyborg Beast model is at a fixed angle (about 80°) relative to the fingers. This is likely to allow for the thumb to perform an opposition function where it should cross over the palm of the hand. In a human hand, the carpometacarpal joint of the thumb is shaped like a saddle, which allows opposition at a variety of angles. Additionally, the average resting position of the thumb is about 45° from the fingers to allow for pinching and gripping activities. In the first iteration of the re-design, we implemented a feature that would allow for manual positioning of the angle of the thumb relative to the fingers (Figure 3). Further iterations of the re-design will focus on reducing stress concentrations and reinforcing weak areas in the prosthetic.




**Figure 3.** First iteration of the Cyborg Beast re-design, which protects the exposed “tendon” cables from early failure. Notably, there is a greater level of coverage of the cables as compared to Figure 1. Additionally, the thumb is modified to allow for manual repositioning of the angle of the thumb relative to the fingers to allow for better opposition as preferred by the user.

### *Aim 3: Mechanical Testing of Optimized Cyborg Beast Model*

Because optimization of the Cyborg Beast model has not yet been completed, we have not started mechanical testing of this model. The hand will undergo joint failure testing, cyclic loading of the entire prosthetic, and component load to failure testing. If mechanical testing of the optimized model does not show improvement or shows little improvement from the original, additional modifications will be completed and testing will continue in an iterative fashion.

### *Aim 4: Kyriakopoulos Open-Source to 3D Printed Prosthetic*


The open-source Kyriakopoulos model has been 3D printed and assembled based on the computer aided-design outlined on the OpenBionics.org website (Figures 4A and 4B). This open-source design includes a whiffle tree configuration within the palm to allow for sharing of forces between finger cables and the use of only one motor for finger actuation. This aspect is optimal for reduction of cost and ideal for incorporation into the design created in aim 2. The open-source design also includes an elegant design of the thumb mechanism, which allows for 144 hand positions. The thumb mechanism will be incorporated into the design in aim 2. Lastly, the hand will be modified such that 1) the prosthetic can be coupled to a forearm cuff for situations in which the residual limb does not include the radial carpal joint and 2) the palm of the device will allow for carpals and partial finger placement for situations in which the residual limb includes the radial carpal joint.



**Figure 4.** (A) 3D-printed components of the Kyriakopoulos Open-Source hand model. (B) Fully assembled Kyriakopoulos model for preliminary analysis.

### Aim 5: Myoelectric Interface

We chose to investigate the use of the MyoWare™ electromyography (EMG) sensor (AT-04-001, Advanced Technologies, Merrimack, New Hampshire) for actuation of the modified Cyborg Beast and Kyriakopoulos prosthetic models. The MyoWare sensor is powered and controlled by an Arduino MEGA microcontroller (Arduino, New York, New York) and snaps directly to electrodes that are adhered to the skin above the muscle from which signal will be obtained (Figure 5). Raw EMG data signals processed with Arduino code will allow for the user to trigger the motor that controls finger and thumb actuation. The MyoWare system is compact and can be easily incorporated into the designs created in aims 2 and 4.



**Figure 5.** Myoware sensor attached to an arm and connected to an Arduino MEGA microcontroller.

### Future Goals

Once we have completed aims 1 through 5, we will proceed with an investigative study to evaluate comfort, adaptability, dexterity, and wear of the prosthetic with children participants. Clinical testing will commence only after approval by our institutional review board. In this study, a mold of the residual limb of the patient will be created during a visit with a physician. The inner surface of the mold will be scanned using a NextEngine 3D scanner (NextEngine, Santa Monica, CA) to serve as a negative

mold for creation of the prosthetic. We will combine the negative mold with an existing model of the prosthetic, such that the final design will perfectly contour the residual limb of the patient. The patient will be asked to wear the device and perform a series of simple tasks with parental or guardian supervision. Qualitative and quantitative outcome measures such as comfort, adaptability, strength, and dexterity will be obtained from these tasks.

### Discussion

The current prosthetic designs available on the market range from hooks to robotically actuated prosthetics.<sup>7-11</sup> Regardless of prosthetic type, the cost of the device is high. These prices can become burdensome for parents of children who replace their prosthetic because of growth or damage during activities of daily living. Although open-source 3D-printed prosthetic designs have recently become available and notably help reduce cost, none of these current options have been mechanically tested to ensure functionality during normal use. Additionally, these models have not been evaluated to ensure physiologic motions similar to that of the native hand. We hypothesize that the modified designs created in our laboratory will allow for a low-cost, patient-specific, and mechanically robust prosthetic with functionality similar to that of the native hand.

Using 3D printing as a manufacturing technique to this end, reduces cost of customization, creation of new designs, and reproduction of the prosthetic when compared to traditional manufacturing. It also allows for the prosthetic to be easily reproduced in a larger size as the child grows. This allows for the parents to purchase a new prosthetic as their child grows, equivalent to the cost of filling up a car with gas. Another advantage is that it reduces casting, molding, and manufacturing times and processes when compared to those of traditional prosthetics because an exact fit can be obtained from computed tomography or magnetic resonance imaging scans of the residual limb. The exact fit also allows for continued adjustment over multiple iterations of the prosthetic as the child grows and replaces the prosthetic. Furthermore, it allows for stability and improved functionality of the prosthetic.

It is widely known that upper-extremity prosthetics tend to be relegated to a drawer and not used by patients owing to prosthetic complexity and lack of functionality. We pursue this research effort to create a simple, functional prosthetic for use by children. The prosthetic will be lighter, easy to use, less-expensive, and more functional to use compared to traditional prosthetic devices.

## Funding

The authors were awarded a grant from the Carrie Tingley Hospital Foundation.

## Conflict of Interest

The authors report no conflicts of interest.

## References

1. Talwalkar VR. Pediatric prosthetics. *Current Opinion in Orthopaedics*. 2006;17(6):517-520. doi:10.1097/01.bco.0000247362.74750.32.
2. Medicaid facts of New Mexico [patient brochure]. American Academy of Pediatrics; January 1, 2017. [https://www.aap.org/en-us/Documents/federaladvocacy\\_medicaidfactsheet\\_newmexico.pdf](https://www.aap.org/en-us/Documents/federaladvocacy_medicaidfactsheet_newmexico.pdf). Accessed July 24, 2017.
3. Apis Cor. Apis Cor website. <http://apis-cor.com/en/>. Accessed June 7, 2017.
4. LM. Local Motors website. <https://localmotors.com>. Accessed June 7, 2017.
5. Organovo. Organovo Holdings Inc website. <http://organovo.com/science-technology/bioprinted-human-tissue/>. Accessed June 7, 2017.
6. Home G, Us C, Sitemap. Enabling the Future website. <http://enablingthefuture.org/>. Accessed February 24, 2017.
7. CostHelper Health. How much does a prosthetic arm cost? <http://health.costhelper.com/prosthetic-arms.html>. Accessed June 22, 2017.
8. Williams MR, Walter W. Development of a prototype over-actuated biomimetic prosthetic hand. *PLoS One* 2015;10(3):e0118817. doi:10.1371/journal.pone.0118817.
9. Kontoudis GP, Liarakapis MV, Zisimatos AG, Mavrogiannis CI, Kyriakopoulos KJ. Open-source, anthropomorphic, underactuated robot hands with a selectively lockable differential mechanism: towards affordable prostheses. Paper presented at: 2015 IEEE/RSJ International Conference on Intelligent Robots and Systems (IROS); September 28-October 2, 2015; Hamburg, Germany.
10. Smit G, Plettenburg DH. Efficiency of voluntary closing hand and hook prostheses. *Prosthet Orthot Int* 2010;34(4):411-27. doi:10.3109/03093646.2010.486390.
11. Zuniga JM, Peck J, Srivastava R, Katsavelis D, Carson A. An open source 3D-printed transitional hand prosthesis for children. *J Prosthet Orthot* 2016;28(3):103-8. doi:10.1097/jpo.000000000000097.

# Missed Early Glenohumeral Septic Arthritis During Emergency Department Visit Owing to Low Virulence *Streptococcus Mitis*: A Case Report

Ashley A. Crum, MD<sup>\*</sup>; Christopher A. McGrew, MD<sup>†‡</sup>; Matthew A. Tennison, MD<sup>\*</sup>

<sup>\*</sup>Department of Emergency Medicine, The University of New Mexico Health Sciences Center, Albuquerque, New Mexico

<sup>†</sup>Department of Orthopaedics & Rehabilitation, The University of New Mexico Health Sciences Center, Albuquerque, New Mexico

<sup>‡</sup>Department of Family & Community Medicine, The University of New Mexico Health Sciences Center, Albuquerque, New Mexico

## Abstract

Glenohumeral joint septic arthritis in a native joint is uncommon but can be debilitating if not treated early. Septic arthritis does not always present with the typical clinical findings, especially in immunocompromised patients. We report a rare case of glenohumeral septic arthritis from *Streptococcus mitis* infection in a diabetic woman that was initially missed on first presentation in the emergency department (ED). The exact cause of infection in this case remains unclear but is likely due to poor dentition and possible transient bacteremia in the setting of large rotator cuff tear in an immunocompromised patient (diabetes). The patient had a good outcome after returning to the ED three days later and undergoing shoulder arthroscopy, irrigation, and initiation of intravenous antibiotics. It is important to keep a high clinical suspicion for septic arthritis in immunocompromised patients with atraumatic shoulder pain.

## Introduction

Atraumatic shoulder pain with limited range of motion has many causes. A high index of suspicion should be maintained to avoid missing critical diagnoses such as infection. Although glenohumeral joint septic arthritis in a native joint is uncommon, occurring in 10% to 15% of septic arthritis cases, it can be debilitating if not treated early due to bone and cartilage destruction, osteonecrosis and secondary arthritis.<sup>1</sup> An atypical presentation of septic arthritis can prolong the time to diagnosis. One

case report<sup>2</sup> described an atypical presentation of septic glenohumeral arthritis in a patient with diabetes mellitus and liver cirrhosis. The patient had 2 months of limited range of motion and stiffness, with no known trauma. She was found to have Methicillin-resistant *Staphylococcus aureus* after joint aspiration, and findings of severe inflammation, fibrinous changes, and erosion of the joint on arthroscopic lavage. Septic arthritis of the glenohumeral joint can mimic other causes of shoulder pain and can occur in pathological features of concomitant rotator cuff tear.

We report a rare case of glenohumeral septic arthritis from *Streptococcus mitis* infection in a 52-year-old woman, in which the diagnosis was missed on initial presentation to the emergency department. To our knowledge, this is the second case report of septic arthritis in the glenohumeral joint from this bacteria.<sup>1</sup> Given the numerous potential causes of shoulder pain and limited range of motion in a middle-aged adult, it is important to keep septic arthritis high in the differential and look for sources of infection on initial evaluation. The patient was informed that the data concerning the case would be submitted for publication, and she provided verbal consent.

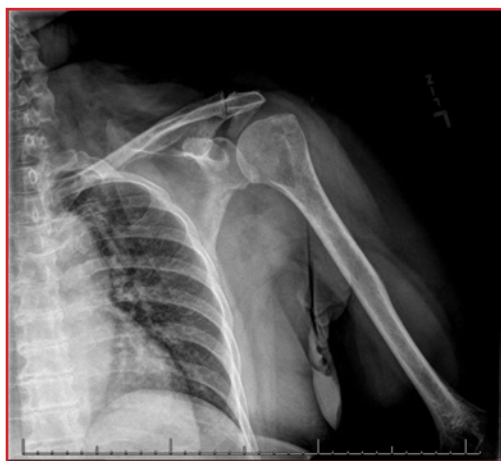## Case Report

A 52-year-old woman with hypertension, diabetes mellitus, and severe anxiety presented to the emergency department with acute onset left shoulder pain. She woke up in the morning on the day of presentation, with severe pain throughout her shoulder described as sharp, radiating

throughout her arm, made worse with movement, and had severely limited range of motion. She did not report any previous injury to the shoulder and never had any pain or loss of range of motion in the past requiring evaluation. She had no fevers or chills. The use of nonsteroidal anti-inflammatory drugs slightly alleviated her pain.

On physical examination, the patient had a blood pressure of 142/73 mm HG, afebrile at 36.9° C, and heart rate of 86 beats per minute. Examination of her left shoulder indicated no deformity or swelling but tenderness to palpation throughout the anterior and posterior aspects. Her range of motion was limited, with flexion and abduction less than 90°, inability to extend or internally rotate because of pain, and painful active and passive external rotation limited to 45°. Results of strength tests (eg, rotator-cuff tests on the supraspinatus and provocative biceps tests such as the Speed and labral tests with active compression) were notably limited owing to pain. Findings of her neurovascular examination were otherwise normal.

A radiograph of the left shoulder was obtained and revealed a large subacromial spur with moderate/severe degenerative changes of the left acromioclavicular joint (Figure 1). Laboratory studies showed the following values: white blood cell count, 8000/mL (nl range 4000-11000 ml); C-reactive protein, 2.1 mg/L (nl <0.3mg/dL); erythrocyte sedimentation rate, 5 mm/hour normal range 0-33mm/hr); glucose, 211 mg/dL; and normal values of other electrolytes and delta troponin. The differential diagnosis at this point included adhesive capsulitis, rotator-cuff disease, infection of muscle or joint, or other non-musculoskeletal cause such as cardiac problems or neck/cervical spine pain.



**Figure 1.** Radiograph of the left shoulder at initial presentation, showing anteroposterior view in external rotation.

An anterior approach glenohumeral intra-articular injection with 5mL of 1% plain lidocaine was performed in the emergency department; the injection resulted in reduced pain. Corticosteroid was not used owing to

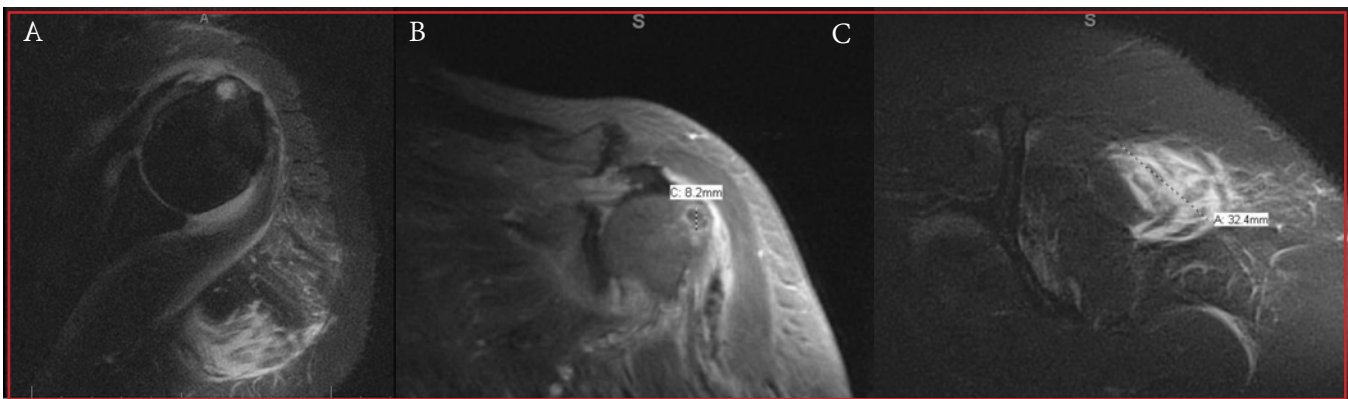
unclear cause of pain. The patient was given a prescription for ibuprofen, an outpatient referral for a shoulder magnetic resonance imaging (MRI), and follow-up with an orthopaedic sports-medicine physician upon discharge. Orthopaedic physicians were not consulted during the emergency department visit.

The patient returned to the emergency department 3 days later with persistent left shoulder pain and new onset symptoms of swelling and subjective fever. She was tachycardic at 103 beats per minute, afebrile in the emergency department (temperature 36.7° C), and had severe tenderness to palpation of the entire left upper extremity, with ongoing limited range of motion. Laboratory studies were repeated, and the patient was found to have leukocytosis with a white blood cell count (13700/mL, or  $13.7 \times 10^9/L$ , nl range 4000-11000 ml). Additionally, C-reactive protein level was 26.9 mg/dL (26.9 nmol/L, nl <0.3mg/dL) and erythrocyte sedimentation rate was 81 mm/hour (normal range 0-33mm/hr).

Orthopaedic physicians were consulted and recommended an MRI, revealing a 3.2-cm area of high signal in the posterior deltoid, indicating the presence of abscess rather than myonecrosis. The MRI also showed a full-thickness tear of the supraspinatus and portions of the infraspinatus, with fatty atrophy, retraction, and moderate joint effusion without evidence of osteomyelitis (Figures 2A through 2C). The physicians elected not to perform a joint aspiration immediately owing to possible overlying myonecrosis, but the patient was started on broad spectrum antibiotics vancomycin and ceftriaxone and admitted. An aspiration was performed the next morning and synovial fluid showed a total nucleated cell count of 92,800  $mm^3$ , at which point the patient was taken to the operating room for treatment of a septic left glenohumeral joint with left shoulder arthrotomy and irrigation. The synovial fluid and tissue culture grew *Streptococcus mitis*. There were no notable cartilage lesions or erosions.

The source of infection was evaluated during the patient's hospital stay, with two blood cultures performed before antibiotic administration. Results of the blood cultures indicated no growth of the bacteria. Findings of a panoramic dental scan showed no apical lucencies but revealed multiple missing teeth. Findings of a transthoracic echocardiogram were normal. At 5 days postoperatively, the patient was discharged from the hospital.

The patient completed 6 weeks of intravenous ceftriaxone based upon a recommendation from the infectious disease service, with a course of physical therapy and did not receive any oral antibiotics. ESR and CRP were normal 2 months later. Complete resolution of symptoms was noted at 4 months postoperatively with no



**Figure 2.** (A) Magnetic resonance imaging of the left shoulder in axial view, with short-TI inversion recovery blade sequence, showing a high signal in posterior deltoid and glenohumeral joint effusion. (B) Magnetic resonance imaging of the left shoulder in paracoronal view, with T1 spin-echo sequences after water-fat shift, showing cystic changes of the humeral head near supraspinatus insertion. (C) Magnetic resonance imaging of the left shoulder in parasagittal view, with short-TI inversion recovery blade sequence, showing a 3.2-cm area of high signal in the posterior deltoid.

residual pain or weakness. She was counseled on the risk of developing osteoarthritis of the glenohumeral joint.

## Discussion

Septic arthritis typically presents as a hot, swollen, tender joint or joints, with a reduced range of motion and pain with axial loading. Symptoms are usually present for less than 2 weeks at presentation, but considerable delays may occur, particularly with low virulence organisms, tuberculosis, and prosthesis infection.<sup>3</sup> In the case presented above, the patient had reduced range of motion and a tender joint with symptoms present for less than 2 weeks. There was no obvious swelling or warmth to the joint on initial evaluation. Infection was a consideration at initial presentation to the emergency department, with evaluation of serum white blood count, C-reactive protein, erythrocyte sedimentation rate, and vital signs. No abnormal findings were noted, except slight elevation of C-reactive protein levels.

Margaretten et al<sup>4</sup> reviewed the use of these serum markers in clinical studies. The authors noted a limited diagnostic accuracy of septic arthritis when assessing abnormal findings in peripheral white blood cell count, erythrocyte sedimentation rate, and C-reactive protein; this limitation was mainly a result of the low specificity of laboratory values. One prospective study included 75 patients who presented with a white blood cell count of more than 10,000/mL ( $10 \times 10^9/L$ ), which minimally increased the likelihood of septic arthritis. The study showed that an erythrocyte sedimentation rate of more than 30 mm/hour minimally increased the likelihood of septic arthritis.<sup>4,5</sup> Similarly, a retrospective case-control series found that a markedly elevated C-reactive protein of more than 100 mg/L (952.4 nmol/L) increased the

likelihood of septic arthritis slightly.<sup>4,6</sup>

All of these studies<sup>4-6</sup> concluded that serum tests were not sufficient to predict septic arthritis, although none commented on whether combination of these laboratory values increased likelihood of the condition. The studies agreed that synovial fluid analysis of total nucleated cell and percentage polymorphonuclear cells had the highest predictive value in diagnosis of septic arthritis while waiting for gram stain and culture results. The patient had a low virulent strain of bacteria in *Streptococcus mitis*, which is a gram-positive coccus, anaerobe subgroup of *Streptococcus viridians*, belonging to normal flora residing predominantly on the surface of teeth. *Streptococcus viridians* is known for its ability to colonize heart valves but is rarely associated with septic arthritis. In the only other case report<sup>1</sup> on *Streptococcus mitis* causing glenohumeral septic arthritis, no chondral injury was reported and the patient healed successfully after treatment. In the current case, this low virulence bacteria may have contributed to the lack of early systemic symptoms at initial presentation.

Another consideration on the initial presentation to the emergency department could have been to evaluate for joint effusion. Although the radiograph of the shoulder did not show signs of a large effusion, there was no ultrasound or MRI performed on initial presentation. Effusion can be less evident on physical examination of a shoulder compared to other joints such as that of the knee. Had a more thorough investigation for joint effusion and aspiration been pursued on initial presentation an earlier diagnosis may have been made. Synovial white blood cell counts are another way to evaluate for septic arthritis. Progressively higher synovial white blood cell counts increase the likelihood of septic arthritis.<sup>4</sup> White blood cell counts greater than 25,000/mL ( $25 \times 10^9/L$ ) show a likelihood ratio of 2.9, synovial white blood cell counts

greater than 50000/mL ( $50 \times 10^9/L$ ) show a likelihood ratio of 7.7, and synovial white blood cell counts greater than 100,000/mL ( $100 \times 10^9/L$ ) show a likelihood ratio of 28.

Risk factors for development of joint sepsis include: rheumatoid arthritis or osteoarthritis, prosthetic joints, low socioeconomic status, intravenous drug abuse, alcoholism, diabetes mellitus, previous intra-articular corticosteroid injection, and cutaneous ulcers.<sup>3</sup> The patient in this case had diabetes. Additionally, several teeth were missing owing to poor dentition. Although she had not had a recent dental procedure, studies have indicated that most causes of septic arthritis are the result of direct inoculation from trauma or bacteremia.<sup>1</sup> We found a massive rotator-cuff tear in our patient, with fatty atrophy and involvement of the glenohumeral joint during arthrotomy. No related symptoms were evident, with no known trauma in the past. It is important to keep a high clinical suspicion of septic arthritis in immunocompromised patients with atraumatic shoulder pain. Systemic and serum markers are not specific enough in many cases for accurate diagnosis. Further imaging and synovial aspiration can greatly contribute to diagnosing this disease that can cause significant morbidity if not treated promptly.

## Funding

The authors received no financial support for the research, authorship, and publication of this article.

## Conflict of Interest

The authors report no conflicts of interest.

## References

1. Feder OI, Gruson KI. Glenohumeral joint sepsis caused by streptococcus mitis: a case report. *Am J Orthop (Belle Mead NJ)* 2016;45(6):E343-E346.
2. Sambandam SN, Atturu M. A case of septic arthritis of shoulder presenting as stiffness of the shoulder. *J Orthop Case Rep* 2016;6(2):31-33.
- 3 Mathews CJ, Kingsley G, Field M, et al. Management of septic arthritis: a systematic review. *Ann Rheum Dis* 2007;66(4):440-5.
4. Margaretten ME, Kohlwes J, Moore D, Bent S. Does this adult patient have septic arthritis? *JAMA* 2007;297(13):1478-88.
5. Jeng GW, Wang CR, Liu ST, et al. Measurement of synovial tumor necrosis factor-alpha in diagnosing emergency patients with bacterial arthritis. *Am J Emerg Med* 1997;15(7):626-9.

6. Söderquist B, Jones I, Fredlund H, Vikerfors T. Bacterial or crystal-associated arthritis? Discriminating ability of serum inflammatory markers. *Scand J Infect Dis* 1998;30(6):591-6.



# Carpal Tunnel Release During Pregnancy: Report of Two Cases

Erica J. Gauger, MD; Deana M. Mercer, MD; Moheb S. Moneim, MD

Department of Orthopaedics & Rehabilitation, The University of New Mexico Health Sciences Center, Albuquerque, New Mexico

## Abstract

Symptoms of carpal tunnel syndrome are common occurrences during pregnancy, particularly in the third trimester. Most patients undergo successful nonoperative treatment shortly after birth or the cessation of breast feeding. However, symptoms noted earlier during pregnancy are more likely to be severe and persistent. We present the cases of two women who developed symptoms of severe carpal tunnel syndrome during the second trimester and did not improve with nonoperative measures. Both underwent carpal tunnel release during pregnancy, with excellent postoperative result. Obstetric providers and surgeons alike should consider surgical treatment for patients with carpal tunnel syndrome who do not improve after nonoperative methods.

## Introduction

Carpal tunnel syndrome has long been associated with pregnancy, with incidence reported as high as 62% among pregnant women.<sup>1</sup> There are several purported reasons for this high incidence, although the true cause remains unknown and is likely multifactorial. Blood volume can increase 30% to 50% with a single pregnancy, and various hormonal causes of increased fluid retention and hyperemia contribute to generalized edema, which is theorized to cause swelling within the carpal tunnel, leading to symptoms of median nerve compression.<sup>2</sup>

Symptoms of carpal tunnel syndrome often present in the third trimester and are believed to resolve shortly after childbirth.<sup>2</sup> However, symptoms can occur as early as the first trimester and progress more quickly than idiopathic carpal tunnel syndrome regardless of severity.<sup>3</sup> Furthermore, up to 50% of cases persist after childbirth.<sup>4</sup> Nonoperative management with splinting, injections, and supportive care is usually standard treatment before childbirth<sup>5</sup>; however, when these methods fail to provide adequate symptom relief, surgical release of the carpal tunnel should be considered.

We describe two women in their first pregnancy with symptoms of carpal tunnel syndrome that started during the second trimester and did not improve with nonoperative treatment. Both underwent carpal tunnel release during pregnancy. The patients were informed that the data concerning the case would be submitted for publication, and they provided verbal consent.

## Case Reports

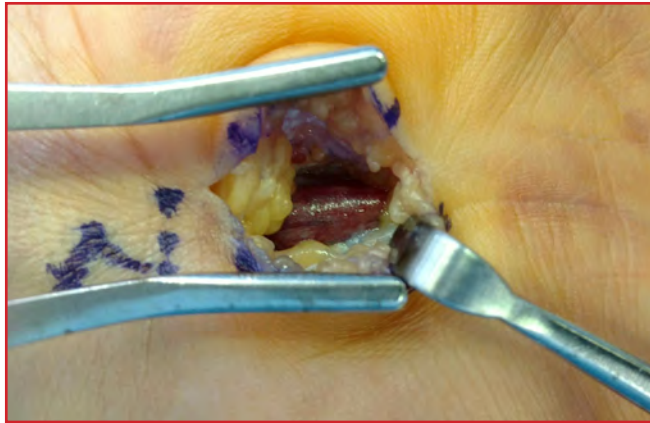### Case 1

A 35-year-old, right-hand dominant woman, employed as a registered nurse, was referred to our hand clinic with symptoms of bilateral hand pain and numbness. She was in the seventh month of pregnancy with her first child and had been having symptoms for 2 months. More symptoms were noted in her right hand than left. The numbness involved the thumb and index fingers and occasionally the ring finger. She had tried using night splints with minimal relief and routinely woke up with numbness and tingling in her hand. No history of diabetes or thyroid disorders was reported. She had no other notable medical history and never had symptoms of carpal tunnel syndrome.

At presentation, a body mass index (BMI, kg/m<sup>2</sup>) of 33.14 was recorded. Results of the Phalen and carpal-compression tests were positive for both hands. Two-point discrimination was 5 mm in all digits. No thenar atrophy or appreciable weakness of the abductor pollicis brevis was noted. The patient had full range of motion of the wrist and all digits. Clinically, a diagnosis of bilateral carpal tunnel syndrome was made.

The patient was subsequently referred for electrodiagnostic studies. Results of which showed a median-motor latency of 8.5 ms on the right hand and 5.9 ms on the left. Sensory latency in the median nerve was nonrecordable on the right and 3.6 ms on the left hand. Results of electromyography revealed positive sharp waves and increased insertional activity in the abductor pollicis brevis on the right hand. The patient was offered and underwent corticosteroid injection, which

did not improve her symptoms. After she returned from a visit with her obstetrician, open carpal tunnel release was performed, with short acting axillary regional block through a limited palmar incision. Intraoperative findings included a large palmaris brevis overlying the transverse carpal ligament, with aberrant sensory nerve branch and considerable hyperemia of the median nerve (Figure 1). At 2 weeks postoperatively, she had complete resolution of her symptoms. The patient elected to postpone operative treatment of the left hand until after childbirth.



**Figure 1.** Intraoperative photograph of the right hand in case 1, revealing severe hyperemia of the median nerve after complete release of the transverse carpal ligament.

### Case 2

A 40-year-old, right-hand dominant woman presented during the eighteenth week of her first pregnancy, with symptoms of severe right-hand numbness, tingling, burning pain, and loss of dexterity. She was an intensive-care physician and had difficulty with work owing to the severity of symptoms. Comorbidities included type 2 diabetes mellitus, which worsened with pregnancy and required insulin; hypertension; depression; and antiphospholipid antibody syndrome. At presentation, the patient was taking labetalol, long and short acting insulin, metformin and lovenox. She did not smoke.

At presentation, a BMI of 33.9 was recorded. Examination results of the right hand showed 4-of-5 motor strength in the abductor pollicis muscle, decreased sensation to light touch in the median nerve distribution, and positive provocative maneuvers for carpal tunnel syndrome. She was subsequently referred for electrodiagnostic studies which revealed a right median motor distal latency of 4.4 ms and distal sensory latency of 3.3 ms. Results of electromyography showed reduced recruitment with increased amplitude and duration on volitional Motor Unit Action Potentials in the abductor pollicis brevis.

Her case was discussed with her obstetric provider, and the decision was made to proceed with operative intervention owing to the severity of her symptoms. No injections were performed. The patient underwent open carpal tunnel release to treat her right hand at 20 weeks' gestation. Intraoperatively, she was noted to have a very thickened transverse carpal ligament, with hyperemia and fibrosis of the median nerve. No operative or postoperative complications were noted. At 2 weeks postoperatively, her pain had resolved. Mild numbness was noted at the tip of her right index finger, which resolved at 6 weeks postoperatively. She developed symptoms of mild carpal tunnel syndrome on the left hand, which were treated successfully with bracing and did not require surgical intervention.

### Discussion

The incidence of pregnancy-related carpal tunnel syndrome has varied reports, from 0.8% to 70% noted.<sup>6</sup> The most common symptom is numbness, followed by pain.<sup>1</sup> In fact, patients with pregnancy-related carpal tunnel syndrome may have more severe symptoms than those with idiopathic carpal tunnel syndrome.<sup>4</sup> Nocturnal symptoms are common, and involvement is often found in both hands.<sup>2,3</sup> Results of electrodiagnostic studies can help determine severity of nerve compression and identify treatment methods. Patients with sensory and motor changes are more likely to undergo operative treatment.<sup>5</sup>

Potential reasons for the regular occurrence of pregnancy-related carpal tunnel syndrome include hypersensitivity of the nerve owing to pregnancy, which results in a double-crush phenomenon; generalized edema resulting from fluid retention and increased blood volume; tenosynovitis of the flexor tendons; and endocrine adaptations in glucose metabolism.<sup>2</sup> However, the true cause may be multifactorial and remains unclear. Patients with hand swelling that prevents use of rings have increased incidence of carpal tunnel syndrome.<sup>7</sup> Yet the amount of weight gain during pregnancy has not been correlated with the development of symptoms.<sup>1</sup>

In general, treatment has consisted of nonoperative measures during pregnancy because symptoms usually abate after delivery.<sup>2</sup> However, symptoms may not always resolve quickly after childbirth. At 3 years after child birth, up to 30% of women may have residual symptoms.<sup>6</sup> Symptom resolution can be prolonged while breast feeding.<sup>5</sup> Regardless, the number of cases involving operative treatment during pregnancy remains low. We reviewed all carpal tunnel release procedures performed at our institution from January 2014 to November 2016, during which 891 procedures were performed and only

two involved pregnant women (reported in the current study). Furthermore, about 82% of pregnant patients have successful relief of symptoms with use of nighttime splints.<sup>5</sup> Use of corticosteroid injections is effective particularly when treating mild to moderate symptoms, without adverse effect on the fetus.<sup>2</sup>

The issue, therefore, is identifying patients who should be offered treatment with carpal tunnel release during pregnancy. Although nonoperative measures should be used first, not all women experience resolution of symptoms. Women who develop symptoms during the first and second trimesters of pregnancy have been described as less likely to improve after undergoing nonoperative treatment.<sup>2,5,8</sup> The clinical practice guidelines of the American Academy of Orthopedic Surgeons do not offer specific recommendations for treating pregnancy-related carpal tunnel syndrome, except to suggest surgery if conservative treatment fail. Overall, a success rate of 98% has been reported with operative treatment in the general population.<sup>2</sup>

In case 1 of the current study, the cause of the symptoms was likely the ischemia of the nerve resulting from increased pressure in the carpal tunnel, owing to the notable amount of hyperemia and nerve swelling found after release of the transverse carpal ligament. Similarly, results of case 2 confirmed median nerve compression localized to the carpal tunnel, with changes in the abductor pollicis brevis muscle. Resolution of symptoms after carpal tunnel release was noted for both cases, and neither patient experienced pregnancy-related complications as a result of the surgery.

Furthermore, both women had a BMI of 33 at presentation, which may indicate the degree of weight gain or edema experienced during pregnancy. Unfortunately, BMI information was not available before pregnancy for either woman. Increased edema, although not necessarily increased weight gain, has been associated with increased incidence of carpal tunnel syndrome.<sup>5,8,9</sup> Similarly, older women have been shown to have increased incidence of carpal tunnel syndrome during pregnancy, and both of our patients were classified as advanced-maternal ages at 35 and 40 years.<sup>7</sup>

Additionally, both patients had motor changes affecting the thenar musculature. This likely indicates the severity of nerve compression and may suggest the need for earlier operative intervention. Perhaps the most predictive indicator of operative intervention in both patients was the presence of symptoms in the second rather than third trimester of pregnancy.<sup>2</sup>

Results of further prospective studies would help determine the natural history of pregnancy-related carpal tunnel syndrome. Additionally, the findings may

illuminate which patients can be treated successfully with nonoperative or operative methods.

## Funding

The authors received no financial support for the research, authorship, or publication of this article.

## Conflict of Interest

The authors report no conflicts of interest.

## References

1. Padua L, Aprile I, Caliandro P, et al; Italian Carpal Tunnel Syndrome Study Group. Symptoms and neurophysiological picture of carpal tunnel syndrome in pregnancy. *Clin Neurophysiol* 2001;112(10):1946-51.
2. Osterman M, Ilyas AM, Matzon JL. Carpal tunnel syndrome in pregnancy. *Orthop Clin North Am* 2012;43(4):515-20. doi: 10.1016/j.ocl.2012.07.020.
3. Mondelli M, Rossi S, Monti E, et al. Prospective study of positive factors for improvement of carpal tunnel syndrome in pregnant women. *Muscle Nerve* 2007;36(6):778-83.
4. Seror P. Pregnancy-related carpal tunnel syndrome. *J Hand Surg Br* 1998;23(1):98-101.
5. Stahl S, Blumenfeld Z, Yarnitsky D. Carpal tunnel syndrome in pregnancy: indications for early surgery. *J Neurol Sci* 1996;136(1-2):182-4.
6. Padua L, Di Pasquale A, Pazzaglia C, Liotta GA, Librante A, Mondelli M. Systematic review of pregnancy-related carpal tunnel syndrome. *Muscle Nerve* 2010; 42(5):697-702. doi: 10.1002/mus.21910.
7. Wand JS. Carpal tunnel syndrome in pregnancy and lactation. *J Hand Surg Br* 1990;15(1):93-5.
8. Padua L, Aprile I, Caliandro P, Mondelli M, Pasqualetti P, Tonali PA; Italian Carpal Tunnel Syndrome Study Group. Carpal tunnel syndrome in pregnancy: multiperspective follow-up of untreated cases. *Neurology* 2002 Nov;59(10):1643-6.
9. Stolp-Smith KA, Pascoe MK, Ogburn PL Jr. Carpal tunnel syndrome in pregnancy: frequency, severity, and prognosis. *Arch Phys Med Rehabil* 1998;79(10):1285-7.

# Posttraumatic Attenuation of the Lisfranc Ligament in a 14-Year-Old Athlete: A Case Report

Paul J. Johnson, MD; David M. Bennett, MD

Department of Orthopaedics & Rehabilitation, The University of New Mexico Health Sciences Center, Albuquerque, New Mexico

## Abstract

Lisfranc injuries in children are rare and range from mild midfoot sprains to severe traumatic fracture-dislocations. Management of sprains is nonoperative, whereas treatment of fracture-dislocations often requires internal fixation. We present a unique case of a midfoot sprain in a 14-year-old adolescent boy, with gradual increased instability at the joint owing to attenuation of the Lisfranc ligament. Closed reduction and percutaneous pinning resulted in successful treatment at 3 weeks postoperatively. Midfoot sprains may lead to further ligamentous attenuation and widening as seen on radiographs and thus should be monitored for signs of persistent pain and instability. Because midfoot instability contributes considerably to posttraumatic arthritis, we recommend reduction when nonoperative interventions are unsuccessful.

## Introduction

The tarsometatarsal complex (TMC), often referred to as the “Lisfranc joint,” is an intricate region of anatomy encompassing the tarsometatarsal, intermetatarsal, and intertarsal articulations. The Lisfranc ligament is an important structure for longitudinal and transverse stability of the osseous arch formed in this region.<sup>1</sup> This interosseous ligament is the strongest of the ligaments in the region and originates on the medial cuneiform, inserting at the plantar surface of the second metatarsal base. Other important ligaments of the TMC include the plantar tarsometatarsal ligaments and the interosseous ligament between the medial and middle cuneiforms. The plantar tarsometatarsal ligaments maintain transverse stability at the joint, whereas the interosseous ligament between the medial and middle cuneiforms maintains longitudinal stability in the region.<sup>2</sup>

Injuries to the TMC range from mild sprains of the ligaments to complete articular disruption and dislocation. TMC sprains, or “midfoot sprains,” occur in competitive

athletes of all types.<sup>3</sup> Competitive American football players seem to be especially at risk for TMC injury. Annually, 4% of college football players sustain a midfoot sprain.<sup>3</sup> These low-energy injuries to the tarsometatarsal complex may occur when an axial load is applied to a plantar-flexed foot with simultaneous rapid abduction or twisting.<sup>4</sup> Each of these injuries by definition involves some compromise of the Lisfranc ligament.<sup>4</sup>

While walking down a staircase, pain is common in subtle midfoot sprains.<sup>5</sup> Ecchymosis of the plantar arch is considered pathognomonic for Lisfranc injury.<sup>5</sup> Diagnosis by perceived widening on plain radiographs can be subjective, depending on the quality of the radiographs and the precise orientation of the X-ray tube and plate.<sup>6</sup> Diagnosis of a severe Lisfranc injury can be obvious, yet minor sprains in the region are commonly missed in the clinic.<sup>7</sup> Up to 35% of these injuries are misdiagnosed or missed at the initial visit.<sup>8</sup>

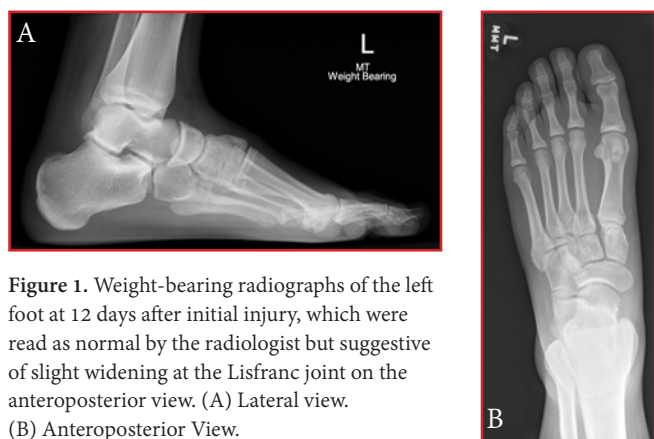
Although sports-related injuries are also the greatest contributor to Lisfranc damage in children, the occurrence is rarely reported in these younger populations.<sup>9</sup> Nonoperative treatment of Lisfranc injuries in children has been common, with use of immobilization and protected weight bearing.<sup>10</sup> Yet Lisfranc injuries that show signs of instability often necessitate operative fixation for successful treatment.<sup>4</sup> Overall, limited data exist to guide evidenced-based diagnosis and treatment of pediatric patients. We describe an adolescent patient who presented with a seemingly mild midfoot sprain with attenuation of the Lisfranc ligament. Initially, no clinical evidence of instability was noted. The patient’s family was informed that the data concerning the case would be submitted for publication, and they provided verbal consent.

## Case Report

A 14-year-old male athlete injured his left foot while playing American football. He was tackled while planting his plantar-flexed foot on the ground and felt a “pop.” The

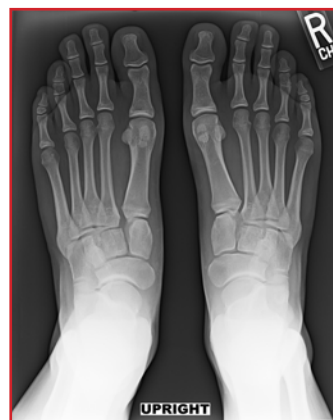patient was unable to bear weight after the injury. He was initially seen at an urgent-care facility, where his injury was diagnosed as an ankle sprain because radiographs of the foot and ankle did not indicate any abnormality.

He reported to the emergency department at 12 days after the injury, with swelling and bruising on the plantar arch of his foot. The patient had been ambulating without crutches intermittently, and the pain did not resolve. The emergency-department physicians ordered weight-bearing radiographs (these did not include the uninjured foot), which the radiologist read as negative for widening at the Lisfranc joint or other fractures (Figures 1A and 1B). Owing to his increasing amount of pain, the patient was referred to our pediatric orthopaedic clinic. He was given a walking boot at discharge.

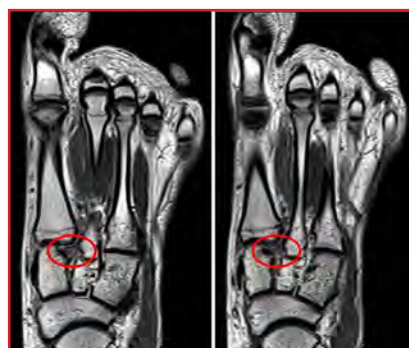

**Figure 1.** Weight-bearing radiographs of the left foot at 12 days after initial injury, which were read as normal by the radiologist but suggestive of slight widening at the Lisfranc joint on the anteroposterior view. (A) Lateral view. (B) Anteroposterior View.

At 17 days after his injury, the patient presented to our clinic with continued pain while ambulating. Results of physical examination revealed ecchymosis of the plantar arch. The midfoot region was tender to palpation, and abduction and pronation of the forefoot elicited pain. Despite the negative findings of previous radiographs, the clinical examination results were suggestive of a Lisfranc injury. We believed that the radiographs showed evidence of widening, and recommended non-weight bearing. Radiographs and magnetic resonance imaging (MRI) were obtained (Figures 2 and 3, respectively). The MRI showed a small fracture on the lateral aspect of the second metatarsal base, and an intact but attenuated Lisfranc ligament with heterogeneously mixed high and low signals. Because the patient had not shown considerable widening of the joint radiographically, he began weight bearing in the walking boot.

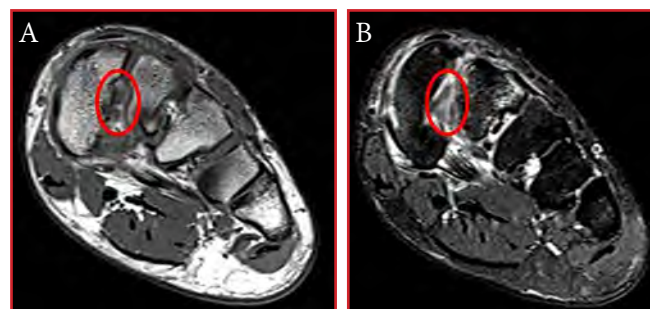


**Figure 2.** At 17 days after initial injury, weight-bearing radiograph of both feet shows subtle widening of the Lisfranc interval of the left foot.



**Figure 3.** At 17 days after initial injury, sequential coronal cuts at 3 mm apart in the proton density-weighted magnetic resonance imaging series shows the Lisfranc ligament with heterogeneous signal (circle) that indicates injury.

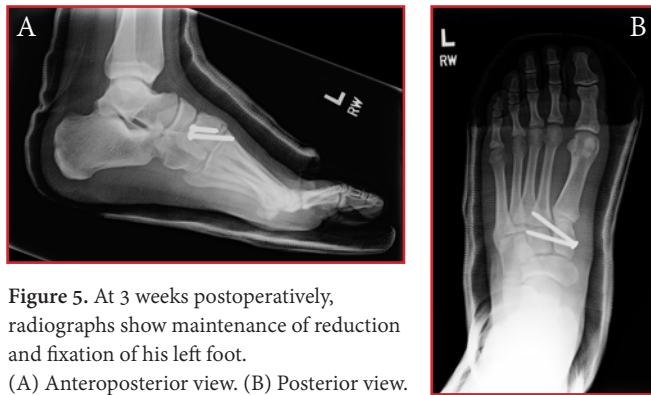
At 2 months after his injury, the patient had continued mild pain, but new MRI showed an increase in widening at the Lisfranc interval (Figures 4A and 4B). Because of the continued pain and instability on weight-bearing radiographs, we offered the patient a surgical intervention with open versus closed reduction and internal fixation. The patient and parents were in favor of the operation.



**Figure 4.** At 3 months after the injury, magnetic resonance imaging in axial view shows the Lisfranc ligament with heterogeneous signal (circle) indicating injury. (A) Proton density-weighted sequence. (B) T2-weighted sequence.

At 3 months after the initial injury, we performed closed reduction and percutaneous pinning. With the patient under anesthesia, we placed a percutaneous two-point clamp across the medial cuneiform and the third metatarsal. The joint was fluoroscopically visualized to close. We placed a 4-mm cannulated screw from the medial cuneiform to the second metatarsal base. A second screw was placed from the medial cuneiform to the middle cuneiform (Figures 5A and 5B). The patient was immobilized in a cast and made non-weight bearing.

Follow-up radiographs at 3 weeks postoperatively showed maintenance of the reduction and fixation without complication (Figures 5A and 5B). The patient's pain has been improving and he will begin weight-bearing between 12 to 16 weeks postoperatively.



**Figure 5.** At 3 weeks postoperatively, radiographs show maintenance of reduction and fixation of his left foot. (A) Anteroposterior view. (B) Posterior view.

## Discussion

Unstable Lisfranc injuries that are unsuccessfully treated using conservative approaches can warrant operative fixation.<sup>4</sup> Although most mild sprains may be treated nonoperatively, attenuation of the ligament can progress to increased instability as shown in the current case.

Advanced imaging techniques can be useful in diagnosis, especially when findings of clinical examination are suggestive of an injury yet radiographs are not. Computed tomography can help detect bony avulsions or subtle subluxations at the articulation points.<sup>11</sup> Furthermore, MRI has a 95% sensitivity and 75% specificity for detecting disruption of the Lisfranc ligament.<sup>11</sup> Bone scintigraphy has been described as a sensitive imaging modality that can detect the subtle inflammation at the corners of the medial cuneiform and the second metatarsal base when injured, although the sensitivity and specificity have not been determined.<sup>4</sup>

In the current case, the findings of MRI helped confirm a Lisfranc injury, despite the normal findings on previous radiographs. Generalized pain in the midfoot and a typical mechanism of injury should lead the practitioner to include midfoot sprain on their list of differential diagnoses,

especially if the pain persists for an extended period after initial injury.

Continued pain months after injury and increased radiographic widening of the Lisfranc interval led us to perform a closed reduction and internal fixation for treating our patient. We believed that continued nonoperative management of the subacute injury would yield inadequate final alignment. Operative fixation of this injury was performed to prevent progressive osteoarthritis of the midfoot, beginning at an early age. Although posttraumatic arthritis may precipitate, studies have suggested that reduction and internal fixation of unstable Lisfranc injuries significantly decreases the rates of future arthritis.<sup>12</sup>

The current case report has limitations. Notably, the follow-up data was reported recently at 3 weeks postoperatively, which may not accurately reflect complete treatment outcomes. Additionally, the patient was a skeletally mature adolescent boy whose treatment may better reflect that of an adult population rather than children. Furthermore, the MRI findings (particularly the small osseous avulsion) may indicate a Lisfranc ligament rupture and less of a sprain, which could affect the success of treatment.

Lisfranc injuries in the pediatric population are rare. Minor sprains are more common and can usually be managed nonoperatively. However, midfoot sprains may lead to further ligamentous attenuation and widening on radiographs and thus should be monitored for persistent pain and instability. Because midfoot instability contributes notably to posttraumatic arthritis, reduction and fixation can be helpful when nonoperative interventions are unsuccessful.

## Funding

The authors received no financial support for the research, authorship, and publication of this article.

## Conflict of Interest

The authors report no conflicts of interest.

## References

1. Watson TS, Shurnas PS, Denker J. Treatment of Lisfranc joint injury: current concepts. *J Am Acad Orthop Surg* 2010 Dec;18(12):718-28.
2. Kaar S, Femino J, Morag Y. Lisfranc joint displacement following sequential ligament sectioning. *J Bone Joint Surg Am* 2007;89(10):2225-32.

3. Meyer SA, Callaghan JJ, Albright JP, Crowley ET, Powell JW. Midfoot sprains in collegiate football players. *Am J Sports Med* 1994;22(3):392-401.
4. Nunley JA, Vertullo CJ. Classification, investigation, and management of midfoot sprains: Lisfranc injuries in the athlete. *Am J Sports Med* 2002;30(6):871-8.
5. Mantas JP, Burks RT. Lisfranc injuries in the athlete. *Clin Sports Med* 1994;13(4):719-30.
6. Hatem SF. Imaging of lisfranc injury and midfoot sprain. *Radiol Clin North Am* 2008;46(6):1045-60, vi. doi: 10.1016/j.rcl.2008.09.003.
7. Veijola K, Laine HJ, Pajulo O. Lisfranc injury in adolescents. *Eur J Pediatr Surg* 2013;23(4):297-303. doi: 10.1055/s-0032-1330847.
8. Vuori JP, Aro HT. Lisfranc joint injuries: trauma mechanisms and associated injuries. *J Trauma* 1993;35(1):40-5.
9. Hill JF, Heyworth BE, Lierhaus A, Kocher MS, Mahan ST. Lisfranc injuries in children and adolescents. *J Pediatr Orthop B* 2017;26(2):159-163. doi: 10.1097/BPB.0000000000000380.
10. Johnson GF. Pediatric Lisfranc injury: "bunk bed" fracture. *AJR Am J Roentgenol* 1981;137(5):1041-4.
11. Raikin SM, Elias I, Dheer S, Besser MP, Morrison WB, Zoga AC. Prediction of midfoot instability in the subtle Lisfranc injury: comparison of magnetic resonance imaging with intraoperative findings. *J Bone Joint Surg Am* 2009;91(4):892-9. doi: 10.2106/JBJS.H.01075.
12. Kuo RS, Tejwani NC, Digiovanni CW, et al. Outcome after open reduction and internal fixation of Lisfranc joint injuries. *J Bone Joint Surg Am* 2000;82-A(11):1609-18.

# Capitate Stress Injuries of Both Wrists in an Adolescent Female Gymnast: A Case Report

Brynne R. W. Latterell, MPH<sup>\*</sup>; Deana M. Mercer, MD<sup>†</sup>; Shane P. Cass, DO<sup>‡</sup>;  
Christopher A. McGrew, MD<sup>†‡</sup>

<sup>\*</sup>School of Medicine, The University of New Mexico Health Sciences Center, Albuquerque, New Mexico

<sup>†</sup>Department of Family & Community Medicine, The University of New Mexico Health Sciences Center, Albuquerque, New Mexico

<sup>‡</sup>Department of Orthopaedics & Rehabilitation, The University of New Mexico Health Sciences Center, Albuquerque, New Mexico

## Abstract

Gymnastic activities expose the wrist to a wide variety of overuse and acute stresses. Injuries to the distal radius are the most commonly reported gymnastic wrist condition; however, many other structures are at risk of injury from the sport's high acute and overuse demands, including the carpal bones, most commonly the scaphoid. We describe a 17-year-old female, high-level gymnast in whom stress injuries to both capitate bones were ultimately diagnosed after initial symptoms of pain. This case demonstrated the need for prompt recognition, without which much chronic and debilitating injury would develop. For successful diagnosis, healthcare providers should carefully examine and evaluate reported wrist pain in high-level, adolescent gymnasts.

## Introduction

Acute and chronic upper-extremity injuries are common in gymnasts. Typical injuries in female gymnasts involve the wrist, whereas men often report shoulder injuries.<sup>1</sup> In one systematic review examining wrist injuries in adolescent athletes, gymnastics was the most common sport reported.<sup>2</sup> During gymnastic activities, the wrist is exposed to many different types of stresses, including repetitive motion, high impact loading, axial compression, torsional forces, and distraction in varying degrees of ulnar or radial deviation and hyperextension.<sup>1</sup>

Radial epiphysitis is a frequent cause of wrist pain and injury in young gymnasts.<sup>1-4</sup> Other diagnoses include scaphoid impaction syndrome, dorsal impingement, scaphoid fractures, scaphoid stress reactions and fractures, ganglia, carpal instability, triangular fibrocartilage complex tears, ulnar impaction syndrome, and lunotriquetral impingement.<sup>1</sup>

Published case reports are limited on capitate stress injury.<sup>5,6</sup> One study<sup>5</sup> involved a 42-year-old male physical-education teacher who was instructing gymnastics; the other<sup>6</sup> described a 30-year-old male dock worker who developed a capitate stress fracture after months of using a lever to operate heavy machinery. Another study<sup>7</sup> radiographically reported a group of 18 children with capitate stress fractures among a larger collection of tarsal and carpal cases in a 30-year period. However, this study did not include specific demographic characteristics of patients such as gender and activities.

We describe the eventual diagnosis of stress injuries to both capitate bones of a 17-year-old, high-level gymnast, who initially presented with 2 months of pain in both wrists. The patient and her mother were informed that the data concerning the case would be submitted for publication, and they provided verbal consent.

## Case Report

A 17-year-old, female gymnast presented to the sports-medicine clinic with pain in both of her wrists for 2 months. She started participating in gymnastics at age 5 years and began competing at age 12. Four months prior to initial presentation, the intensity of her practices increased when she began training with a new coach. The patient did not recall a specific single traumatic episode. Of the four gymnastic events, the balance beam bothered her the most. The patient was healthy; she had regular menstrual periods since age 13 years, did not smoke or use tobacco, and reported no previous stress fractures.

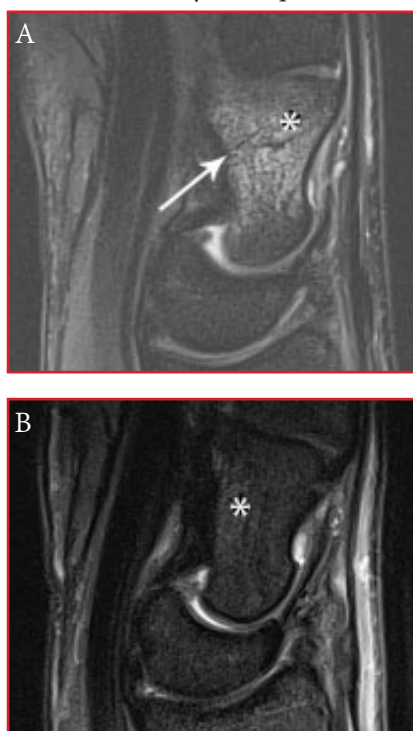
Results of physical examinations indicated no obvious wrist deformities. The patient had decreased extension and flexion on both wrists, with mildly limited supination. She had tenderness over the distal radius, ulna, and dorsal wrist but not specifically over the capitate. Findings of her



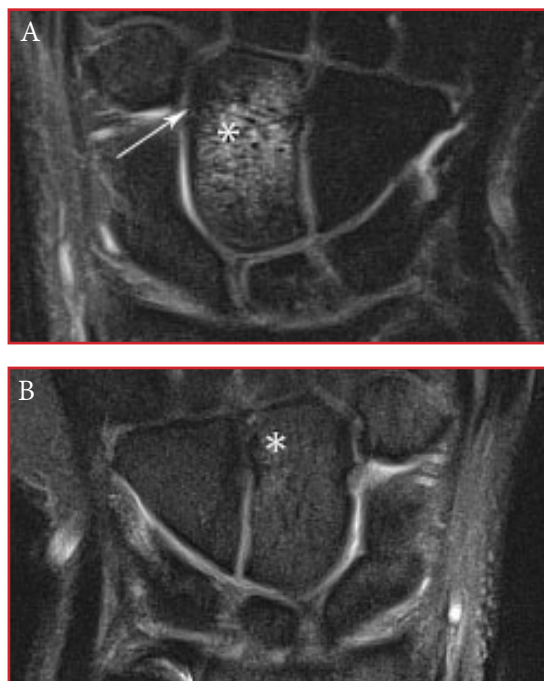
neurovascular examination and elbows test were normal. Plain radiographs of the forearm and wrist showed closed physes, but findings were otherwise unremarkable. At this point, the family agreed to obtain magnetic resonance imaging (MRI) of both wrists to investigate the source of the pain. The patient was instructed to avoid painful activity and wear braces to help limit wrist hyperextension while waiting for the MRI results.

The MRI revealed stress injuries of the capitate bones in both wrists. The patient was referred to a pediatric orthopaedist who reviewed the imaging. The surgeon noted a stress fracture of the distal third of the left capitate and stress reaction of the right distal capitate, caused by hyperextension, with a likely mechanism of metacarpal-capitate abutment (Figures 1A through 3A). The injury was less severe in the right wrist compared with the left, with limited signs of edema (Figures 1B and 2B) and no fracture line (Figures 1B and 3B). The patient continued wearing the braces to prevent hyperextension of the wrists and was asked to avoid gymnastic activity for 6 to 12 weeks.

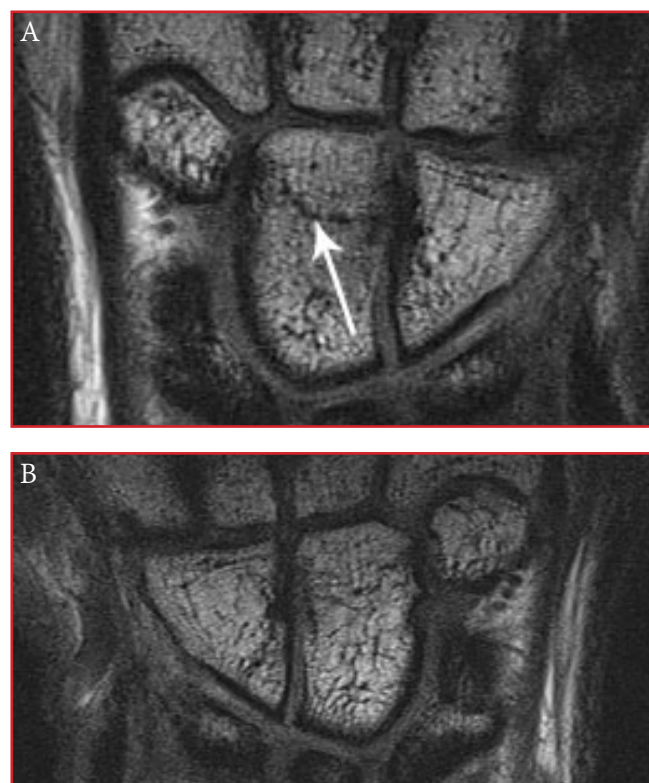
At 6 weeks after the MRIs revealed the injury, the patient reported no pain in her wrists. Physical examination findings were normal, with a full range of motion and no dorsal tenderness of her wrist. She was directed to gradually resume activity, with progressive symptom-limited training, and return to the clinic if she felt pain. The patient did not return for any subsequent visit.



**Figure 1.** T2-weighted magnetic resonance imaging of the (A) left wrist and (B) right wrist, showing sagittal view of the capitate edema (white asterisk) and a fracture line (arrow) extending from volar proximal to dorsal distal in the distal third of the capitate. Notably, on the right wrist, the edema is less severe and no fracture line is seen.



**Figure 2.** T2-weighted magnetic resonance imaging of the (A) left wrist and (B) right wrist, showing coronal view of capitate edema (white asterisk) and a fracture line (arrow) extending transversely in the distal third of the capitate. Notably, on the right wrist, the edema is less severe and no fracture line is seen.



**Figure 3.** T1-weighted magnetic resonance imaging of the (A) left wrist and (B) right wrist, showing coronal view of the capitate fracture line (arrow) extending transversely in the distal third of the capitate. Notably, the fracture line is not visible on the right wrist, indicating a less severe injury compared with the left wrist.

## Discussion

This is the first case report of a capitate stress fracture in an adolescent female athlete. The exact mechanism of injury to the capitate bone is complex; however, the axis-based position of the capitate may cause strain during ulnar and radial deviation of the wrist.<sup>6</sup> In the current case, the MRI revealed a less severe stress injury of the right wrist compared to the left, which could indicate that a higher level of force was applied to the left wrist during gymnastic activity. However, it could also be due to frequency of wrist bearing and strain, specific positions of the wrist, as well as many other variables. Furthermore, this patient met two out of three key risk factors detailed in a study of overuse injuries in young athletes including early onset of training (our patient started training at age 12) and sudden increase in training intensity (our patient increased training intensity with her new coach).<sup>2</sup> Other risk factors mentioned in a study specifically on young competitive female gymnasts included recent injury, periods of rapid bone growth, low level of bone maturation, and advanced levels of training and competition.<sup>9</sup>

Standard treatment for overuse injuries such as a stress fracture involves relative rest, allowing non-painful activities with appropriate bracing to limit extremes of motion.<sup>1,3,8</sup> Return to participation is usually over a 6- to 12-week timeframe, depending on severity of symptoms, findings of physical examination, and, though less common, findings of repeat imaging.<sup>1,3,8</sup> If untreated, capitate stress fractures may result in possible career-altering or ending outcomes for patients. Complications include fracture displacement, non-union in fractures involving the cortical bone, malunion of displaced fractures, avascular necrosis associated with chronic pain, loss of range of motion, and need for surgical intervention.<sup>1-6</sup>

Although stress injuries of the capitate in gymnasts are relatively rare,<sup>5,6</sup> athletes, coaches, parents, and healthcare providers should not dismiss chronic or progressive wrist pain and soreness as normal results of training. Despite normal plain radiograph findings, a high index of suspicion should be maintained when evaluating wrist pain in these athletes. Use of MRI (with situational use of nuclear medicine bone scanning and computed tomography) can be helpful to assess the presence and severity of wrist injury in high-level, adolescent gymnasts.

## Funding

The authors received no financial support for the research, authorship, and publication of this article.

## Conflict of Interest

The authors report no conflicts of interest.

## References

1. Webb BG, Rettig LA. Gymnastic wrist injuries. *Curr Sports Med Rep* 2008;7(5):289-95. doi: 10.1249/JSR.0b013e3181870471.
2. Kox LS, Kuijjer PP, Kerkhoffs GM, Maas M, Frings-Dresen MH. Prevalence, incidence and risk factors for overuse injuries of the wrist in young athletes: a systematic review. *Br J Sports Med* 2015;49(18):1189-96. doi: 10.1136/bjsports-2014-094492.
3. Wolf MR, Avery D, Wolf JM. Upper extremity injuries in gymnasts. *Hand Clin* 2017;33(1):187-197. doi: 10.1016/j.hcl.2016.08.010.
4. Poletto ED, Pollock AN. Radial epiphysitis (aka gymnast wrist). *Pediatr Emerg Care* 2012;28(5):484-5. doi: 10.1097/PEC.0b013e318259a5cc.
5. Allen H, Gibbon WW, Evans RJ. Stress fracture of the capitate. *J Accid Emerg Med* 1994;11(1):59-60.
6. Vizkelety T, Wouters HW. Stress fracture of the capitate. *Arch Chir Neerl* 1972;24(1):47-57.
7. Oestreich AE, Bhojwani N. Stress fractures of ankle and wrist in childhood: nature and frequency. *Pediatr Radiol* 2010;40(8):1387-9. doi: 10.1007/s00247-010-1577-y.
8. Jones GL. Upper extremity stress fractures. *Clin Sports Med* 25(1):159-74. doi: 10.1016/j.csm.2005.08.008.
9. Caine D, Cochrane B, Caine C, Zemper E. An epidemiologic investigation of injuries affecting young competitive female gymnasts. *American Journal of Sports Med* 2016;17(6):811-20. doi: 10.1177/036354658901700616.

# Transhumeral Amputation for Treating Necrotizing Fasciitis Infection of the Upper Extremity: Report of Two Cases

Drew K. Newhoff, MD; Amber L. Price, MD; Christina Salas, PhD; Deana M. Mercer, MD  
Department of Orthopaedics & Rehabilitation, The University of New Mexico Health Sciences Center,  
Albuquerque, New Mexico

## Abstract

Necrotizing fasciitis, an infection of the skin and subcutaneous tissue, can spread rapidly. Studies have emphasized the importance of prompt surgical intervention with aggressive debridement of diseased tissue; however, mortality rates are high despite immediate treatment. We describe two men, aged 44 years (case 1) and 74 years (case 2), presenting with necrotizing fasciitis who underwent aggressive surgical intervention, multiple debridements, and eventual transhumeral amputation of the upper extremity. In each case, the patients were discharged from the hospital to their homes on amoxicillin-clavulanate at postoperative days 15 (case 1) and 32 (case 2). Findings of laboratory studies had normalized. Early diagnosis of necrotizing fasciitis is vital for successful treatment of the infection. We recommend limb amputation as a life-saving measure if aggressive debridement and antibiotic therapy are unsuccessful.

## Introduction

Necrotizing fasciitis is a life-threatening infection of the subcutaneous tissue and spreads rapidly.<sup>1</sup> The most common pathogen of this disease, group A streptococcus, is ubiquitous and present in normal human oral flora.<sup>2</sup> Early diagnosis and surgical debridement, in conjunction with antibiotic therapy, reduce the death rates associated with necrotizing fasciitis.<sup>1</sup> Even with appropriate treatment, mortality rates as high as 33% have been reported.<sup>3</sup>

Scores of the Laboratory Risk Indicator for Necrotizing Fasciitis have helped determine the presence of the infection based on component levels (C-reactive protein,  $\geq 150$  mg/L; total white blood cell count,  $> 15$  g/L; hemoglobin,  $< 13.5$  g/dL; sodium,  $< 135$  mmol/L; creatinine,  $> 1.41$  mg/dL; and glucose,  $> 10$  mmol/L).<sup>4</sup> The goal of this study was to reflect upon the importance of co-morbidity factors on the exacerbation of spread and severity of infection with respect to upper limb necrotizing fasciitis

associated with fight bite, as well as comment on the importance of limb amputation as a life saving treatment option. We describe two men who presented with clinical findings of necrotizing fasciitis of the upper extremity. After repeated unsuccessful and extensive debridements and fasciotomies, with continued hemodynamic instability, florid bacterial sepsis, and progression of necrotic muscular tissue in both patients, transhumeral amputation was performed. The patients were informed that the data concerning the case would be submitted for publication, and they provided verbal consent.

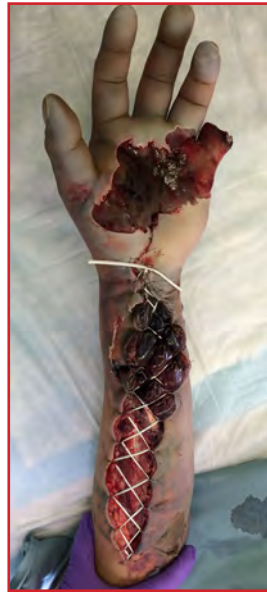## Case 1

A 44-year-old man presented to our emergency department for evaluation of worsening pain and swelling in his left hand and forearm. The patient reported involvement in an altercation 48 hours earlier, in which he struck another individual in the mouth and sustained a laceration to the dorsal aspect of his small finger, near the metacarpophalangeal (MCP) joint. He did not seek care for 24 hours, when he woke up with pain and swelling in his left hand. The patient was seen at an outlying hospital and transferred to our tertiary care center for definitive treatment. Notably, he had a past medical history significant for type 2 diabetes, hypertension, and alcohol abuse.

On admission, he had a discolored hand and forearm. A 4-mm laceration was noted over the dorsal aspect of the MCP joint of the small finger, with purulent discharge. The hand was cool, entirely insensate, and compartments in the forearm were firm. The patient expressed pain with passive extension of the fingers and no active motion of the digits. Neither the radial nor ulnar pulses were palpable nor present on Doppler examination, although the brachial artery was. Radiographs revealed no bony abnormalities or gas in the soft tissues. Initial results of laboratory studies confirmed the suspected diagnosis of necrotizing fasciitis (white blood cell count, 20.5 g/L; hemoglobin, 14.6 g/L;

serum sodium, 123 mmol/L; lactate, 5.2 mmol/L; and creatinine, 1.09 mg/dL).

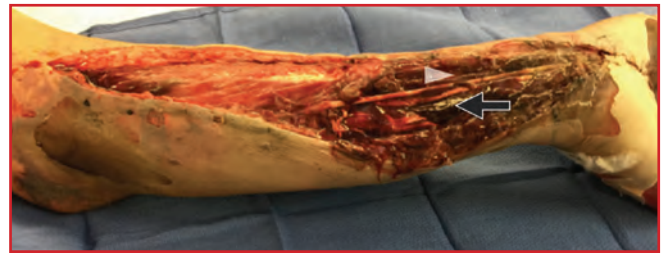The patient was taken urgently to the operating room. Fasciotomies of the forearm were performed for treatment of his compartment syndrome. Operative evaluation indicated bulging muscle compartments of the forearm after fasciotomies (Figure 1). His small finger was necrotic, with a septic proximal interphalangeal joint; therefore, the small finger was amputated at the level of the mid-proximal phalanx. The muscle appeared to improve in color on release of the fascia but was not contractile.



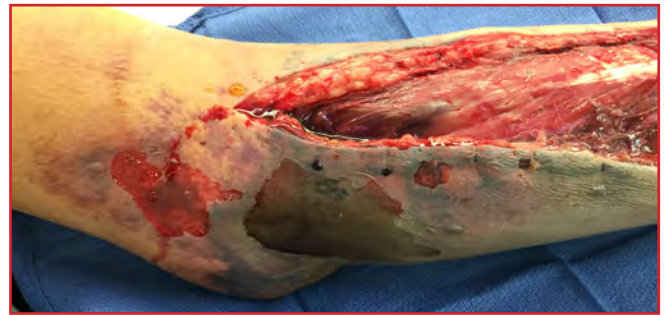
**Figure 1.** Intraoperative, anterior view of left forearm and hand in case 1 shows bulging muscle compartments and temporary closure.

The forearm culture, obtained intraoperatively, was positive for *Streptococcus pyogenes*, and a blood culture was negative for bacterial growth. The patient remained critically ill, with labile blood pressures after the procedure, and was taken to the intensive care unit. Unasyn was administered on admission to the emergency department and continued in the intensive care unit. Clindamycin was also administered during his stay in the intensive care unit.

At 48 hours after the initial injury, repeated irrigation and debridement procedures were performed. Progression of the necrotic muscle was noted, and the flexor compartment was entirely devitalized and debrided (Figure 2). A thin, light-brown colored watery discharge was observed when the wound was opened (Figure 3). Based on the extent of infection, devitalized tissue, and persistent hypotension, transhumeral amputation was performed. The wound was left open to drain. In the subsequent week, serial debridements were performed in four additional operative procedures, in which necrotic muscle was excised.



**Figure 2.** Intraoperative, anterior view of left forearm in case 1 shows notable devitalization of flexor digitorum superficialis (black arrow) and carpi radialis (white arrow).

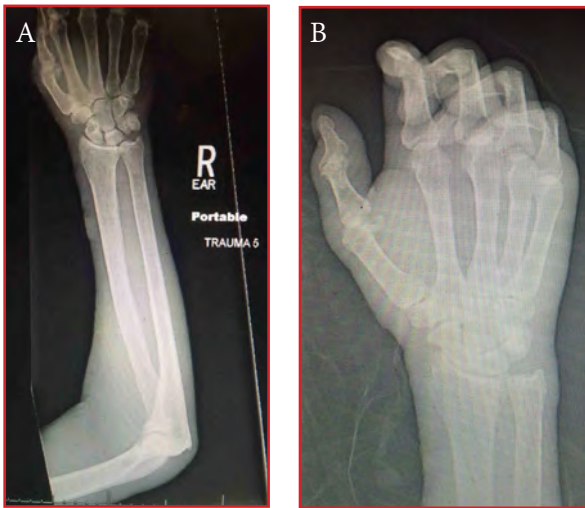

**Figure 3.** Intraoperative, anterior view of left elbow in case 1 indicates thin watery discharge encountered in wound.

After undergoing transhumeral amputation, the patient recovered and was discharged from the hospital on amoxicillin-clavulanate at postoperative day 15. At 1 week after the transhumeral amputation, the appearance of the arm improved and the open wound was definitively treated with delayed primary closure. At discharge, component values obtained from laboratory tests and vital signs had normalized (white blood cell count, 7.8 g/L; serum sodium, 136 mmol/L; and lactate, 0.9 mmol/L).

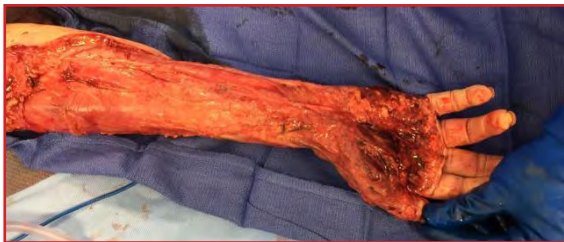### Case 2

A 74-year-old man was transferred to our facility from a rehabilitation center. He had worsening pain and swelling in his right upper extremity and rapidly deteriorating mental status during a 24-hour period. Notably, the patient had past medical history significant for dementia, depression, type 2 diabetes, posttraumatic stress disorder, alcohol withdrawal with history of seizures, traumatic brain injury, ascitis, and alcoholic cirrhosis of the liver. On clinical examination, the patient had a superficial abrasion over the dorsum of the hand, with cellulitis extending to the antecubital fossa, and sloughing of the skin. Radiographic findings were of nonspecific soft tissue edema, with no evidence of subcutaneous air (Figures 4A and 4B). He was admitted to the intensive care unit after a diagnosis of sepsis (white blood cell count, 33.5 g/L; hemoglobin, 13.9 g/L; serum sodium, 139 mmol/L; lactate, 13.3 mmol/L; and creatinine, 2.45 mg/dL, ESR 8, CRP 12.5).



**Figure 4.** Preoperative radiograph of right forearm and hand in case 2. (A) Nonspecific swelling of the dorsal forearm. (B) Swelling of the hand dorsum.

The patient was taken urgently to the operating room where fasciotomies of the forearm were performed and devitalized tissue was aggressively debrided (Figure 5). Fascial tissues were surrounded by a thin dishwater-colored serous fluid, a known finding in patients with necrotizing fasciitis. Intraoperative cultures were positive for *Streptococcus pyogenes* or group A streptococcus. Postoperatively, he returned to the intensive care unit and remained critically ill. He was started on clindamycin.



**Figure 5.** Intraoperative view of the right forearm and hand in case 2 after fasciotomy and aggressive debridement, showing development of devitalized tissue over the palmar surface of the hand.

For 15 hours, the clinical status of the patient continued to deteriorate. Evidence of proximal progression of the infection was noted, and component values obtained from laboratory tests did not improve. The decision was made to proceed with transhumeral amputation, just above the elbow for source control, and delayed closure.

After undergoing transhumeral amputation, the patient recovered and was discharged from the hospital on amoxicillin-clavulanate at postoperative day 32. Component values had similarly normalized at discharge (white blood cell count, 6.6 g/L; hemoglobin, 11.1 g/L; serum sodium, 139 mmol/L; lactate, 1.0 mmol/L; and creatinine, 0.74 mg/dL).

## Discussion

The axiom “life before limb” is often cited in orthopaedics and trauma surgery in the face of devastating injury or infection. The current cases represent the severity of infection and risk to life in those afflicted with necrotizing fasciitis. Both involved overwhelming infection, rapidly deteriorating clinical status, and consensus that the limb had to be removed to save the patient’s life. Once amputation had occurred, both patients demonstrated improved blood pressures, improving kidney function and subsequent decrease in leukocytosis.

To our knowledge, case 1 is one of the first reports of necrotizing fasciitis resulting from a human bite to the hand. Wienert et al.<sup>5</sup> described a human bite to the lower extremity, which caused an infection with group A streptococcus that resulted in necrotizing fasciitis. The infection was successfully treated with repeated debridement and a limb salvage procedure. Additionally, Motsitsi<sup>6</sup> reported a fatal case of necrotizing fasciitis after a human bite to the upper extremity. Studies involving the presence of necrotizing fasciitis after human bites in the lower extremities,<sup>7,8</sup> and sexual organs<sup>8</sup> have also been noted.

Factors affecting the mortality rate of patient’s have varied significantly in the research (Table 1). However, we could find only one study that analyzed this for the upper limb only. Yeung et al<sup>9</sup> found that liver failure, thrombocytopenia, initial more proximal involvement, renal failure, and hypotension upon initial presentation were predictors of mortality in patients with necrotizing fasciitis of the upper limb. Jabbour et al<sup>10</sup> did a large scale review of the literature and found that delay in diagnosis, advanced age, existence of multiple medical comorbidities, polymicrobial infections, and bacteremia were associated with higher mortality. In contrast, earlier surgical debridement and early antibiotic therapy were associated with decreased mortality.<sup>11,12</sup> Hypertension, diabetes mellitus and renal impairment were found to be the comorbidities that were most associated with mortality, with diabetes being the most prevalent.<sup>10</sup>

For both of our patients, early diagnosis was based on intraoperative appearance of the wound and confirmed with findings of intraoperative cultures. Both patients presented to our emergency department in early decline. Quick clinical diagnosis of necrotizing fasciitis is critical but is often missed or delayed.<sup>13</sup> However, there are several clinical features that can act as risk indicators. Most importantly, these include a significantly elevated CRP of  $\geq 150$  mg/l as well as decreased hemoglobin and erythrocyte count.<sup>13</sup> Aggressive operative treatment, antibiotic therapy, and eventual amputation after notable

**Table 1.** Summary of recently published studies analyzing predictors of mortality and overall mortality associated with necrotizing fasciitis

Study	Year, country	Study type	No. patients	Mortality rate	Predictors of mortality
Yeung et al <sup>9</sup>	2011, Japan	Retrospective	29	28%	Decreased renal and liver function, thrombocytopenia, initial proximal involvement, hypotension on admission, ALERTS score of 3
Hadeed et al <sup>12</sup>	2016, US	Retrospective	87	12.5%	Surgical intervention by 6 h after presentation (17.5% in late group vs. 7.5% in early group)
Kao et al*	2011, US	Retrospective	296	9%-25%, six hospitals	Patient age, severity of disease (ie, presence of shock requiring pressor support and renal failure)
Wong et al <sup>11</sup>	2003, Singapore	Retrospective	89	21.3%	Advanced age, > two associated comorbidities, procedure delay > 24 h (P < 0.05; relative risk = 9.4)

US, United States; ALERTS, Abnormal Liver function, Extent of infection, Renal impairment, Thrombocytopenia, and Shock.

\* Kao LS, Lew DF, Arab SN, et al. Local variations in the epidemiology, microbiology, and outcome of necrotizing soft-tissue infections: a multicenter study. *Am J Surg* 2011;202(2):139-45. doi: 10.1016/j.amjsurg.2010.07.041.

effort to save the limb led to successful clinical recovery. Concerning initial time to first debridement and interval to subsequent debridements, the results of the current cases correspond with the mean time to intervention of a recently published study<sup>14</sup> in the United Kingdom. On average, the first debridement was performed within 12 hours of patient referral to the clinic; the median delay between the first and second debridement was 24 hours.

The outcomes of our study reinforce known principles in treating necrotizing fasciitis. Aggressive surgical debridements did not change the clinical status of either patient as demonstrated in the literature, therefore amputation of the infected extremity was necessary in saving the life of these two men.

## Funding

The authors received no financial support for the research, authorship, and publication of this article.

## Conflict of Interest

The authors report no conflicts of interest.

## References

1. Fontes RA Jr, Ogilvie CM, Micalau T. Necrotizing soft-tissue infections. *J Am Acad Orthop Surg* 2000;8:151-8.

2. Goldstein EJ. Bite wounds and infection. *Clin Infect Dis* 1992;14:633-8.
3. Cunningham JD, Silver L, Rudikoff D. Necrotizing fasciitis: a plea for early diagnosis and treatment. *Mt Sinai J Med* 2001;68:253-61.
4. Wong CH, Khin LW, Heng KS, Tan KC, Low CO. The LRINEC (Laboratory Risk Indicator for Necrotizing Fasciitis) score: a tool for distinguishing necrotizing fasciitis from other soft tissue infections. *Crit Care Med* 2004;32:1535-41.
5. Wienert P, Heiss J, Rinecker H, Sing A. A human bite. *Lancet* 1999;354:572.
6. Motsitsi NS. Fatal necrotizing fasciitis following human bite of the forearm. *J Hand Surg Eur Vol* 2011;36:605. doi: 10.1177/1753193411411547.
7. Danino AM, Malka G. A lethal necrotizing fasciitis after human bite. *Plast Reconstr Surg* 2004;113:2234-5.
8. Sikora CA, Spielman J, Macdonald K, Tyrrell GJ, Embil JM. Necrotizing fasciitis resulting from human bites: a report of two cases of disease caused by group A streptococcus. *Can J Infect Dis Med Microbiol* 2005;16:221-4.
9. Yeung YK, Ho ST, Yen CH, et al; Hong Kong Society for Surgery of the Hand. Factors affecting mortality in Hong Kong patients with upper limb necrotising fasciitis. *Hong Kong Med J* 2011;17(2):96-104.
10. Jabbour G, El-Menyar A, Peralta R, et al. Pattern and predictors of mortality in necrotizing fasciitis patients in a single tertiary hospital. *World J Emerg Surg* 2016;11:40.

doi: 10.1186/s13017-016-0097-y.

11. Wong CH, Chang HC, Pasupathy S, Khin LW, Tan JL, Low CO. Necrotizing fasciitis: clinical presentation, microbiology, and determinants of mortality. *J Bone Joint Surg Am* 2003;85-A(8):1454-60.
12. Hadeed GJ, Smith J, O’Keeffe T, et al. Early surgical intervention and its impact on patients presenting with necrotizing soft tissue infections: a single academic center experience. *J Emerg Trauma Shock* 2016;9(1):22-7. doi: 10.4103/0974-2700.173868.
13. Borschitz T, Schlicht S, Siegel E, Hanke E, von Stebut E. Improvement of a Clinical Score for Necrotizing Fasciitis: “Pain Out of Proportion” and High CRP Levels Aid the Diagnosis. *Efron PA, ed. PLoS One* 2015;10(7):e0132775. doi: 10.1371/journal.pone.0132775.
14. Glass G, Sheil F, Ruston J, Butler P. Necrotising soft tissue infection in a UK metropolitan population. *Ann R Coll Surg Eng* 2015;97(1):46-51. doi: 10.1308/003588414X14055925058553.

# Sciatic Nerve Palsy After Operative Treatment of Subtrochanteric Femur Fracture Resulting from Postoperative Hematoma: A Case Report

Tony G. Pedri, MD; Gehron P. Treme, MD

Department of Orthopaedics & Rehabilitation, The University of New Mexico Health Sciences Center, Albuquerque, New Mexico

## Abstract

Treatment of subtrochanteric femur fractures can be difficult owing to high risk of complications. No cases of sciatic nerve palsy after hematoma following open reduction and intramedullary nailing of a subtrochanteric femur fracture have been reported. We describe a 28-year-old man who presented with a subtrochanteric fracture in the left femur after a motor-vehicle collision, in whom open reduction and intramedullary nailing led to an immediate postoperative hematoma and sciatic nerve palsy. Prompt diagnosis and early wound exploration resulted in complete resolution of the palsy at 1 month postoperatively. Our findings reinforce the importance of prompt diagnosis and treatment in limiting long-term complications for patients who develop postoperative sciatic nerve palsy associated with hematoma after undergoing operative treatment of subtrochanteric femur fractures.

## Introduction

Subtrochanteric fractures of the femur occur at the proximal aspect of the bone, between the lesser trochanter to 5 cm distally, with possible proximal or distal extension.<sup>1,2</sup> The mechanism of injury, location, and unopposed muscle forces can make closed reduction difficult. Often, open reduction is performed, and complications can include increased blood loss, malreduction, and loss of fixation.<sup>1,2</sup> A fracture table is often required for fracture fixation, with risks such as pudendal nerve injuries related to traction and sciatic nerve injuries of the uninjured side owing to positioning.<sup>3</sup>

Sciatic nerve injury after fixation of femur fractures is rare, with only a few reported cases. Lhowe and Hansen<sup>4</sup> reported a single case of injury to the sciatic nerve after intramedullary nailing for treating a femoral shaft fracture. Britton and Dunkerley<sup>5</sup> noted sciatic nerve palsy after entrapment of the nerve during closed reduction. Sciatic nerve injuries have been associated with traction during

hip arthroscopy.<sup>6</sup> Sciatic nerve palsy with postoperative hematoma has been described after total hip arthroplasty.<sup>7</sup> No study has reported sciatic nerve palsy in relation to postoperative hematoma resulting from open reduction.

We describe a transient sciatic nerve palsy in the immediate postoperative period owing to postoperative hematoma after open reduction and intramedullary nailing for treating a subtrochanteric femur fracture. The patient was informed that the data concerning the case would be submitted for publication, and he provided verbal consent.

## Case Report

A 28-year-old man presented to the emergency department as the restrained passenger in a motor-vehicle collision. He had multiple facial fractures and a closed left subtrochanteric femur fracture, classified in the AO/OTA<sup>8</sup> system as type 32-C1.1 (Figures 1A and 1B). On initial and secondary examinations, his left ankle could dorsiflex and plantarflex and his toe could flex and extend. Sensation to light touch was noted along the medial, lateral, dorsum, plantar, and first web space of the left foot, indicating intact function of the sciatic nerve. A proximal tibia traction pin was placed and approximately 6.75 kg (15 lb) of skeletal traction was initiated. The patient was admitted to the trauma surgical service for further resuscitation.

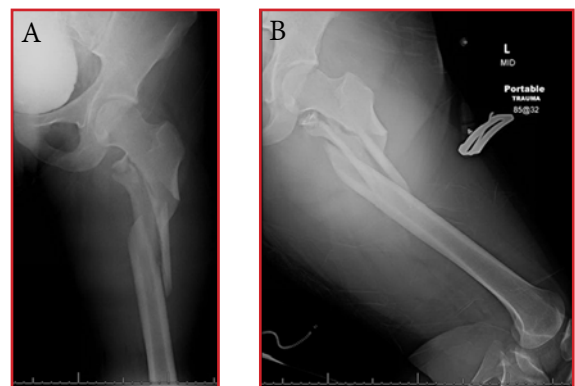
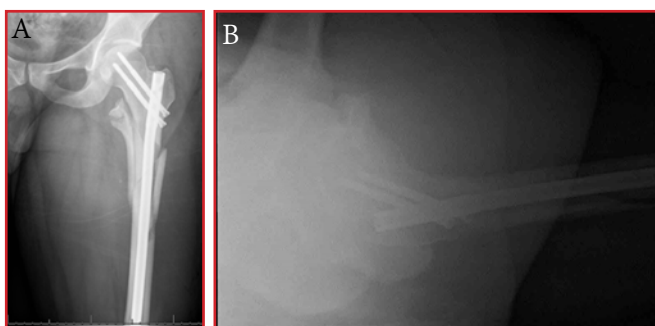


Figure 1. Preoperative radiographs of the left femur, revealing a closed subtrochanteric fracture. A) Anterior-posterior view. B) Lateral view.



On hospital day 1, the patient was taken for operative treatment under general anesthesia. He was positioned on a fracture table with a well padded peroneal and underwent open reduction and intramedullary nailing of the fracture with antegrade greater trochanteric entry nail (Figures 2A and 2B). Open reduction was achieved by direct manipulation and clamping of the fracture, using a direct lateral approach. Meticulous hemostasis was obtained with compression and electrocautery. Before closing the wound, no active bleeding was noted. Closure included the fascia of the iliotibial band, subcutaneous tissue, and skin. The operating time was 3 hours and 38 minutes, with 680 cc of estimated blood loss. Preoperative and immediate postoperative hematocrit volumes were 40% and 18%, respectively. The patient received 2 units of packed red blood cells postoperatively, and results of a second assessment for hematocrit volume was noted at 29%.

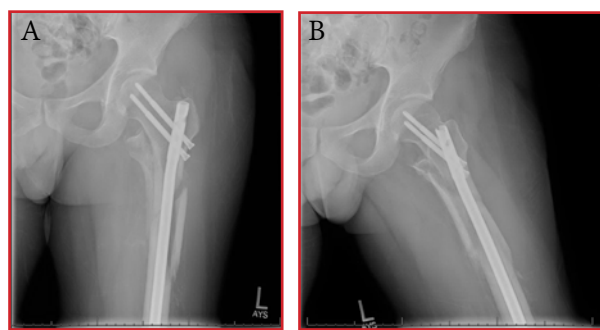


**Figure 2.** Intraoperative radiographs of the left femur, showing placement of the intramedullary nail at the greater-trochanteric entry site. A) Anteroposterior view. B) Lateral view.

At 12 hours postoperatively, the patient described a moderate increase in pain, fullness in his thigh at the site of the incision, and paresthesias in his foot. This progressed to a loss of sensation at the dorsum and plantar aspect of the left foot, with complete inability to dorsiflex or plantarflex the ankle or move the great toe. The patient rated his pain at 7 out of 10 on the visual analog scale. He described this pain level similar to that of preoperative time, with no notable increase.

Owing to the persistence of pain and loss of sensation in the patient, the decision was made to return him to the operating room immediately for exploration of the wound. He returned to the operating room approximately 13 hours after completion of the initial procedure. He was placed under general anesthesia. Intraoperatively, the previous incision was reopened without any extension of exposure. A large hematoma (100 cc) was noted and evacuated. The visualized musculature was well perfused and contractile. No abnormal active bleeding was noted. After irrigation, the wound was packed using damp gauze dressings.

On postoperative day 1, the patient had no sensation or motor function below the left knee in a sciatic nerve distribution. He could flex and extend the knee with some pain limitations. The pain level was described similarly as that experienced throughout his presentation. He was placed in an ankle-foot orthosis and observed for return of nerve function. At 5 days postoperatively, motor and sensory function returned throughout the lower extremity, with only subtle decreases in strength and sensation compared with the uninjured side. At 1-month follow-up, the patient was noted to have complete resolution of the sciatic nerve palsy. At 8-week follow-up, the patient had discontinued using his ankle foot orthosis and showed no residual neurological symptoms to the left lower extremity (Figures 3A and 3B). He was subsequently lost to follow-up, and efforts to contact the patient for a 6-month visit were unsuccessful.



**Figure 3.** Postoperative radiographs of the left femur at 8-week follow-up. A) Anteroposterior view. B) Lateral view.

## Discussion

Subtrochanteric femur fractures are frequently the result of a high-energy mechanism. Assessment of the initial injury, definitive fixation, and postoperative treatment course provide unique challenges for orthopaedic surgeons, with numerous reported complications.<sup>1-3</sup> Although sciatic nerve palsy is a well-documented complication after total hip arthroplasty and hip arthroscopy, it is a rare occurrence after operative treatment of subtrochanteric femur fractures.<sup>6,7,9</sup> Our patient developed sciatic nerve palsy after such treatment, which resolved after evacuation of a large hematoma.

Femur-shaft fractures can be associated with acute compartment syndrome and sciatic nerve injuries. However, sciatic nerve injuries are typically acute and unassociated with fixation procedures.<sup>10</sup> In the current case, the presence of compartment syndrome in the patient was felt to be unlikely owing to his moderate pain level that did not increase, initial presentation of neurological symptoms rather than pain, and intraoperative finding of a

large hematoma. Furthermore, we attribute the successful treatment of the palsy to an early diagnosis and evacuation of the hematoma (within 6 hours of onset of symptoms). This notion is consistent with the findings of a similar study by Butt et al<sup>7</sup> on six patients who underwent total hip arthroplasty, in which early diagnosis and evacuation of the hematoma in three patients resulted in complete resolution of symptoms. Sciatic palsy in the other three patients was described as delayed diagnosis, and none had complete resolution of symptoms at 4 years postoperatively.

Sciatic nerve palsy, regardless of the cause, can be a devastating injury. In the short term, it can compromise a patient's ability to participate in rehabilitation<sup>5,7</sup>; in the long term, it may severely affect activities of daily living and return to previous levels of function.<sup>7,9</sup> Our experience supports the existing literature on sciatic nerve palsy and highlights the importance of prompt recognition and treatment in limiting the long-term sequel for patients. Thorough documentation of nerve function in the perioperative period is crucial to guide appropriate treatment. A preexisting palsy or a deficit present immediately upon awakening from anesthesia are unlikely to benefit from exploration of the wound and may expose patients to increased risks associated with further surgical procedures. Conversely, progressive neurologic deficits require consideration for urgent surgical decompression to ensure the best possible outcome.

## Funding

The authors received no financial support for the research, authorship, and publication of this article.

## Conflict of Interest

The authors report no conflicts of interest.

## References

1. Sean NE, Reilly MC. Subtrochanteric fractures of the femur. In: Browner BD, Jupiter JB, Krettek C, Anderson PA, eds. *Skeletal Trauma: Basic Science, Management, and Reconstruction*. 5th ed. Philadelphia, PA: Saunders; 2015:1733-86.
2. Lundy DW. Subtrochanteric femoral fractures. *J Am Acad Orthop Surg* 2007;15(11):663-71.
3. Flierl MA, Stahel PF, Hak DJ, Morgan SJ, Smith WR. Traction table-related complications in orthopaedic surgery. *J Am Acad Orthop Surg* 2010;18(11):668-75.
4. Lhowe DW, Hansen ST. Immediate nailing of open fractures of the femoral shaft. *J Bone Joint Surg Am* 1988;70(6):812-20.
5. Britton JM, Dunkerley DR. Closed nailing of a femoral fracture followed by sciatic nerve palsy. *J Bone Joint Surg Br* 1990;72(2):318.
6. Clarke MT, Arora A, Villar RN. Hip arthroscopy: complications in 1054 cases. *Clin Orthop Relat Res* 2003;(406):84-8.
7. Butt AJ, McCarthy T, Kelly IP, Glynn T, McCoy G. Sciatic nerve palsy secondary to postoperative haematoma in primary total hip replacement. *J Bone Joint Surg Br* 2005;87(11):1465-7.
8. Marsh JL, Slongo TF, Agel J, et al. Fracture and dislocation classification compendium - 2007: Orthopaedic Trauma Association classification, database and outcomes committee. *J Orthop Trauma* 2007;21(10 suppl):S1-S133.
9. Farrell CM, Springer BD, Haidukewych GJ, Morrey BF. Motor nerve palsy following primary total hip arthroplasty. *J Bone Joint Surg Am* 2005;87(12):2619-25.
10. Ojike NI, Roberts CS, Giannoudis PV. Compartment syndrome of the thigh: a systematic review. *Injury* 2010;41(2):133-6. doi:10.1016/j.injury.2009.03.016.

# A New Diagnosis of Multiple Sclerosis in a 29-Year-Old Former Collegiate Basketball Player With Initial Symptoms of Recurrent Bell's Palsy: A Case Report

Eric R. Reynolds, MD<sup>\*</sup>; Andrew D. Ashbaugh, DO<sup>†</sup>; Christopher A. McGrew, MD<sup>†‡</sup>

<sup>\*</sup>Department of Pediatrics, The University of New Mexico Health Sciences Center, Albuquerque, New Mexico

<sup>†</sup>Department of Family & Community Medicine, The University of New Mexico Health Sciences Center, Albuquerque, New Mexico

<sup>‡</sup>Department of Orthopaedics & Rehabilitation, The University of New Mexico Health Sciences Center, Albuquerque, New Mexico

## Abstract

Multiple sclerosis (MS) is a demyelinating disorder of the central nervous system, characterized by immune-mediated destruction of myelinated axons, which leads to notable physical disability. Although presence among active athletes is extremely low, it can cause considerable lifestyle changes for those athletes affected as they transition into life after competitive athletics. We describe a 29-year-old former collegiate women's basketball player in whom MS was diagnosed during a visit for recurrent evaluation of Bell palsy. Subsequent neurology consult and magnetic resonance imaging led to the confirmation of the diagnosis of MS, and the patient began treatment for relapsing-remitting MS. During visits of what appear to be straightforward neurological symptoms, it is imperative to collect a full neurologic history and perform a detailed physical examination to determine whether a more systemic disease process could be at fault, which may subsequently lead to earlier detection and treatment of MS.




## Introduction

Multiple sclerosis (MS) is an immune-mediated, demyelinating disease that affects the central nervous system—leading to considerable physical disability.<sup>1</sup> MS currently affects more than two million people worldwide according to the National Multiple Sclerosis Society, and current estimates state that more than 400,000 individuals are affected in the United States.<sup>1</sup> Recent data show that MS affects more women than men by a two-to-one ratio.<sup>2</sup> Patient age at diagnosis is traditionally between 20 to 50 years.<sup>1</sup>

Numerous hypotheses exist as to which individuals get MS, but most experts agree that it is a combination of genetic and environmental factors. Genetic factors comprise mainly ethnicity and sex, with current research directed toward specific single-nucleotide polymorphisms and histocompatibility complexes.<sup>3,4</sup> Environmental factors include geography and vitamin-D factors (eg, the closer that patients live to the equator, the less likely they are to get MS); additionally, higher levels of vitamin D are thought to be protective against MS.<sup>5-7</sup>

The diagnostic criteria for MS have gradually changed. For the 2010 revision to the McDonald criteria, the goal was to simplify the ability to show lesions in space and time with the help of magnetic resonance imaging (MRI) (Figure 1). MS is typically divided into four categories: relapsing-remitting, secondary progressive, primary progressive, and progressive-relapsing, with relapsing-remitting being the most common criterion.<sup>8</sup>

Treatment of MS is typically divided into acute attacks and disease-modifying agents. Acute attacks are treated with a burst of corticosteroids, whereas disease-modifying agents (including glatiramer acetate, interferon, and natalizumab) are used in attempt to reduce frequency of relapse.<sup>9</sup> We describe diagnosis of MS in a former collegiate athlete who initially had presented with symptoms of Bell's palsy. The patient was informed that the data concerning her case would be submitted for publication, and she provided verbal consent.

  		
Diagnosis of MS requires elimination of more likely diagnoses and demonstration of dissemination of lesions in space (DIS) and time (DIT)*		
CLINICAL (ATTACKS)	LESIONS	ADDITIONAL CRITERIA TO MAKE DX
2 or more	Objective clinical evidence of $\geq 2$ lesions or objective clinical evidence of 1 lesion with reasonable historical evidence of a prior attack	None. Clinical evidence alone will suffice; additional evidence desirable but must be consistent with MS
2 or more	Objective clinical evidence of 1 lesion	DIS; OR await further clinical attack implicating a different CNS site
1	Objective clinical evidence of $\geq 2$ lesions	DIT; OR await a second clinical attack
1	Objective clinical evidence of 1 lesion	DIS OR await further clinical attack implicating a different CNS site AND DIT; OR await a second clinical attack
0 (progression from onset)		One year of disease progression (retrospective or prospective) AND at least two of: DIS in the brain based on $\geq 1$ T2 lesion in periventricular, juxtacortical or infratentorial regions; DIS in the spinal cord based on $\geq 2$ T2 lesions; or positive CSF

\* Polman et al. Diagnostic criteria for multiple sclerosis: 2010 revisions to the McDonald Criteria. *Ann Neurol* 2011;69:292-302. \* See reverse for DIS and DIT

**Figure 1.** The revised diagnostic criteria in 2010 for multiple sclerosis, used by the National Multiple Sclerosis Society. (Diagnostic criteria. National Multiple Sclerosis Society website. <http://www.nationalmssociety.org/For-Professionals/Clinical-Care/Diagnosing-MS/Diagnosing-Criteria>. Accessed February 4, 2017).

## Case Report

A 29-year-old former collegiate basketball player presented to our sports-medicine clinic with concern for Bell's palsy. She had reported that this was the second occurrence of Bell's palsy; she had experienced a similar episode about a year earlier, which resolved after a 5-day treatment of oral corticosteroid. She reported the inability to fully close her left eye since the onset of symptoms, about 7 to 10 days before presentation to our clinic. She also reported some fullness in her right ear. She did not mention any hyperacusis, loss of taste, numbness, tingling of her extremities, or diffuse weakness. She did report some mild blurry vision in her left eye along with some lateral gaze disturbance, but she attributed this to her inability to close the eye fully and said that this was similar to her last bout of Bell's palsy 1 year earlier. Additionally, the patient did not have any recent viral infection of the upper respiratory system or other viral prodrome.

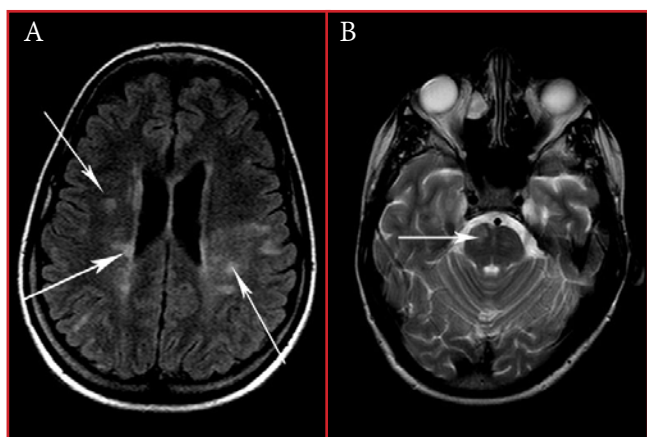
On physical examination, results of the Head, Eye, Ear, Nose and Throat test and neurological examination were remarkable for inability to raise the left eyebrow. Her left eye could only be covered with full, maximal effort. Upon smiling, the left side of her mouth was noted to not raise as much as the right side to produce an asymmetrical smile. Additionally, the patient was noted to have end-gaze nystagmus on both eyes.

The patient was discharged from the clinic with a 5-day, 60-mg prednisone burst for Bell's palsy treatment; however, owing to presence of nystagmus, we consulted our colleagues in neurology for additional recommendations. Neurologists agreed with the current treatment plan and diagnosis because of the lack of other systemic symptoms, but they advised to have a low threshold to get an MRI owing to concern for mass, a tumor of the central nervous system, cavernous sinus aneurysm, or MS.

At 1 week after the initial visit to our clinic, the patient returned for scheduled follow-up. Her facial palsy was improved, but she continued to report lateral gaze disturbance and occasional diplopia, which worsened during lateral gaze. She noted these symptoms the most while playing pick-up basketball and during kickboxing class. While playing basketball, she also suffered from an unusual sluggishness and "couldn't move normally." She did not report any history of diplopia or blurry vision during periods of raised internal temperature. We again discussed the case with neurologists, who recommended to further assess the patient's symptoms with an MRI, magnetic resonance angiography, and additional blood examinations (ie, tests for complete blood count; C-reactive protein levels; erythrocyte sedimentation rate; chemical substance levels; liver function; human immunodeficiency virus; treponema; and antinuclear antibody count). Because of concern for cavernous sinus

aneurysm, the patient was instructed to not work out or do any activities that would raise her blood pressure in the interim.

Results of laboratory studies were remarkable for a mildly elevated creatinine count to 1.16; total bilirubin count of 1.3 (direct, 0.3); and positive antinuclear antibody count, with a titer of less than 1:40. An MRI was obtained on the night of her second clinic visit (Figures 2A and 2B). The image revealed an abnormal moderate amount of scattered areas of cerebral and brainstem T2 prolongation, with distribution and formation suggestive of demyelinating plaques of MS. Multiple areas of T2 prolongation showed postcontrast enhancement. Differential consideration included collagen vascular disease and vasculitis, although this was thought less likely.



**Figure 2.** T2-weighted magnetic resonance imaging at 1 week after initial presentation. A) Abnormal moderate amount of scattered areas of cerebral T2 prolongation, with distribution and morphological features (arrows) suggestive of demyelinating plaques of multiple sclerosis. B) Specific lesion (arrow) of T2 prolongation in the pons, which may explain the patient's symptoms of palsy during lateral gaze.

The patient was referred to a neurology clinic for management of suspected MS. At that visit, the patient reported intermittent numbness of her left calf and left side of her trunk for the past 5 months, which were not reported during her initial visit for Bell's palsy. Her scan was reviewed in detail by the neurologist, who noted that the patient had a lesion on the left side of her pons, near the origin of her sixth and seventh cranial nerves. The presence of the lesion was consistent with the noted lateral gaze palsy, associated diplopia on lateral gaze, and facial nerve paresis. Diagnostic criteria was noted to have been met for MS on the basis of the "MRI, age, response to steroids, and duration of symptoms."

The patient recently underwent treatment with use of Rebif (interferon beta-1a) and vitamin D. At her most recent follow-up, she reported an increase in baseline

left-lower extremity pain and "hotness" during her exercise class. The neurologist recommended that she have an ice-cold beverage with her to prevent a rise in her core body temperature which is known to exacerbate symptoms of MS.

## Discussion

Because MS affects the central nervous system, the disorder can result in severe limitations to physical activity.<sup>1</sup> Although studies have shown benefits from exercise in regards to a patient's "overall functional capacity and psychological well-being" in the presence of MS, the type of exercise should be discussed and exposure to heat should be limited.<sup>10</sup>

The current case fits a typical description of a patient with MS. Our patient was a woman aged 29 years, with an initial attack responding to a burst of steroids and a relapse about 1 year after. Perhaps a more thorough evaluation at her initial clinic visit could have elicited the report of left lower extremity numbness as indicated when she saw the neurologist. However, the sports-medicine physicians correctly suspected a more systemic process; thus, neurologists were consulted immediately. Although recurrent Bell's palsy may occur, it is very rare. In one of the largest studies involving Bell's palsy, it was determined that only 7% of patients had a recurrence, and mean time to recurrence was 10 years.<sup>11</sup>

As such, the findings of this case can serve as a reminder that patients who present with symptoms of Bell's palsy, especially a recurrent symptom, should get a full neurological examination, with specific focus on the timing of symptoms in relation to activity; and an increase in core body temperature.

## Funding

The authors received no financial support for the research, authorship, and publication of this article.

## Conflict of Interest

The authors report no conflicts of interest.

## References

1. Noonan CW, Williamson DM, Henry JP, et al. The prevalence of multiple sclerosis in 3 US communities. *Prev Chronic Dis* 2010;7(1):A12.
2. Who gets MS? (Epidemiology). National Multiple Sclerosis Society website. <http://www.nationalmssociety.org>

- org/What-is-MS/Who-Gets-MS. Accessed February 4, 2017.
3. Nischwitz S, Müller-Myhsok B, Weber F. Risk conferring genes in multiple sclerosis. *FEBS Lett* 2011;585(23):3789-97. doi: 10.1016/j.febslet.2011.03.037.
  4. Yeo TW, De Jager PL, Gregory SG, et al. A second major histocompatibility complex susceptibility locus for multiple sclerosis. *Ann Neurol* 2007;61(3):228-36.
  5. Kampman MT, Brustad M. Vitamin D: a candidate for the environmental effect in multiple sclerosis-observations from Norway. *Neuroepidemiology* 2008;30(3):140-6. doi: 10.1159/000122330.
  6. Munger KL, Levin LI, Hollis BW, Howard NS, Ascherio A. Serum 25-hydroxyvitamin D levels and risk of multiple sclerosis. *JAMA* 2006;296(23):2832-8.
  7. Islam T, Gauderman WJ, Cozen W, Mack TM. Childhood sun exposure influences risk of multiple sclerosis in monozygotic twins. *Neurology* 2007;69(4):381-8.
  8. McDonald WI, Compston A, Edan G, et al. Recommended diagnostic criteria for multiple sclerosis: guidelines from the International Panel on the diagnosis of multiple sclerosis. *Ann Neurol* 2001;50(1):121-7.
  9. Compston A, Coles A. Multiple sclerosis [published erratum in: *Lancet* 2002;360(9333):648]. *Lancet*. 2002 Apr 6;359(9313):1221-31.
  10. Crutchfield KE. Managing patients with neurologic disorders who participate in sports activities. *Continuum (Minneapolis)* 2014;20(6 Sports Neurology):1657-66. doi: 10.1212/01.CON.0000458968.40648.6f.
  11. Pitts DB, Adour KK, Hilsinger RL Jr. Recurrent Bell's palsy: analysis of 140 patients. *Laryngoscope* 1988;98(5):535-40.

# Lipoma of the Tendon Sheath Causing Symptoms of de Quervain's Tenosynovitis: A Case Report

James Rose, MD; Moheb S. Moneim, MD

Department of Orthopaedics & Rehabilitation, The University of New Mexico Health Sciences Center, Albuquerque, New Mexico

## Abstract

Deep lipomas arising from the extensor compartments of the wrist are extremely rare. Owing to infrequent presentation and mass effect on nearby structures, lipomas can be mistaken for other clinical entities. We describe a 70-year-old woman who presented to our clinic with symptoms initially suggestive of de Quervain's tenosynovitis of the left wrist. However, findings of physical examinations and imaging techniques revealed a lipoma of the tendon sheath of the second dorsal compartment. The patient was successfully treated operatively, with excision and release of the first dorsal compartment. To help accurately diagnosis and treat lipomas of the wrist in deep-tissue areas—with symptoms initially similar to de Quervain's tenosynovitis—surgeons should consider performing thorough physical examinations and, if needed, magnetic resonance imaging.

## Introduction

Lipomas are benign adipose tumors. They are the most common benign soft-tissue tumor,<sup>1</sup> particularly in the hands and forearm.<sup>2</sup> Lipomas typically arise in the subcutaneous tissues and rarely appear within deeper layers such as the deep palmar spaces, extensor tendon sheaths, and perineural zones in the hand and forearm.<sup>3,4</sup>

Despite their benign nature, lipomas of the wrist and hand have been associated with a high potential for compression of surrounding structures owing to the musculoskeletal density of those regions.<sup>3,5</sup> To our knowledge, no reports have noted a lipoma in or adjacent to other wrist-extensor compartments. We describe a 70-year-old woman with a deep lipoma of the second-extensor compartment of the wrist, with initial symptoms of de Quervain's tenosynovitis. The patient was informed that the data concerning the case would be submitted for publication, and she provided verbal consent.

## Case Report

A 70-year-old, right-hand dominant, retired woman presented with a mass on the dorsum of the distal aspect of her left forearm. The mass had been slowly enlarging for 3 years. Initially, the mass was painless; however, in the month before presentation, the patient described pain over the dorsal radial aspect of the wrist. Findings in her medical history and the noted distribution of pain were suggestive of de Quervain's tenosynovitis. She did not report symptoms of de Quervain's tenosynovitis before mass enlargement.

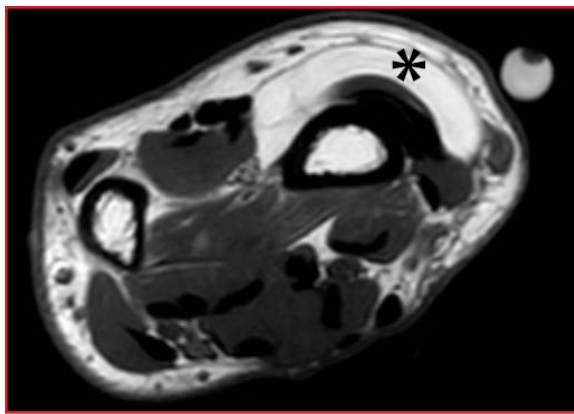
Results of physical examinations revealed a soft, rubbery, mobile mass on the dorsoradial aspect of the wrist, arising proximal to the radial styloid. The patient exhibited tenderness to palpation over the tendons of the first dorsal compartment, with a positive Finkelstein maneuver. She had no positive Tinel sign over her superficial radial sensory nerve and no sensory deficits in the hand. The wrist and hand exhibited normal range of motion, with mild pain upon terminal wrist flexion and extension.

Plain radiographs of the wrist showed no abnormalities, except for incidental age-related degenerative changes. Because of the presence of the mass on physical examination, an MRI with and without contrast was obtained which demonstrated a 2.7 x 4.1 cm non-enhancing, septated mass consistent with lipoma (Figure 1). This appeared to arise from within the tendon sheath of the second extensor, just proximal to the extensor retinaculum. The mass proceeded proximally and superficially, situated in the distal forearm above the outcropper muscles that crossed toward the first dorsal compartment. The abductor pollicis longus (APL) and extensor pollicis brevis (EPB) tendons distally showed radiographic signs of tendinitis. The radial styloid also showed high T2-weighted signal consistent with bony edema.

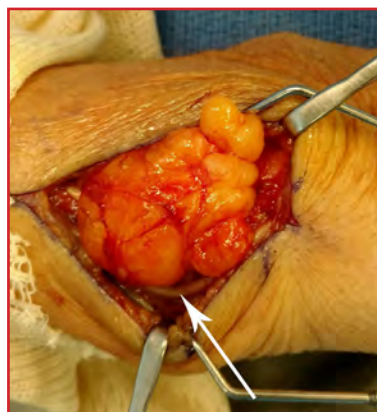During operative treatment, an oblique incision was made over the course of the mass. No lipomatous tissue was found in the subcutaneous adipose layer. The

superficial radial nerve was identified and protected (Figure 2). A thickened capsule was encountered and entered overlying a large, lobulated yellow mass consistent with lipoma. At its proximal extent, this mass extended superficial to and compressed the APL and EPB (“outcropper”) muscle bellies, as indicated by the MRI (Figure 3). The mass was somewhat adherent to the underlying muscle and, upon distal dissection, appeared to originate around the tendons of the second extensor tendon compartment in the wrist. It was excised as a single unit and sent to the pathology department for histological analysis, which confirmed the diagnosis of lipoma. Although the symptoms may have resolved without compartment release, we decided to release the first dorsal compartment intraoperatively to ensure complete relief of symptoms and avoid any residual discomfort or revision procedures.

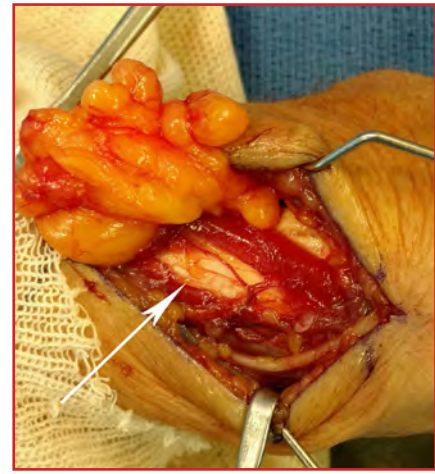At 2 weeks postoperatively, the patient returned for follow-up. Her symptoms of first dorsal compartment compression had resolved. Her wound was healing well and she did not experience any pain.



**Figure 1.** Axial magnetic resonance imaging, showing the lipoma’s origin (asterisk) within the second dorsal compartment and its mass effect on the outcropper muscles.



**Figure 2.** Lobulated lipomatous mass immediately deep to capsule. Superficial radial nerve is visible (arrow) at the inferior aspect of the dissection.



**Figure 3.** Lipomatous mass reflected after dissection to illustrate compressive effect on crossing muscle fibers of the abductor pollicis longus and extensor pollicis brevis (arrow).

## Discussion

Deep lipomas of the upper extremities are relatively rare, tendon sheath lipomas of the upper extremity are extremely rare, and extensor tendon sheath lipomas of the hand and wrist are nearly unreported. To our knowledge, no study has described a deep lipoma with symptoms similar to those of de Quervain’s tenosynovitis owing to compression on the APL and EPB muscle bellies.

Leffert<sup>5</sup> reviewed 141 lipomas of the upper extremity and noted six patients with compressive neuropathy and 26 with local pain caused by compression from adjacent lipomas. In a study of 13 lipomas of the forearm, wrist, and hand by Nadar et al.,<sup>3</sup> multiple instances of neuropathy and compression-related muscle pain were described; furthermore, extensive neurolysis was often required owing to the perineural location of the tumor. Gurich and Pappas<sup>3</sup> recently described a lipoma of the fourth extensor compartment of the wrist, causing compressive pain and stiffness with finger extension.

In the current case, the associated diagnosis of lipoma was clear after superficial tracking and a subsequent clinically apparent dorsal mass; however, our patient was a slender, elderly woman (body mass index, 23 kg/m<sup>2</sup>) with a relatively small amount of muscle mass. In an obese patient, or one with notably more muscle bulk about the forearm, the diagnosis would have been easier to miss.

Of note, the lipoma did not track distally into the first dorsal compartment at the wrist, and therefore a standard limited open surgical approach to release the tendons of the first dorsal compartment would not have revealed it. We believe the lipoma caused or contributed to the symptoms of radial sided wrist pain by irritating the APL and EPB tendons proximal to the retinaculum and needed



to be excised in combination with first dorsal compartment release in order to relieve these symptoms. Clinicians should be aware of a potential proximal compressive origin in what appear to be symptoms of de Quervain's tenosynovitis and perform a careful physical examination with, if needed, MRI.

## Funding

The authors received no financial support for the research, authorship, and publication of this article.

## Conflict of Interest

The authors report no conflicts of interest.

## References

1. Higgins JC, Maher MH, Douglas MS. Diagnosing common benign skin tumors. *Am Fam Physician* 2015;92(7):601-7.
2. Calandruccio JH, Jobe MT. Tumors and tumorous conditions of the hand. In: Canale ST, Beaty JH, eds. *Campbell's Operative Orthopaedics*. 11th ed. Philadelphia, PA: Mosby Elsevier; 2008: chap 74.
3. Nadar MM, Bartoli CR, Kasdan ML. Lipomas of the hand: a review and 13 patient case series. *Eplasty* 2010;10:e66.
4. Gurich RW Jr, Pappas ND. Lipoma of the tendon sheath in the fourth extensor compartment of the hand. *Am J Orthop (Belle Mead NJ)* 2015;44(12):561-2.
5. Leffert RD. Lipomas of the upper extremity. *J Bone Joint Surg Am* 1972;54(6):1262-6.

# Diagnosing an Acute Quadratus Plantae Tear in a 37-Year-Old Athlete: A Case Report

James P. Toldi, DO\*; Shane P. Cass, DO\*; Richard A. Miller, MD†; Christopher A. McGrew, MD\*\*†

\*Department of Family & Community Medicine, The University of New Mexico Health Sciences Center, Albuquerque, New Mexico

†Department of Orthopaedics & Rehabilitation, The University of New Mexico Health Sciences Center, Albuquerque, New Mexico

## Abstract

Foot injuries occur frequently in distance runners and can notably impact training performance. Common diagnoses include plantar fasciitis, tendinopathies of the forefoot or midfoot, and stress fractures of the metatarsals. Occasionally, more obscure structures may be involved. We describe a 37-year-old male distance runner who presented with symptoms of heel pain and ecchymosis, suggesting an acute plantar fascia injury. However, findings of magnetic resonance imaging revealed a tear to the quadratus plantae (QP). The patient gradually returned to normal levels of physical activity, with complete resolution of symptoms by 4 months after the initial injury. Healthcare providers should be aware of the possible presence of a QP tear in patients who present with symptoms suggestive of acute plantar fascia rupture.

## Introduction

Lower-extremity injuries are frequent in both elite and recreational runners.<sup>1</sup> The foot is the third most common location for injury,<sup>2</sup> with plantar fasciitis being the most common foot problem. Traditional imaging for running-related foot injuries has primarily involved standard radiographs, magnetic resonance imaging (MRI), computerized axial tomography scans, and less commonly nuclear-medicine scanning. Musculoskeletal ultrasound has become an increasingly more common choice in the past decade.<sup>3</sup> Challenges exist for advocates of using musculoskeletal ultrasound, including determining the imaging accuracy and reliability compared to traditional imaging and demonstrating improved outcomes and more efficient return to play. Furthermore, diagnostic challenges occur when less-common structures such as the quadratus plantae (QP) muscle are involved.

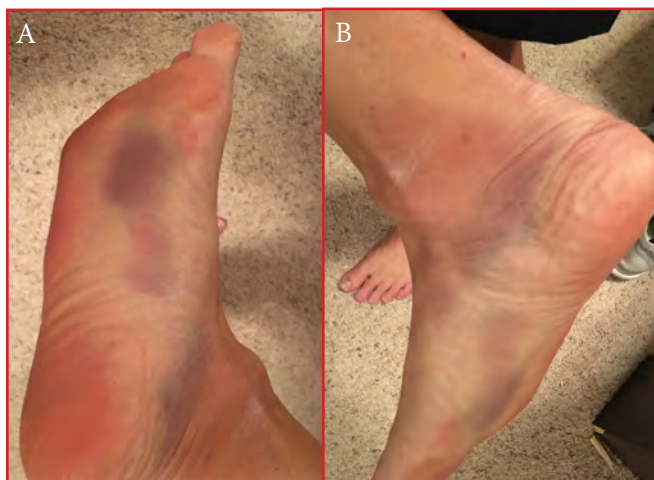We describe a 37-year-old distance runner who presented with symptoms and bedside musculoskeletal ultrasound imaging suggestive of an acute plantar fascia tear in his right heel, yet MRI findings revealed the presence of a QP tear. We found no published case report of specific tearing or strain injuries to the QP, although the structure is affected in hind-foot compartment syndrome after calcaneal fractures.<sup>4-6</sup> The patient was informed that the data concerning his case would be submitted for publication, and he provided verbal consent.

## Case Report

A 37-year-old male runner presented to the sports medicine clinic with 3 days of right-heel pain, which began acutely near the beginning of his morning run. He ignored the pain and finished his 10-mile run (16.1 km). After the run, he self-treated with stretching, ice, and 800 mg of ibuprofen, but his pain continued throughout the day. The next morning, the patient noticed considerable bruising along the plantar aspect of his foot and medial ankle (Figures 1A and 1B). He also experienced paresthesias and burning pain in the lateral foot and two toes, with prolonged ambulation that diminished with rest. He was an otherwise healthy individual, with no chronic conditions, regular medications, pre-existing foot injuries, or corticosteroid injections.

Results of his physical examination showed an antalgic gait, with noted exaggerated supination and avoidance of push-off on great toe by placing all of his weight on the outside of his foot during ambulation. Static inspection revealed bilateral pes planus. There was extensive ecchymosis on the medial plantar surface of the foot, originating about 5 cm distally from the medial aspect of the calcaneus, and prominent ecchymosis posterior to the medial malleolus. Neurovascular structures were intact. The ankle had complete range of motion, and results of the

Tinel test over the tarsal tunnel were negative. There was pinpoint tenderness over the medial plantar aspect of the calcaneus near the attachment of the plantar fascia.



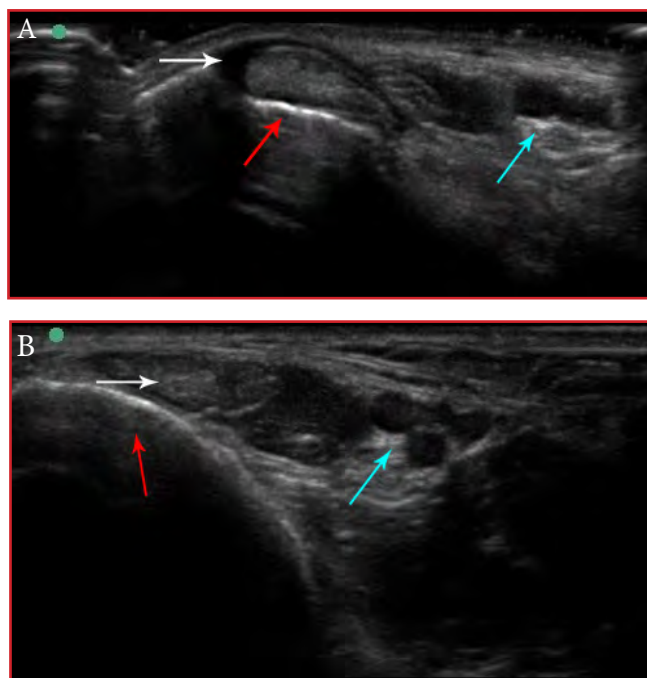
**Figure 1.** The patient's right foot at 36 hours after the initial injury. (A) The plantar aspect of the foot. (B) The medial aspect of the ankle.

Bedside ultrasound examination showed a small anechoic fluid collection around the posterior tibialis tendon at the ankle (Figure 2A) and a large anechoic fluid collection inferior to the plantar fascia, near the insertion on the calcaneus, consistent with signs of hematoma (Figure 2B). A possible partial tear of the medial band of the plantar fascia was present at the calcaneal insertion. An MRI at 2 weeks after the injury showed edema and high signal within the proximal QP muscle near the calcaneal insertion (Figures 3A and 3B), consistent with a partial QP tear. The plantar fascia was non-ruptured.

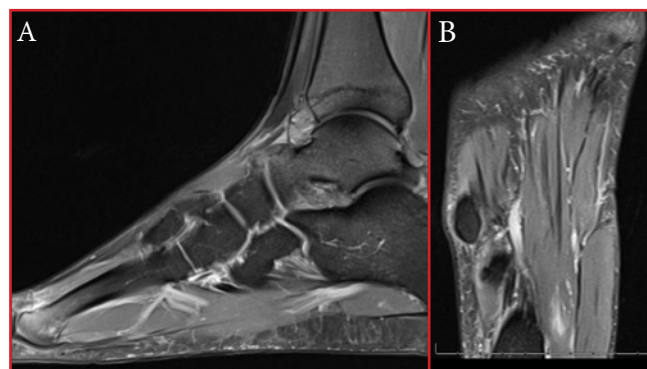
Many of the patient's initial symptoms were observed as a result of Baxter neuropathy from extensive edema and hematoma. At initial presentation, the patient was placed in a walking boot for 2 weeks and underwent daily soft-tissue therapy treatments and modalities. The patient was allowed to gradually increase his level of activity and resume stretching. At the 30-day point, he was pain free, could walk, and began short runs. Serial ultrasound imaging, obtained weekly, showed some resolution of hematoma formation within the QP (Figures 4A through 4C).

Resolution of the anechoic fluid signal around the posterior tibialis at 2 weeks after the injury was noted in repeat ultrasonography examinations (Figure 2B). Around the QP, the fluid collection decreased in size at that time (Figure 4B). Ultrasound was obtained before resuming workouts and at 1 week after return to running (Figure 4C). The ultrasounds had similar findings, with a small fluid collection remaining; however, the size of the collection did not increase and pain did not return with the initiation of training. At 4 months after the injury, we noted

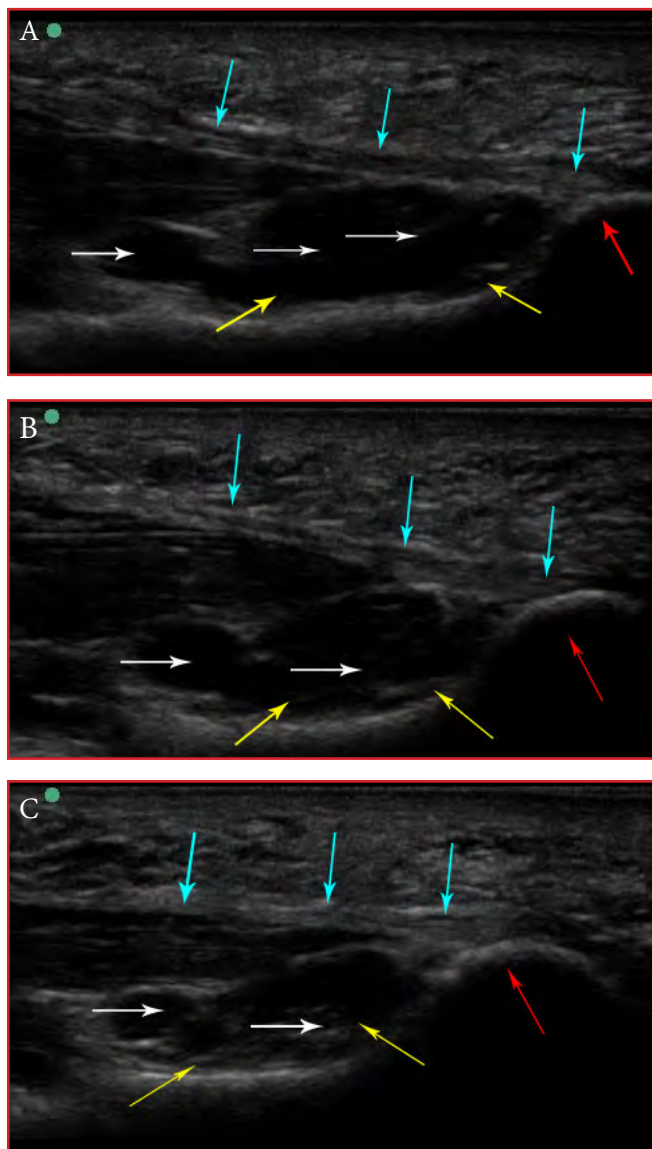
resolution of the original hematoma around the QP and the anechoic fluid collection around the posterior tibialis tendon, with no recurrent symptoms despite a regular running-training routine.



**Figure 2.** Ultrasound of the posterior tibialis, showing short-axis view and the medial malleolus (red arrow) and tibial neurovascular bundle (blue arrow). (A) Findings of initial scanning noted anechoic fluid (white arrow) around the tendon. (B) At 1-week after initial scanning, findings indicate resolving fluid (white arrow) around the tendon.



**Figure 3.** Magnetic resonance imaging of the quadratus plantae, showing signs of edema (arrows). (A) Sagittal view. (B) Axial view.



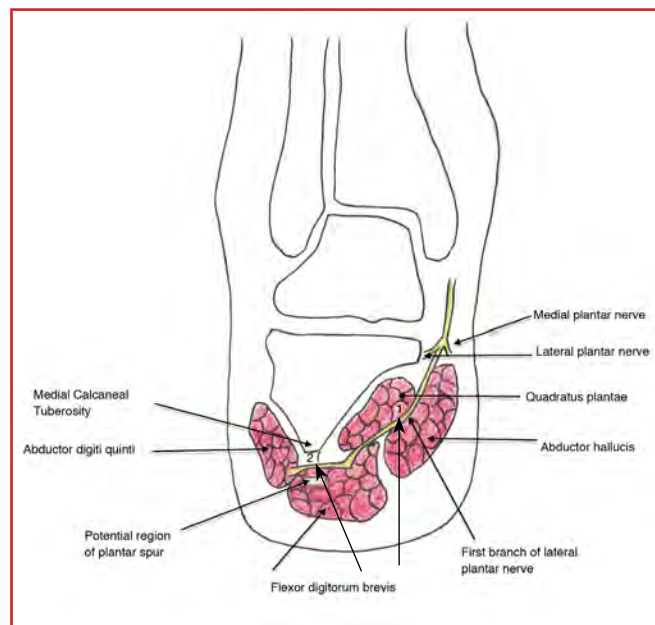
**Figure 4.** Ultrasound of the quadratus plantae (yellow arrows), showing long-axis view and the medial calcaneous (red arrow) and plantar fascia (blue arrows). (A) Anechoic fluid collection (white arrows) extending from the calcaneus, indicating evolving hematoma. (B) Same view at 1 week later, showing that the anechoic fluid collection stopped tracking distally (white arrows) and the hematoma has become more defined. (C) Same view at 4 weeks later, showing that the hematoma has notably reduced in size and the anechoic fluid has become more heterogeneous (white arrows).

## Discussion

We believe this to be the first case report of a QP injury involving an acute injury with a tendon tear and strain. Among podiatrists and chiropractors, QP injury is known as a masquerader of plantar fascia injury. It is typically treated conservatively in a similar manner to that of a plantar fascia injury (ie, treated with rest, ice, nonsteroidal anti-inflammatory drug, and a period of immobilization

accompanied by soft-tissue modalities, stretching, and intrinsic foot-muscle strengthening exercises).

The QP is an intrinsic muscle of the foot, which is innervated by the first branch of the lateral plantar nerve (Baxter's nerve) and aids in plantar flexion of the four lateral toes. Additionally, Baxter's nerve innervates the flexor digitorum brevis and abductor digiti quinti, and sends sensory fibers to the periosteum of the medial calcaneal tuberosity, lateral plantar skin, and long plantar ligament. Baxter's nerve lies deep to the abductor hallucis and flexor digitorum brevis, and superficial to the QP (Figure 5). Bleeding into the QP can lead to compression of the lateral plantar nerve between the flexor digitorum brevis and QP, leading to symptoms of Baxter's neuropathy, with pain at the medial heel and burning pain in the lateral foot.<sup>7,8</sup> Compartment syndrome of the midfoot, which can mimic Baxter's neuropathy, can lead to the devastating complications of paresis and ischemic contracture of the short flexors of the toes, resulting in hammer- or claw-toe deformity.<sup>4</sup>



**Figure 5.** Illustration of a left heel showing the potential sites of compression of the Baxter nerve: the deep margin of the abductor hallucis muscle (1) and the point at which the nerve passes anterior to the medial calcaneal tuberosity (2). Adapted from: Lareau CR, Sawyer GA, Wang JH, DiGiovanni CW. Plantar and medial heel pain: diagnosis and management. *J Am Acad Orthop Surg* 2014;22(6):372-80.

Fortunately for our patient, the symptoms were only present with prolonged ambulation and were completely resolved with rest. Had his symptoms been more persistent, this would have warranted a referral for evaluation by a surgeon specializing in the foot and ankle. It has also been shown that the QP has fascia connections to other midfoot structures and to the posterior compartment of

the leg through the retinaculum posterior to the medial malleolus.<sup>7,8</sup> Thus, bleeding into the QP can lead to hematoma formation in both of those locations. This may account for the external bruising pattern seen in our case.

Initial bedside ultrasound indicated an acute injury, mistaken for a plantar fascia tear. Subsequently, an MRI accurately diagnosed the QP injury. After MRI, the ultrasonographer refined his technique and felt that the QP could be imaged. Scanning protocols from the American Institute of Ultrasound Medicine do not address QP injuries.<sup>9</sup> Ultrasound findings were used to monitor hematoma resolution while our patient returned to activity. Radwan et al<sup>10</sup> suggested that ultrasound could monitor improvement and disease process after rehabilitation interventions. However, at this time, routine musculoskeletal ultrasound monitoring for management is not supported.<sup>11</sup>

There is no clear indication that either the treatment or the time to return to running with this patient's injury—a partial QP tear—would have been any different if the injury had been a plantar fascia tear. As described in the current case report, it should be noted that the learning curve is longer for diagnosing atypical and uncommon injuries such as QP tears with ultrasound than the more common structures such as an acute plantar fasciitis injury.

## Funding

The authors received no financial support for the research, authorship, and publication of this article.

## Conflict of Interest

The authors report no conflicts of interest.

## References

1. Kindred J, Trubey C, Simons SM. Foot injuries in runners. *Curr Sports Med Rep* 2011;10(5):249-54. doi: 10.1249/JSR.0b013e31822d3ea4.
2. van Gent RN, Siem D, van Middelkoop M, van Os AG, Bierma-Zeinstra SM, Koes BW. Incidence and determinants of lower extremity running injuries in long distance runners: a systematic review. *Br J Sports Med* 2007;41(8):469-80; discussion 480.
3. Jacobson JA. Musculoskeletal ultrasound and MRI: which do I choose? *Semin Musculoskelet Radiol* 2005;9(2):135-49.
4. Andermahr J, Helling HJ, Tsironis K, Rehm KE, Koebke J. Compartment syndrome of the foot. *Clin Anat* 2001;14(3):184-9.
5. Manoli A 2nd, Weber TG. Fasciotomy of the foot: an anatomical study with special reference to release of the calcaneal compartment. *Foot Ankle* 1990;10(5):267-75.
6. Andermahr J, Helling HJ, Rehm KE, Koebke Z. The vascularization of the os calcaneum and the clinical consequences. *Clin Orthop Relat Res* 1999;(363):212-8.
7. Sooriakumaran P, Sivananthan S. Why does man have a quadratus plantae? A review of its comparative anatomy. *Croat Med J* 2005;46(1):30-5.
8. Lareau CR, Sawyer GA, Wang JH, DiGiovanni CW. Plantar and medial heel pain: diagnosis and management. *J Am Acad Orthop Surg* 2014;22(6):372-80. doi: 10.5435/JAAOS-22-06-372.
9. American College of Radiology (ACR).; Society for Pediatric Radiology (SPR).; Society of Radiologists in Ultrasound (SRU). AIUM practice guideline for the performance of a musculoskeletal ultrasound examination. *J Ultrasound Med* 2012;31(9):1473-88.
10. Radwan A, Wyland M, Applequist L, Bolowsky E, Klingensmith H, Virag I. Ultrasonography, an effective tool in diagnosing plantar fasciitis: a systematic review of diagnostic trials. *Int J Sports Phys Ther* 2016;11(5):663-671.
11. Klauser AS, Tagliafico A, Allen GM, et al. Clinical indications for musculoskeletal ultrasound: a Delphi-based consensus paper of the European Society of Musculoskeletal Radiology. *Eur Radiol* 2012;22(5):1140-8. doi: 10.1007/s00330-011-2356-3.

# Unsuccessful Metatarsophalangeal Joint Replacement for Treating Arthritis of the Great Toe: Report of Three Cases

Jory Wasserburger, MD; Paul J. Johnson, MD; Katherine J. Gavin, MD;  
Richard A. Miller, MD

Department of Orthopaedics & Rehabilitation, The University of New Mexico Health Sciences Center,  
Albuquerque, New Mexico

## Abstract

Metatarsophalangeal (MTP) joint fusion or replacement are commonly performed for treating advanced arthritis of the MTP joint of the great toe. However, results of MTP joint arthroplasty have shown no clear advantages compared to those of fusion. We present a 72-year-old woman (case 1), 66-year-old woman (case 2), and 64-year-old man (case 3) who underwent unsuccessful MTP joint replacement of the great toe and presented to our clinic with pain at 15, 1, and 20 years postoperatively, respectively. Operative resection has been scheduled for case 1, whereas symptoms were managed nonoperatively in case 2. In case 3, operative removal of the prosthesis and fusion led to resolution of symptoms at 6-month follow-up, but a nonunion was noted. Although MTP joint arthroplasty can be helpful for treating joints such as in the knee, surgeons should consider other operative procedures for treating MTP joint arthritis of the great toe.

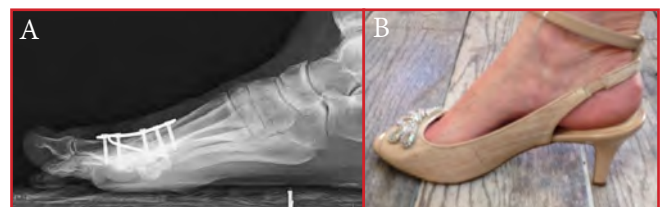## Introduction

Metatarsophalangeal (MTP) joint fusion and joint replacement are the most common surgical procedures for treating advanced arthritis of the MTP joint of the great toe. MTP joint fusion has been found to result in pain relief and minimal activity limitation.<sup>1,2</sup> Treated patients can run, bike, and play sports (Figures 1A and 1B). Despite successful results associated with MTP fusion, patients often undergo MTP joint replacement instead. However, treatment outcomes after MTP joint replacement have shown no improvement in function compared with those of MTP joint fusion.<sup>2</sup>

Although treatment with MTP joint replacement can result in retained motion at the MTP joint, high rates of prosthesis failure and unsuccessful subsequent procedures have been described.<sup>1</sup> The prosthesis has been

noted to break, loosen, and dislocate, which causes pain. Furthermore, reconstruction procedures performed after unsuccessful MTP joint replacement have less satisfactory results than those of primary MTP joint fusion. These outcomes are probably owing to loss of first ray length, transfer metatarsalgia, and difficulty in obtaining a fusion after removal of the failed prosthesis. An intercalary bone graft is sometimes required to compensate for the bone loss and resulting defect after removal of the failed prosthesis.<sup>1</sup>

We describe three patients who presented to our clinic after undergoing unsuccessful MTP joint replacement, which were performed at outside institutions. We report on implant loosening, dislocation, and continued pain associated with MTP joint replacement. The patients were informed that the data concerning the case would be submitted for publication, and they provided verbal consent.



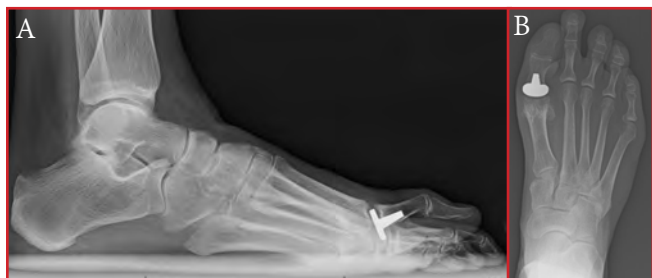**Figure 1.** A patient who underwent metatarsophalangeal (MTP) joint fusion of her great toe. A) Lateral view of a properly positioned MTP joint fusion, showing about 10° of dorsiflexion relative to the floor. B) The patient can walk using 2.5-inch high-heels.

## Case Reports

### Case 1

A 72-year-old woman presented to our clinic at 15 years after undergoing MTP joint hemiarthroplasty for treating arthritis of her great toe. The base of the proximal phalanx had been replaced with a metallic implant. The patient indicated that her pain was not resolved after operative treatment. She developed increased pain in the 3 years

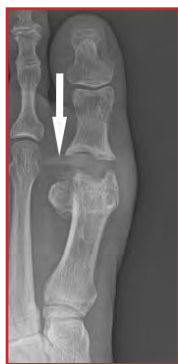after the surgery, without any history of injury. Her great toe became extended and overlapped her second toe. She had almost no motion in the joint and felt pain with any attempt to move it. The second toe appeared shortened. Radiographs showed loosening of the prosthesis, with impingement and erosion of the first metatarsal head (Figures 2A and 2B). Our team discussed treatment options with the patient, including implant removal and possible revision to arthrodesis. At the time of this article, the definitive treatment plan is still being decided.



**Figure 2.** Radiographs of the right foot in case 1, obtained at presentation to our clinic and 1 year after initial treatment. A) Lateral view, showing loose metatarsophalangeal joint hemiarthroplasty that impinges on the first metatarsal head, resulting in pain and limited motion. The dorsal portion of the prosthesis is eroding the first metatarsal head. B) Anteroposterior radiograph demonstrating shortening of the great toe which is overlapping the second toe.

### Case 2

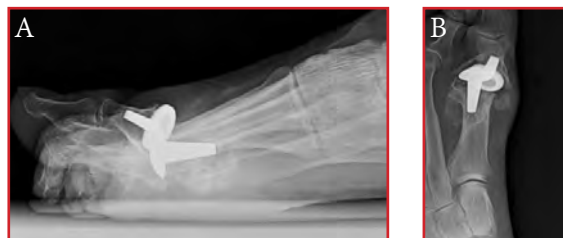A 66-year-old woman presented to our clinic at 1 year after undergoing silastic implant replacement of the great toe MTP joint for treating arthritis. She had pain and a sensation of fullness in the region of the joint. Her toe was shortened with mild extension and limited motion. Radiographs revealed that one limb of the prosthesis had dislocated from its position within the bone and was facing laterally toward the second metatarsal head (Figure 3). Her symptoms were managed with activity modification and orthotics.



**Figure 3.** Radiograph in case 2, obtained 15 years after metatarsophalangeal (MTP) joint hemiarthroplasty for treating arthritis. Shows dislocated and possibly broken limb of prosthesis at the MTP joint (arrow).

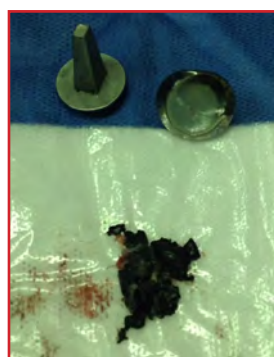### Case 3

A 64-year-old man presented to our clinic after undergoing replacement of the great toe MTP joint, using a two-piece prosthesis, for treating arthritis. The prosthesis had been placed more than 20 years previously. At an unknown point in time, the replacement prosthesis had dislocated, and the great toe was stuck in an extended position (Figures 4A and 4B). The position of the great toe resulted in an altered gait and pain.

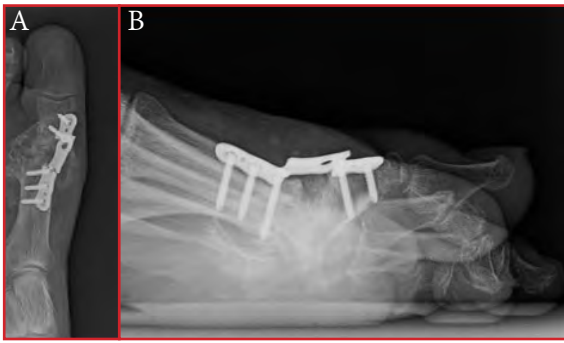


**Figure 4.** Radiographs in case 3, obtained 20 years after metatarsophalangeal joint replacement of the great left toe. Shows bone erosion and dorsal dislocation of the great toe replacement prosthesis. A) Anteroposterior view. B) Lateral view.

The patient underwent removal of the prosthesis and fusion. Intraoperatively, metallic debris was found throughout the soft tissues of the great toe MTP joint (Figure 5). Bone allograft was used to fill the void created by the initial placement of the prosthesis. At 6-month follow-up, the fusion plate had broken and a nonunion existed (Figures 6A and 6B). However, the patient felt that his symptoms were resolved and that the toe position was more aligned with the metatarsal.



**Figure 5.** The removed prosthesis and metallic debris, which were found intraoperatively in case 3.



**Figure 6.** Radiographs at 6 months postoperatively in case 3. Shows failure of attempted great toe fusion with broken plate and screws, with the difficulty in obtaining a fusion after metatarsophalangeal joint replacement owing to bone loss from the prosthesis. A) Anteroposterior view. B) Lateral view.

## Discussion

First MTP joint replacement was conceived as a potential alternative to joint arthrodesis, with the goal of maintaining the natural mechanics and motion of the great toe. Results of studies on these two treatment options have indicated more success with MTP joint fusion than replacement in clinical outcome and need for revision procedures.<sup>2-7</sup>

One study in the Netherlands prospectively analyzed the functional result in 62 patients undergoing first MTP joint arthrodesis.<sup>2</sup> Patients with concomitant operative treatment on the same or uninjured foot, inflammatory arthritis, or previous fusion using another technique were excluded. The authors found noted a high fusion rate (95%), an increase in function, and a decrease in pain after cross-screw arthrodesis.

Duncan et al<sup>3</sup> reported the retrospective outcome data from a series of arthroplasty procedures using ToeFit-Plus (Smith & Nephew, London, UK) performed between 2006 and 2011. A total of 69 MTP joint arthroplasties were performed in 57 patients with at least 6-month follow-up. Six revisions were performed: two for treating symptomatic and progressive osteolysis; one for treating restricted range of motion associated with pain; and another that was dorsally dislocating. Radiolucency was noted to be seen in 23 cases, giving the concern for potential future loosening of implants. In a follow-up study<sup>4</sup> of the same implant, a total of 86 arthroplasties in 73 patients were assessed in the same manner. Postoperative American Orthopaedic Foot and Ankle Society (AOFAS) scoring improved; however, a 24% revision rate was seen owing to implant loosening, progressive radiographic lucency, fracture, infection, and dislocation. Although the authors reported excellent outcomes in the successful arthroplasties, the unacceptably high revision rate forced the discontinuation of the ToeFit-Plus system.

A series by Dawson-Bowling et al<sup>5</sup> studied a different MTP joint arthroplasty system. The MOJE ceramic implant (Petersberg, Germany) was used during 32 procedures in 30 patients throughout a 6-year period. Postoperatively, the patients were found to have mid-range functional scores. Range of motion was also assessed, with 15 patients having poor (< 36), nine with moderate (36-45), four with good (46-60), and one with excellent (> 60) range of motion. There was a 77% rate of either loosening or revision, leading the authors to believe in the superiority of arthrodesis compared with joint replacement.

To our knowledge, only one series<sup>6</sup> directly compared arthrodesis and total replacement arthroplasty.<sup>6</sup> Sixty-three patients with first MTP joint pain recalcitrant to conservative measures were recruited and randomly selected to undergo arthrodesis or MTP joint arthroplasty using an unconstrained BIOMET. Patients with arthrodesis did not have increased loading on the lateral side of their foot. In contrast, patients with arthroplasty had increased rates of lateral loading and transfer metatarsalgia. Arthroplasty was found to be more expensive than arthrodesis, with a cost of £4025 and £1980, respectively. The authors concluded arthrodesis resulted in decreased pain, better functional outcomes, decreased cost, and lower complication rates when compared to arthroplasty. The authors also concluded that the high early revision rate was unacceptable, and recommended against MTP joint arthroplasty.

Finally, Brewster<sup>7</sup> investigated the outcomes of MTP joint arthroplasty versus arthrodesis, using a systematic retrospective review of the literature. The average follow-up in months were 27.8 for the arthroplasty group and 48.8 for the arthrodesis group. The median revision rate was 7% for arthroplasty and 0% for arthrodesis. The average AOFAS score after arthroplasty and arthrodesis was 83 and 82, respectively. However, the author expressed that the increased complication rate, expense, and long-term revision rate of arthroplasty made arthrodesis a more sensible option in the treatment of great toe MTP joint arthritis.

In case 1, we could not report patient outcomes after revision procedure because the patient has not yet decided. In case 2, the patient elected against a revision procedure because she experienced considerable relief from activity modification and orthotics. Results of the first two cases show morbidity associated with the failure of these implants. In case 3, the implant in the patient was removed and the joint was debrided; although his revision treatment was unsuccessful, the symptoms completely resolved. This is likely owing to the correction of the great toe deformity, which had developed because of the failed implant, and the removal of the reactive implant. Results of case 3 also



show the technical difficulty that surgeons face regarding revision procedures of failed MTP arthroplasty. This can lead to poor patient satisfaction and higher costs associated with treatment.

When patients present with end-stage first MTP arthritis, the condition is treated conservatively at first with shoe modifications, orthotics, and activity modification. If these fail, surgical options are discussed with the patients. Patient demographics can affect surgical treatments offered, but we routinely discuss all available options. The senior author favors arthrodesis but will recommend arthroplasty if preferred by the patient after discussing the current evidence-based medicine. More recent patient discussions have involved use of new polyvinyl alcohol implants (Cartiva, Alpharetta, GA). The senior author did not perform this procedure at the time of this article, and available studies on the topic are short term.

In patients with first MTP arthritis, pain-free range of motion is a treatment goal that replacement arthroplasty has addressed and a concept that has fared well with other joints in the body such as the knee and hip. However, findings of the current case report support other studies with findings suggesting that the risks of first MTP joint arthroplasty outweigh the benefits when compared to arthrodesis of the same joint.<sup>5-7</sup> Implant failure, aseptic loosening, transfer metatarsalgia, hardware failure, infection, and persistent pain are all problems with great toe implant arthroplasty. In operatively treating MTP joint arthritis of the great toe, surgeons should consider other methods before performing MTP joint arthroplasty.

## Funding

The authors received no financial support for the research, authorship, and publication of this article.

## Conflict of Interest

The authors report no conflicts of interest.

## References

1. Gross CE, Hsu AR, Lin J, Holmes GB, Lee S. Revision MTP arthrodesis for failed MTP arthroplasty. *Foot Ankle Spec* 2013;6(6):471-8. doi: 10.1177/1938640013502725.
2. van Doeselaar DJ, Heesterbeek PJ, Louwerens JW, Swierstra BA. Foot function after fusion of the first metatarsophalangeal joint. *Foot Ankle Int* 2010;31(8):670-5. doi: 10.3113/FAI.2010.0670.
3. Duncan NS, Farrar NG, Rajan RA. Early results of first metatarsophalangeal joint replacement using the ToeFit-Plus™ prosthesis. *J Foot Ankle Surg* 2014;53(3):265-8. doi: 10.1053/j.jfas.2014.01.008.
4. Titchener AG, Duncan NS, Rajan RA. Outcome following first metatarsophalangeal joint replacement using TOEFIT-PLUS™: a mid term alert. *Foot Ankle Surg* 2015;21(2):119-24. doi: 10.1016/j.jfas.2014.10.005.
5. Dawson-Bowling S, Adimonye A, Cohen A, Cottam H, Ritchie J, Fordyce M. MOJE ceramic metatarsophalangeal arthroplasty: disappointing clinical results at two to eight years. *Foot Ankle Int* 2012;33(7):560-4. doi: 10.3113/FAI.2012.0000.
6. Gibson JN, Thomson CE. Arthrodesis or total replacement arthroplasty for hallux rigidus: a randomized controlled trial. *Foot Ankle Int* 2005;26(9):680-90.
7. Brewster M. Does total joint replacement or arthrodesis of the first metatarsophalangeal joint yield better functional results? A systematic review of the literature. *J Foot Ankle Surg* 2010;49(6):546-52. doi: 10.1053/j.jfas.2010.07.003.

# Rare Tumors Adjacent to the Achilles Tendon: Report of Two Cases

Jay J. Wojcik, MD\*; Aditi S. Majumdar, MD\*; Kathleen M. Madden, MD†; Richard A. Miller, MD\*

\*Department of Orthopaedics & Rehabilitation, The University of New Mexico Health Sciences Center, Albuquerque, New Mexico

†Department of Pathology, The University of New Mexico Health Sciences Center, Albuquerque, New Mexico

## Abstract

Benign masses are not uncommon near the Achilles tendon of the ankle. However, the occurrence of angiomyomas or glomus tumors in the region has rarely been reported. We describe two patients, a 44-year-old woman and 44-year-old man, who presented with a tender mass posterior to the Achilles tendon. Excision led to successful removal of the lesion in both cases. Results of histological examinations revealed an angiomyoma and glomus tumor in the woman and man, respectively. Although rare, the presence of these tumors should be considered in the differential diagnosis of masses near the Achilles tendon.

## Introduction

A palpable prominence near the Achilles tendon often results from tendon thickening owing to tendinopathy, ossific deposits within the tendon, or the Haglund deformity.<sup>1</sup> Other common masses in the area include rheumatoid nodules<sup>2</sup> and tophaceous gout deposits.<sup>3</sup> However, studies have rarely reported angiomyomas or glomus tumors adjacent to the Achilles tendon.<sup>4-7</sup>

Angiomyomas, also known as vascular leiomyoma or angioleiomyoma, are benign, slow-growing, and solitary soft-tissue tumors usually less than 2 cm in diameter.<sup>4,5,8,9</sup> They originate from vascular smooth muscle and have three histological subtypes: solid (most common), cavernous, and venous.<sup>8</sup> The tumor commonly occurs in women but generally in adults aged 40 to 60 years.<sup>5,9</sup> About 75% of angiomyomas are found in the lower extremity,<sup>4-6,8-10</sup> with resultant pain reported by nearly half of patients.<sup>8,9</sup> The tumors rarely recur after excision.<sup>8</sup>

Similarly, glomus tumor are rare, benign, and hamartomatous lesions, that derive from neuromyoarterial glomus cells that regulate peripheral blood flow and temperature.<sup>11-13</sup> Studies have reported common occurrences in the hand,<sup>11</sup> primarily within the subungual

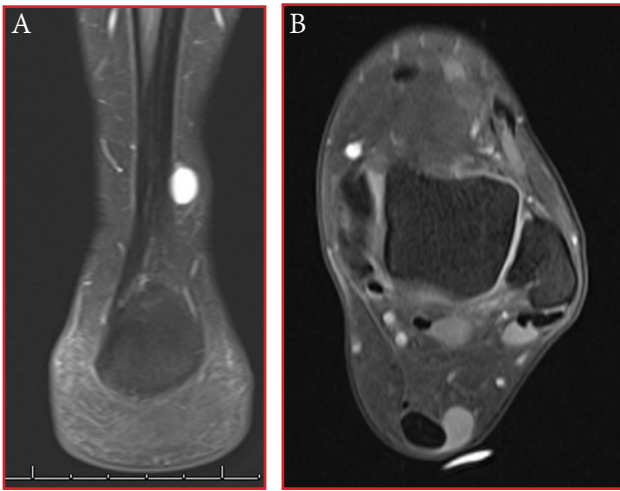
region of distal phalanges.<sup>12,14</sup> Often associated with prominent peripheral capillary vasculature, the lesions account for 1.6% of all soft-tissue tumors.<sup>13</sup> The tumors are typically small ( $\leq 1$  cm in diameter), solitary, firm, painful, and intolerant to cold.<sup>11-13,15</sup> Histologically, glomus tumors appear as an arteriovenous anastomotic complex comprised of uniform, circumscribed epithelioid, glomus, and smooth-muscle cells, which lack atypia or mitotic activity.<sup>16</sup> Because clinical manifestations of extradigital glomus tumors vary in paroxysmal pain, cold sensitivity, and point tenderness, the diagnosis is often delayed.<sup>17</sup>

We describe two patients who presented with a tender mass posterior to the Achilles tendon at the ankle joint. An angiomyoma was present in the first, whereas the second involved a glomus tumor. The patients were informed that the data concerning the cases would be submitted for publication, and they provided verbal consent.

## Case Reports

### Case 1: Angiomyoma

A 44-year-old woman presented with a painful mass posterior to the midsubstance of the right Achilles tendon. No history of injury was reported. In the 5 months since the patient first noticed the mass, it had slowly enlarged; otherwise, she was healthy. The mass was about 1 cm in diameter, ovoid shaped, and tender to palpation. On physical examination, her ankle had full range of motion. Magnetic resonance imaging (MRI) revealed a solid enhancing mass adjacent to the Achilles tendon (Figures 1A and 1B). Excision of the mass showed no direct involvement with the Achilles tendon. The mass was mostly grayish in color with a firm, rubbery texture. Findings of histological examination were consistent with the presence of an angiomyoma (Figure 2). The area around the excision healed, and the patient had complete resolution of symptoms. No recurrence of the angiomyoma was noted.



Figures 1A and 1B. Magnetic resonance imaging in case 1, showing the angiomyoma lesion adjacent to the Achilles tendon.

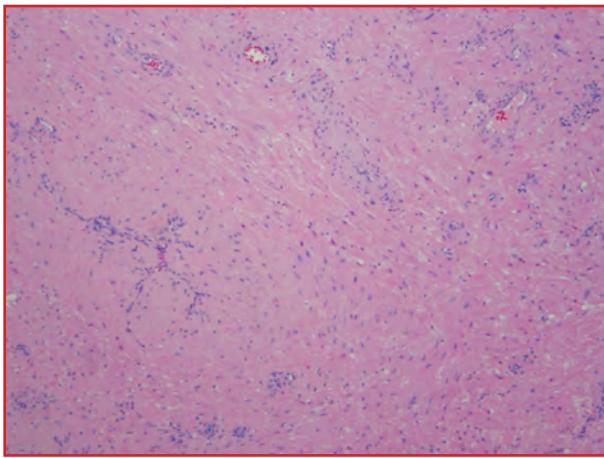


Figure 2. Results of the histological examination in case 1, showing proliferation of benign smooth muscle cells around blood vessels.

### Case 2: Glomus Tumor

A 44-year-old man presented with a mass posterior to the midsubstance of his left Achilles tendon. The lesion had existed for about 6 months, and the patient had no history of an injury. The area around the mass was painful during ambulation and when rubbed against by his shoe. High blood pressure was noted in the medical history of the patient; otherwise, he was healthy. The mass was tender and about 1 cm in diameter. An MRI showed the mass to have decreased signal on T1- and T2-weighted imaging (Figure 3). No involvement of the Achilles tendon was observed. After surgical excision, the mass appeared encapsulated and bluish in color. Results of histological examination revealed signs consistent with a glomus tumor (Figure 4). Postoperatively, the patient had complete relief of pain. No recurrence of the tumor was found.

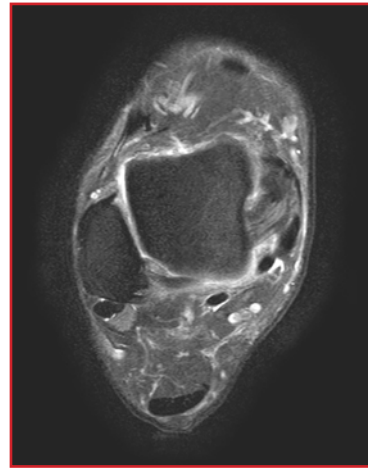


Figure 3. Magnetic resonance imaging in case 2, showing a subcutaneous mass posterior to the Achilles tendon.

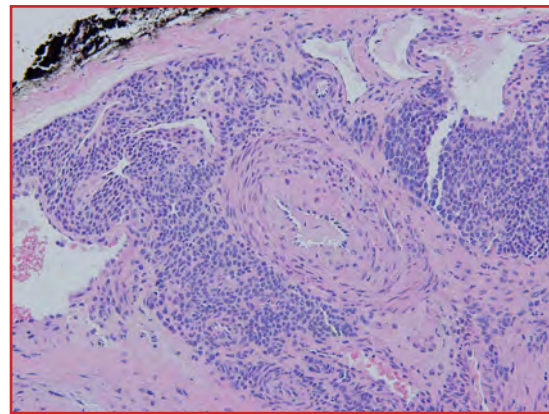


Figure 4. Results of the histological examination in case 4, showing a glomus tumor with vessels lined by uniform blue cells.

### Discussion

Although benign masses may be found near the Achilles tendon, the presence of actual tumors adjacent to the tendon are rare. We describe two patients who presented with a tender mass found posterior to the Achilles tendon at the ankle joint. Findings of histological examinations revealed the presence of an angiomyoma in case 1 and glomus tumor in case 2. For both patients, excision of the mass led to successful resolution of pain.

Angiomyomas adjacent to the Achilles tendon have rarely been reported.<sup>4-6</sup> Smith et al<sup>4</sup> reported a 58-year-old woman with a 5-year mass at the Achilles tendon, which had slowly increased in size and led to difficulty in wearing shoes. Barnes et al<sup>6</sup> reported a 37-year-old male police officer with a 2-year, intermittently painful mass next to his Achilles tendon. This was excised, and the patient noted a full recovery. Furthermore, Sonohata et al<sup>5</sup> described a slowly enlarging 2-cm mass during a 2-year period, which was found on the heel of a 47-year-old male office worker.

Although findings can vary in preoperative diagnosis, results of the current case 1 support typical clinical signs of an angiomyoma near the Achilles tendon, including a size of less than 2 cm in diameter<sup>4,5,8,9</sup> and prevalence in middle-aged adults, particularly women.<sup>6</sup>

To date, only one case by Nakamura et al<sup>7</sup> in 2000 has reported extradigital glomus tumors near the Achilles tendon. In the study, a 48-year-old woman presented with a 14-year history of a painful para-Achilles nodule. In contrast, our patient in case 2 had a 6-month history of the lesion. As with the current study, simple surgical excision led to complete resolution of pain. Other reports have described extradigital paratendinous or intratendinous glomus tumors, including those near the rotator cuff musculotendinous junction,<sup>18</sup> triceps tendon,<sup>19</sup> quadriceps tendon,<sup>15</sup> and patellar tendon.<sup>15,20</sup> In a 20-year retrospective review of 56 extradigital glomus tumors, twenty-three patients (41%) had a lower-extremity lesion, with a total of 7 cases occurring in the leg, ankle, and foot regions.<sup>21</sup> Mohler et al<sup>22</sup> described a 55-year-old woman with a 12-year history of a solitary, painful subcutaneous nodule of the plantar arch. The lesion was treated with excisional biopsy, and findings of pathological tests confirmed a glomus tumor. Additionally, Chiang and Chen<sup>23</sup> reported recurrent subfascial glomus tumors in the right gastrocnemius muscle of a 51-year-old man, with severe local pain from minimal skin contact. Treatment with repeated excisions led to successful removal of six total masses.

Because angiomyomas and glomus tumors can vary in size, location, and noted pain between patients, studies have typically combined use of clinical findings with imaging tests such as MRI to help with diagnosis.<sup>4,12,13,15</sup> Notably, the MRI in case 2 did not help isolate the lesion to the Achilles tendon. Subsequently, the results of the current cases may reinforce consideration of differential diagnosis in successfully identifying tumors near the Achilles tendon at the ankle joint.

## Funding

The authors received no financial support for the research, authorship, and publication of this article.

## Conflict of Interest

The authors report no conflicts of interest.

## References

1. Weinfeld SB. Achilles tendon disorders. *Med Clin North Am* 2014;98(2):331-8. doi: 10.1016/j.mcna.2013.11.005.
2. Turesson C, Matteson EL. Clinical features of rheumatoid arthritis: extra-articular manifestations. In: Hochberg MC, Silman AJ, Smolen JS, Weinblatt ME, Weisman MH, eds. *Rheumatoid Arthritis*. Philadelphia, PA: Mosby Elsevier; 2009:62-67.
3. Ventura-Ríos L, Sánchez-Bringas G, Pineda C, et al. Tendon involvement in patients with gout: an ultrasound study of prevalence. *Clin Rheumatol* 2016;35(8):2039-44. doi:10.1007/s10067-016-3309-7.
4. Smith J, Wisniewski SJ, Lee RA. Sonographic and clinical features of angioleiomyoma presenting as a painful Achilles tendon mass. *J Ultrasound Med* 2006;25(10):1365-8.
5. Sonohata M, Okamoto T, Shigematsu M, Mawatari M, Hotokebuchi T. Angioleiomyoma overlying the Achilles tendon. *J Orthop Sci* 2007;12(5):502-4.
6. Barnes SJ, Gey van Pettius D, Maffulli N. Angioleiomyoma of the Achilles tendon. *Bull Hosp Jt Dis* 2003;61(3-4):137-9.
7. Nakamura Y, Nomura T, Ookubo M, Adati T, Harada D. Extradigital glomus tumor causing para-Achilles tendon pain: a case report. *Acta Orthop Belg* 2000;66(5):503-6.
8. Hachisuga T, Hashimoto H, Enjoji M. Angioleiomyoma: a clinicopathologic reappraisal of 562 cases. *Cancer* 1984;54(1):126-30.
9. Zhang JZ, Zhou J, Zhang ZC. Subcutaneous angioleiomyoma: clinical and sonographic features with histopathologic correlation. *J Ultrasound Med* 2016;35(8):1669-73. doi:10.7863/ultra.15.06056.
10. Yates BJ. Angioleiomyoma: clinical presentation and surgical management. *Foot Ankle Int* 2001;22(8):670-4.
11. Carroll RE, Berman AT. Glomus tumors of the hand: review of the literature and report on twenty-eight cases. *J Bone Joint Surg Am* 1972;54(4):691-703.
12. Trehan SK, Athanasian EA, DiCarlo EF, Mintz DN, Daluiski A. Characteristics of glomus tumors in the hand not diagnosed on magnetic resonance imaging. *J Hand Surg Am* 2015;40(3):542-5. doi:10.1016/j.jhssa.2014.12.002.
13. Nazzi V, Bagatti D, Mazibrada J, Franzini A. Glomus tumor closely related to a branch of the left sural nerve: a case of a rare lesion occurring at unusual location. *Acta Neurochir (Wien)* 2015;157(9):1619-22. doi:10.1007/s00701-015-2499-0.
14. Maxwell GP, Curtis RM, Wilgis EF. Multiple digital glomus tumors. *J Hand Surg Am* 1979;4(4):363-7.
15. El Hyaoui H, Messoudi A, Rafai M, Garch A. Unusual localization of glomus tumor of the knee. *Joint Bone Spine* 2016;83(2):213-5. doi:10.1016/j.jbspin.2015.07.001.
16. Kouskoukis CE. Subungual glomus tumor: a clinico-

- pathological study. *J Dermatol Surg Oncol* 1983;9(4):294-6.
17. Lee SH, Roh MR, Chung KY. Subungual glomus tumors: surgical approach and outcome based on tumor location. *Dermatol Surg* 2013;39(7):1017-22. doi:10.1111/dsu.12181.
18. Yoshikawa G, Murakami M, Ishizawa M, Matsumoto K, Hukuda S. Glomus tumor of the musculotendinous junction of the rotator cuff: a case report. *Clin Orthop Relat Res* 1996;(326):250-3.
19. Tomak Y, Dabak N, Ozcan H. Extradigital glomus tumor of the triceps tendon as a cause of elbow pain: a case report. *J Shoulder Elbow Surg* 2003;12(4):401-2.
20. Mabit C, Pécout C, Arnaud JP. Glomus tumor in the patellar ligament: a case report. *J Bone Joint Surg Am* 1995;77(1):140-1.
21. Schiefer TK, Parker WL, Anakwenze OA, Amadio PC, Inwards CY, Spinner RJ. Extradigital glomus tumors: a 20-year experience. *Mayo Clin Proc* 2006;81(10):1337-44.
22. Mohler DG, Lim CK, Martin B. Glomus tumor of the plantar arch: a case report with magnetic resonance imaging findings. *Foot Ankle Int* 1997;18(10):672-4.
23. Chiang ER, Chen TH. Multiple glomus tumors in gastrocnemius muscle: a case report. *Arch Orthop Trauma Surg* 2008;128(1):29-31.

# Preparing Resident Physicians for Healthcare Reform

Michael M. Decker, MD

Department of Orthopaedics & Rehabilitation, The University of New Mexico Health Sciences Center, Albuquerque, New Mexico

During my residency training, there have been considerable changes in the way that healthcare is financed and delivered in the United States. Some changes will notably affect my future career as a surgeon specializing in adult reconstruction. The most influential change thus far is the Comprehensive Care for Joint Replacement (CJR) model for joint replacement surgery, introduced by the Centers for Medicare & Medicaid Services (CMS).

The CJR model, which officially began in 2016 in select regions, redefined how CMS reimburses hospitals and providers for total joint replacement. The model shifts financial risk from the payer (CMS) to the hospital and providers, while offering incentives to improve the quality of care for patients. This value-based reimbursement model differs notably from the fee-for-individual-services model (currently used by many other payers), changing the payment method instead to a bundled payment for a defined episode of care. The change has required hospitals to revise their care-delivery models for covered patients who undergo total joint replacement. As a result, extensive research has been conducted into cost-saving strategies, patient-risk stratification, and quality-improvement measures to ensure that hospitals and patients succeed in this model. Providers must be well versed in the model structure to maintain a thriving, patient-centered practice.

Unfortunately, during residency, we spend little time becoming educated in the nuances of healthcare systems or practice management. Most of our educational time is spent gaining medical and technical knowledge needed to complete an orthopaedic-surgery residency. However, starting early in training, resident physicians across all specialties begin assuming the responsibility of providing direct patient care. The decisions have a notable effect on both the patients and the associated hospital system. Resident knowledge of healthcare systems and reforms is essential for residents to effectively deliver care in the hospitals and for teaching institutions to continue to be successful in these new models.

We can use the CJR model to better appreciate this knowledge. Hospital systems are developing and implementing numerous strategies to improve the

value of care concerning joint replacement procedures by decreasing costs and improving patient outcomes. Surgeons may collaborate with anesthesiologists and primary-care providers to develop more coordinated and extensive preoperative strategies to minimize perioperative complications. Acute inpatient care can be streamlined to standardize laboratory orders, pain-control protocols, postoperative rehabilitation, and patient co-management with other medical services.

Discharge planning and post-discharge follow-up care plans will be especially important to avoid unnecessary emergency-room visits; additionally, this planning ensures that patients have access to healthcare professionals with knowledge about any recent operative procedures and post-acute care needs. Residents must understand these changes to provide cost-effective, high-quality patient care in operating, inpatient, and outpatient settings. Although this example specifically affects total joint replacement practices, the trend toward value-based delivery reform will continue in other areas of orthopaedics and other medical specialties. It is in the best interests of hospitals and patients that residents develop a sound understanding of the healthcare system they work in.

We eventually complete residency and fellowship training and begin practice. It is essential that we understand how the healthcare system—which we work in—influences the care that we are trained to deliver. Despite the best intentions of healthcare-reform measures, unforeseen negative effects may occur. For example, a theoretical concern of the CJR model is that certain patients may be considered to be too “high risk” for a hospital to consider providing an otherwise beneficial total joint replacement. These “high-risk patients” could be channeled toward tertiary care hospitals to undergo joint replacement; however, this may create a largely high-risk patient pool for these hospitals and thereby increase costs and decrease patient access to joint replacement surgery. Because of downward pressure on target prices created by yearly readjustments, concern exists that fewer and fewer patients may have access to surgical procedures that could otherwise improve their quality of life. If we can begin

educating residents about how these systems influence practice, our physicians can be better prepared to develop effective strategies to overcome barriers in providing care and advocate for patient interest.

To be successful and ensure that patient care remains the cornerstone of our future practices, we as residents must develop a sound understanding of the current state of our healthcare system and reform measures. This may be difficult to incorporate into an otherwise busy resident schedule, yet it would be imprudent to overlook its importance in the short and long term. We can better treat our patients in training, ensure sustainability of our training hospitals, finish our training with the appropriate tools to build a viable practice, and advocate for our patients' access to needed care while healthcare reforms are created—and thereby we can contribute to a more efficient healthcare system.

# Hosting the Perry Outreach Program and Medical Student Outreach Program in Albuquerque: Promoting Women Leaders in Engineering and Orthopaedic Surgery

Lauren Long, BS\*; Sahar Freedman, BA\*; Jodie Gomez, BS\*\*; Deana M. Mercer, MD\*; Christina Salas, PhD\*\*\*

\*Department of Orthopaedics & Rehabilitation, The University of New Mexico Health Sciences Center, Albuquerque, New Mexico

†Department of Mechanical Engineering, The University of New Mexico, Albuquerque, New Mexico

‡Center for Biomedical Engineering, The University of New Mexico, Albuquerque, New Mexico

Jenni Buckley, PhD, and Lisa Lattanza, MD, founded the Perry Initiative in 2009. Drs. Buckley and Lattanza named the non-profit organization in honor of Dr. Jacquelin Perry, one of the first female orthopaedists in the 1950s.<sup>1</sup> The Perry Initiative runs more than 30 annual outreach programs and aims to inspire young women to pursue orthopaedic-surgery and engineering careers. Why? Because the percentage of female leadership in each field is low—women “make up only 6.1% of fully-accredited practicing orthopaedic surgeons” and “only 12.4% of the faculty at engineering schools are women.”<sup>1</sup>

At The University of New Mexico (UNM) Department of Orthopaedics & Rehabilitation, we are honored to host two Perry Initiative programs right here in Albuquerque: the Perry Outreach Program (POP) and the Medical Student Outreach Program (MSOP). We have hosted five POPs since 2013 and hosted our first MSOP in 2016. Owing to the success of our previous POP events, the Perry Initiative selected our site to host the MSOP, a recently created pilot program.

## Differences Between the Programs

At both events, participants must first submit to a selective application process for acceptance. Both events include open discussions, hands-on workshops, and direct networking with orthopaedic surgeons and engineers—guided by women leaders in both fields. Additionally, they are free for participants. Notably, the POP and MSOP have a few differences.

The POP is a long-standing annual event held in various locations across the United States and recruits mainly high-school students. The program exposes young women

to medicine and engineering fields, and 40 local students are accepted to this all-day event. The program includes six hands-on workshops, an engineering competition (created by Christina Salas, PhD, and her team at the UNM Orthopaedics Biomechanics & Biomaterials Laboratory), and two lectures. Two representatives from the Perry Initiative fly out to New Mexico to lead the program.

The MSOP is a new program (introduced in 2016) and recruits only female medical students, allowing direct exposure to orthopaedic surgery. A total of 30 UNM medical students participate in this half-day event. The program—consisting of two hands-on workshops and two lectures—is self-run by UNM Orthopaedics (with help and supplies provided from afar by the Perry Initiative).

Ultimately, the goal of each program is to inspire women to pursue careers in the two male dominated fields of engineering and orthopaedic surgery. The methods and emphasis, however, to achieve these are slightly different. The POP invites young women in high schools throughout New Mexico to explore careers in medicine and engineering. The MSOP helps foster a sense of community between new medical students and UNM Orthopaedics and provides a unique opportunity to network with UNM physicians, residents, fellows, and colleagues. At the end of both programs, we hope our participants leave with new ideas and insights into a lifelong career—a career that women and men can pursue with equal success.





## Hosting the Fifth Annual Perry Outreach Program on March 4, 2017

At the fifth annual POP, a total of 28 volunteers (ie, physicians, residents, fellows, orthopaedic technicians, physician assistants, medical students, engineering students, and department staff members) and 41 high-school students embarked on a journey with drills, bones, and cadaveric specimens. Our guest speaker from Axogen Inc—Crystal Simon, PhD—started the day with a talk about biomedical engineering and the dynamic relationship between physicians and engineers (Figure 1A). Afterward, we began the first set of hands-on workshops and helped the high-school students apply arm casts, suture pig feet, and drill intramedullary (IM) nails into fractured bones (Figure 1B).



**Figure 1.** At the Perry Outreach Program, (A) Crystal Simon, PhD, discusses how to succeed as a biomedical engineer and (B) Orlando Merced-O'Neill (blue scrubs) shows two participants the proper way to apply suturing techniques.

After the morning workshops, Dr. Salas directed the bone-breaking competition—an innovative engineering-related addition to the program, featured for the first time last year. Participants watched wide-eyed as engineering volunteers placed the bones (which the participants had repaired earlier during the IM nail workshop) inside a testing device that applied force until breakage occurred—a device that Dr. Salas and her team designed and created (Figure 2). The winning group repaired a bone that withstood 250 lb!

With new understanding of how the type of surgical repair affects the strength of the repaired bone, students transitioned into the final set of hands-on workshops: repairing fractures of the distal radius, performing external fixation, and observing a live dissection of a cadaveric hand-and-forearm.

Before the program concluded, we rallied all volunteers for a final question-and-answer session and invited the participants (and their parents) to inquire about any topic in either field. Questions ranged from how to successfully apply to medical school to how to persevere in a male-dominated profession. The young, aspiring

women departed with personalized diplomas, goodie bags, mentors, internship opportunities, and a newfound passion for medicine and engineering (Figure 3).



**Figure 2.** At the Perry Outreach Program, Christina Salas, PhD leads the engineering competition and discusses the device constructed in her UNM Orthopaedic Biomechanics & Biomaterials Laboratory.



**Figure 3.** At the Perry Outreach Program, a group photograph shows all fantastic participants and volunteers.

## Hosting the First Annual Medical Student Outreach Program on September 17, 2016

Janel Pietryga, a senior medical student at UNM, began our first annual MSOP with an informative talk on physician-shadowing opportunities and available student groups at UNM North Campus. Christopher Hanosh, MD—an assistant professor at UNM Orthopaedics—complemented Janel's lecture with a lively discussion on work-life balance as a practicing surgeon (Figure 4). The entire group consisted of 27 medical students and 10 volunteers (ie, physicians, fellows, residents, and staff members).

After the morning lectures, the medical students participated in two hands-on workshops: applying techniques using IM nailing and performing external fixation, both for treating fractured femurs (Figure 5).

Erica Gauger, MD, and Brandee Black, MD captivated all listeners with their stories on choosing orthopaedics as a lifelong career, persevering through residency and fellowship experiences, and overcoming the many obstacles along the way.

Following the lectures, the volunteers formed a panel discussion and invited all participant inquiries. The medical students asked about daily life, how to raise kids while working as a surgeon, and the timeframe required to complete a fellowship in orthopaedics. Before the program ended, each of the participants received a shiny certificate of completion and a book published by the Ruth Jackson Orthopaedic Society (Figure 6).



**Figure 4.** At the Medical Student Outreach Program, Christopher Hanosh, MD, asks the students about their current interests regarding surgical professions.



**Figure 5.** At the Medical Student Outreach Program, Brandee Black, MD, helps medical students in the intramedullary-nail activity.



**Figure 6.** At the Medical Student Outreach Program, participants and volunteers pose for a group photograph before heading home.

## Moving Forward

Thanks to these two amazing programs created by the Perry Initiative, many young women of New Mexico can reap the benefits of networking and participating in medical- and engineering-related workshops. UNM Orthopaedics is grateful for the opportunity to host such fantastic outreach events in our effort to actively educate the women of our state on the essential collaboration between medicine, engineering, and pursuing your ambitions in both fields.

## Funding

The Perry Outreach Program was generously supported by material donations from Summit Medical, AxoGen Inc, Acumed, Össur, and Zimmer BioMet. Special thanks to UNM Department of Orthopaedics & Rehabilitation for financial support.

## Acknowledgments

We thank the following volunteers from the Perry Initiative, Summit Medical, Acumed, AxoGen Inc, UNM Department of Orthopaedics & Rehabilitation, School of Medicine, School of Engineering, Marketing & Communications, and the many individuals whose time and efforts dedicated to the two programs made the events not only possible but enjoyable. Special thanks to: Manuela Restrepo, Grace Ruiz Cooper, Nicole Ray, Laurie Meszaros Dearolf, Quincy Gonzales, Crystal Simon, Orlando Merced-O'Neill, Joy VanMeter, Melanie DeLorenzo, Ryan Wood, Selina Silva, Brandee Black, Christopher Hanosh, Erica Gauger, Amber Price, Katherine Gavin, Erika Garbrecht, Aditi Majumdar, Angelina Rodriguez, Amber West, Kris Battaglini, Jessica Yazzie, Linda Joy Elliott, Pamela Caraveo, Ericka Charley, Janel Pietryga, Jessica Avila, Yvonne Talamantes, Jodie Gomez, Lauren Long, Steven Nery, Christopher Buksa, Farid Manuchehrfar, Gene Passariello, James Perea, Amy Rosenbaum, George Griego, Kim Delker, Amanda Bassett, Janea Dickson, Marcos Romero, Julie Bowers, and Ethan Rule.

## Reference

1. The Perry Initiative. Mission & History. <http://perryinitiative.org/about/mission-statement/>. Accessed March 10, 2017.

# The Albuquerque Community Sports Medicine Experience: Four Decades and Counting

Christopher A. McGrew, MD<sup>\*†</sup>; Thomas A. DeCoster, MD<sup>\*†</sup>; Shane P. Cass, DO<sup>†</sup>;  
Richard Gerrells, BS, ATC<sup>‡</sup>; Edward R. Sweetser, MD<sup>§</sup>

<sup>\*</sup>Department of Orthopaedics & Rehabilitation, The University of New Mexico Health Sciences Center, Albuquerque, New Mexico

<sup>†</sup>Department of Family & Community Medicine, The University of New Mexico Health Sciences Center, Albuquerque, New Mexico

<sup>‡</sup>Albuquerque Public Schools, Albuquerque, New Mexico

<sup>§</sup>Orthopaedic Surgery, Mountain View Medical Group, Las Cruces, New Mexico

The Albuquerque and Bernalillo County Medical Association (ABCMA) formed the Sports Medicine Committee (ABCMA<sup>SMC</sup>) in 1973. The original charge to the committee was to “1) heighten the consciousness of the community regarding the importance of physical fitness in general health programs and 2) improve physician understanding of physical fitness and encourage physicians to increase their activities in this field of study.”<sup>1</sup> Throughout the United States, numerous community endeavors have existed to improve scholastic sports medicine<sup>2-6</sup>—but the Albuquerque program was and continues to be notable for its multidisciplinary aspect, growth, and overall scope.<sup>1</sup>

Of the original 12 ABCMA<sup>SMC</sup> members, several were specifically interested in sports injuries in children and adolescents and had already independently covered high-school football (American football) games. At that time, Albuquerque possessed no formal sports medicine programs or certified athletic trainers in high schools. Coaches handled minor injuries, and more serious injuries fell to the athletes and their parents to treat, with no formal rehabilitation. These deficiencies were recognized by committee members and became a crystallizing stimulus for the group.

In 1982, Sweetser et al<sup>1</sup> chronicled the origin and early activities of the ABCMA<sup>SMC</sup>, highlighting the multidisciplinary composition and development of a comprehensive sports medicine program for community high schools. Notable achievements of the initial ABCMA<sup>SMC</sup> included a formal assignment of volunteer community team physicians for each of the ten public high schools, an injury surveillance system, and educational initiatives. Furthermore, the group advocated the establishment of certified athletic trainers (ATCs) in every Albuquerque public high school, raising the standard of

sports medicine care for scholastic athletes across the community. Fortunately, this coincided with the rapidly growing Athletic Trainer Education Program (ATEP) at The University of New Mexico (UNM), which provided a large pool of ATCs who could be hired by the public high schools. The initial efforts of ABCMA<sup>SMC</sup> were critical in laying the groundwork for developing close personal and work relationships among the volunteer team physicians, trainers, administrators, and athletes.

After 1982, further refinements in the community and beyond began to shape the structure of the program: ABCMA was renamed to GAMA, the Greater Albuquerque Medical Association; the number of high schools in the area grew from 10 to 21; private groups coalesced into hospital affiliations; and sub-specialization in sports medicine became commonplace. Most notably, UNM Health Sciences Center (UNMHSC) orthopaedics faculty grew from five members to 27; in 1990, this number included a non-surgical primary care sports medicine physician who served as a liaison to the GAMA Sports Medicine Committee (GAMA<sup>SMC</sup>). At this point, UNMHSC participation in the volunteer physician program rapidly increased, with involvement from both faculty and resident physicians.

By 2015 (43 years after ABCMA<sup>SMC</sup> formed!), the persistent and enduring grass-roots program of GAMA<sup>SMC</sup> continued to thrive. Volunteer physicians for teams and education programs provided coverage to high schools in three counties in the central part of the state (Sandoval, Bernalillo, and Valencia counties), serving 18 public and three private high schools. We estimate that, by 2015, GAMA<sup>SMC</sup> had provided medical coverage to more than 6000 high school football games and 10,000 injured athletes since its inception. More than 100,000 injured athletes in a variety of sports had been treated by school

athletic trainers, and more than 350,000 student athletes in high school had received sports-medicine assistance during training and games.

GAMASMC service continued to grow in 2016, and the ever-expanding involvement of UNMHSC helped provide physician coverage to the increasing number of high schools in the region. By 2016, more than 30 volunteer team physicians covered more than 220 football games and acted as consultants to athletic trainers of schools. Whereas in 1982 GAMASMC exclusively comprised private-practice physicians, half of the high-school coverage in 2016 came from faculty and residency programs of UNMHSC (ie, Department of Orthopedics & Rehabilitation, Family & Community Medicine, Pediatrics, and Emergency Medicine). Additionally, in 2016, two new programs were created: 1) a formal orientation program to prepare residents for year-long roles as sideline team physicians and consultants; and 2) a program for medical students, who were assigned to volunteer team physicians, participated in sideline coverage of games, maintained a season-injury log, and completed bi-weekly quizzes (Figure 1).

The sports-medicine program has been actively embraced by Albuquerque Public Schools, recognizing the importance of high-quality health care to high-school athletes. The on-campus trainer program has expanded from non-existent to consistent coverage for each school. The program has also incorporated the educational aspect by facilitating student managers and assistants to the athletic trainers.



**Figure 1.** James Toldi, DO, and Seth Hunter, a second-year medical student, volunteer as team physicians for Albuquerque Academy during a football game.

Throughout the years of GAMASMC, the reporting of injury surveillance—which transitioned from cumbersome, paper-based systems to electronic, online records—has helped guide injury protocols and decisions in sports medicine. In 1988, Grace et al<sup>7</sup> reported that the use of prophylactic knee bracing can reduce the severity of collateral ligament injuries in football athletes who play the position of interior linemen. The article is frequently referenced during the still-current debate on prophylactic knee braces for football. Furthermore, DeCoster et al<sup>8</sup> published a review on sports-specific fractures (including football athletes in high school) and Swartzon et al<sup>9</sup> presented the total number of concussions, referral percentages, and average time for return to play of these athletes. This concussion data played an important role in 2016 State of New Mexico legislation, which extended the minimum time for return to play after a concussion.

The educational component of GAMASMC continues to this day. Every August, an orientation meeting is held for all volunteer physicians and athletic trainers. Since 2005, GAMASMC and UNMHSC Sports Medicine have co-hosted a monthly sports-medicine conference in the community, which offers continuing education credits and attracts local coaches, physical therapists, medical students, and various healthcare professionals. The presentations (also available online after the meeting) include common, important, and relevant musculoskeletal and medical issues involving athletic care, as well as updates from the staff members of Albuquerque Public Schools. Time is allocated for networking among the providers, thereby promoting the development of team building, problem solving, and innovation.

Teamwork and sustainability are essential for the success of any community service organization or program. The founders of GAMASMC believed that an organized, formal relationship between physicians and athletic trainers are key to the continued success and longevity. Additionally, the founders philosophically opined that “the rewards to the physician participants, though not monetary, far transcend the time and effort expended and benefit the entire community in a variety of ways”<sup>1</sup>. Throughout the evolution of the program, participants have developed modifications and initiatives with these basic tenets in mind. As each new wave of providers enters the program, the original principles remain valued and followed in producing an enduring, positive influence on athletic-medicine care in the community.

The volunteer team physician program of GAMASMC provides an ongoing service to the Albuquerque community and especially to healthy competition amongst high-school athletes. For more than 40 years, it has served as an ongoing and evolving example of volunteer

coordinated care—involving various providers from different professions and practice settings.

## References

1. Sweetser ER, Nelson MA, Miranda GE. A county sports medicine committee: the Albuquerque experience. *Am J Sports Med* 1982;10(3):184-7.
2. Porter M, Noble HB, Bachman DC. Sports medicine care in Chicago-area high schools. *Phys Sportsmed* 1980;8(2):95-9.
3. Redfearn RW. The physician's role in school sports programs. *Phys Sportsmed* 1980;8(9):67-71.
4. Mathews E, Esterson P. Sports medicine in northern Virginia high schools. *Athl Train* 1983;18:181-2.
5. Culpepper MI. The availability and delivery of health care to high school athletes in Alabama. *Phys Sportsmed* 1986;14(1):130-7. doi: 10.1080/00913847.1986.11708971.
6. Tucker JB, O'Bryan JJ, Brodowski BK, Fromm BS. Medical coverage of high school football in New York state. *Phys Sportsmed* 1988;16(9):120-30. doi: 10.1080/00913847.1988.11709601.
7. Grace TG, Skipper BJ, Newberry JC, Nelson MA, Sweetser ER, Rothman ML. Prophylactic knee braces and injury to the lower extremity. *J Bone Joint Surg Am* 1988;70(3):422-7.
8. DeCoster TA, Stevens MA, Albright JP. Sports fractures. *Iowa Orthop J* 1994;14:81-4.
9. Swartzon M, Southard J, Navarro R, McGrew C. State legislative impact on high school concussion return to play. Poster presented at: 2013 American Medical Society for Sports Medicine Annual Meeting; April 17-21, 2013; San Diego, CA.

# Remembrances: Orthopaedics Throughout the Years (1980s–Present)

Richard A. Miller, MD

Department of Orthopaedics & Rehabilitation, The University of New Mexico Health Sciences Center, Albuquerque, New Mexico

## Residents Enjoying Libations at El Patio Restaurant (1990)



From left to right back row: Sanagaram Shantharam (Class of 1992), unknown student, Mark Crawford (1994), Tom Ferro (1990), and Harry Cole (1992). Foreground: Laurel McGinty (1991) who passed away on January 9, 2012.


---

## The Annual University of New Mexico Orthopaedic Alumni Conference (1996 and 1997)

Traveling fellows from the Association of Southeast Asian Nations, with a young Richard Miller (Class of 1990), attended the alumni conference in 1996.



Papers advertising the alumni conferences in 1996 and 1997.





Facing from left to right: Tom DeCoster, Frances Ting, Victoria Matt (Class of 2002), Adam Barmada (2001), Andy Veitch's head (2003), Rich Aiken, and Eric Thomas (2004) now deceased.



Left: Mike Willis, a friend, and Ali Motamedi stir the pot in 1997. Photo courtesy of Ali.

## Crawfish Boil Turns 20 Years Old (1997 and 2001)

The crawfish boil was the brainchild of Louisiana native Mike Willis (Class of 2000). Attendees included Matt Patton (Class of 2002), Ali Motamedi (1998), Tim McAdams (2000) and Brian Robinson (1998). They do not remember the location. Over the past 20 years, the boil has been held at various resident houses, including that of Eric Benson (2007). Gehron Treme (2006), our current residency program director, and his wife Michelle now host the annual event.



Crawfish boil in 2006, hosted by Gehron Treme. Left to right: Krishna Tripuraneni, Jeff Yaste, Clayton Conrad, Bob Quinn, Gehron Treme, and Zach Adler.



Above: Brent Milner (2003) and Speight Grimes (2004).



Crawfish boil in 2004, hosted by Eric Benson. Crowd hovering over and eating crawfish at the table. Far end of the table: Rick Gehlert, Gehron Treme, and Gregg Pike.

## Sports and Orthopaedics

Many former and current residents played sports in college.



Tom DeCoster:  
The University of  
New Mexico Law  
School courts,  
1989.



Bob Sotta (Class of 1987) as player  
#29: played quarterback in college.  
Seen here on the softball field in  
1986. Bob went on to a sports  
fellowship.




Erika Garbrecht: soccer.



The University of New Mexico North  
Golf Course with Richard Miller,  
Adam Barmada (2001), John Franco  
(2003), Charlie and Andy Veitch  
(2003), and a visiting resident from  
Germany in 2001.

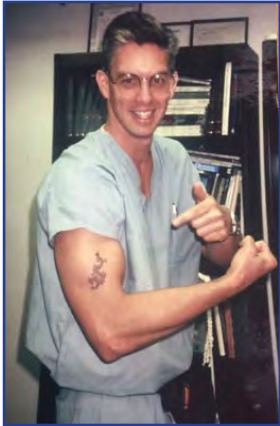

Aditi Majumdar:  
pole vault, The  
University of New  
Mexico.




Mischa Hopson seen on the  
sidelines of the Texans football  
game.





Jim Ferries (Class of 1995) sporting a temporary tattoo.

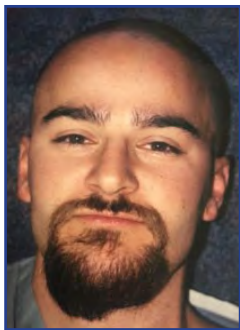


David Cortese (Class of 2005) doing what we have all done.



Jimmy Slauterbeck (Class of 1993), Dan Downey (1992), and Grant Dona (1993) on the tarmac.

Residency is hard work and long hours.  
Sometimes you need a little diversion.



Adam Barmada (Class of 2001), Chris Hanosh (2001), and Matt Patton (2002). Looking good with shaved heads.



Party with Rick Castillo (Class of 1988), Dudley Burwell (1987), Bennett Davis, Lock Ochsner (1986), and Richard Miller (1990) in 1985.

### Acknowledgments

My thanks to Eric Benson and Gehron Treme for helping provide pictures of the Crawfish Boil.

# Novel Strategies for Time Efficiency in an Orthopaedic Clinic: A Satire

Christopher L. Shultz, MD; Richard A. Miller, MD

Department of Orthopaedics & Rehabilitation, The University of New Mexico Health Sciences Center, Albuquerque, New Mexico

## Abstract

**Background:** Healthcare professionals aim to provide every patient with the time necessary to make a successful diagnosis and offer treatment options. As the demand for seeing more patients rises, so does the need for tools to make clinical visits more efficient. One of the most easily fixed issues is the time required to login to computers for collecting patient information, which can result in many hours lost in collective physician time. We propose use of a novel vibrating mousepad to save time by preventing computers from automatically logging off.

**Methods:** In half of a clinic-day, with 16 patient visits, we placed a vibrating mousepad on each designated computer. As a control, another computer was logged into before each patient visit.

**Results:** The computer designated to the vibrating mousepad successfully avoided re-login for 13 of 16 patient encounters (81.3%). Of the three unsuccessful events, two resulted from the mouse falling off the pad and one resulted from user error. Average login time was 11 seconds, including time spent typing and waiting for the screen to load to access imaging and electronic medical record programs. Annually, these results reflect potential time and financial savings per physician, respectively, of 7.3 to 17 hours and \$3672 based on median salary of orthopaedists.

**Conclusions:** The vibrating mouse pad is an efficacious cost and time saving tool in busy orthopaedic clinics, allowing providers to increase their quality and quantity of care to the community.

## Introduction

Seeing patients in clinic is an important aspect of orthopaedic care. Whether a new patient visit or postoperative follow-up, we continue to hold ourselves to a standard to provide each patient with the time necessary for diagnosis and treatment options. A Medscape survey<sup>1</sup> in 2011 of orthopaedic surgeons found that most spent between 9 and 12 minutes per patient.<sup>1</sup> In 2016, this

increased to 9 to 16 minutes per visit.<sup>2</sup> Although this a step in the right direction, there is still room to improve. By granting more efficiency to the clinic system, we allow ourselves to provide both quality and quantity of patient care to the community.

At our institution, several strategies have been successfully introduced to increase clinic efficiency, such as standardized radiograph order forms, pre-clinic radiographs, and well trained personnel. However, slow computers and long wait times for password logins have posed an insurmountable threat to clinic flow thus far.

Although the electronic medical record made communication, documentation, and ordering systemically easier, it is not without imperfections. One of the most easily fixed short-fallings is the inefficiency of computer login time. This time spent logging into a computer has resulted in significant collective loss of physician time. These hours could have otherwise been spent seeing patients and improving documentation. The aim of this article is to present a novel strategy for saving time and increasing productivity in an orthopaedic clinic by keeping the computer mouse active and preventing the physician's account from logging off.

## Methods

A Google search was performed for vibrating mouse pads. There were no commercially available vibrating mouse pads readily accessible on the internet. We then came across the Lulla-Vibe Vibrating Mattress Pad (Munchkin, Van Nuys, CA), with an average price of \$20 on Amazon.<sup>3</sup> The pad requires four AA batteries. To activate the pad function, a large "On" button is squeezed. The mouse can then vibrate on the pad, preventing a computer from logging off (Figure 1).

In a clinic half day, with 16 patient encounters, we placed the mouse on an active vibrating mouse pad between each clinic patient encounter. As a control, another computer was allowed to log-off between patient encounters, requiring a physician log in for each encounter. All computers tested were enclosed in a designated, private,

well-furnished physician work room. We then measured the frequency of successful encounters where a physician work computer did not require re-entry of password.

To assess the average time that orthopedic physicians at our institution spend logging in to a computer in a given day we measured the time spent logging in to a computer after each patient encounter in a clinic day. Start time was defined as when the provider began typing to log into the computer. End time was defined as when the provider was able to access the patients' EMR and imaging software.



Figure 1. The vibrating device, which is placed next to the mouse to prevent the computer from automatically logging off owing to inactivity.

## Results

Of the 16 patient visits, our control computer was automatically logged out after every patient encounter. The computer designated to the vibrating mouse pad successfully avoided re-entry and login for 13 of 16 patients (81.3%). Of the three unsuccessful events, two were the result of the mouse falling off the pad, and one was a result of user error (ie, forgetting to turn the pad on between patient encounters).

The average time to log back in to a clinic computer was 11 seconds. This was measured during the clinic day. This includes time spent typing and time spent waiting for the screen to load to access imaging and EMR programs. Multiplied by a total of 32 visits for a full clinic day, this resulted in 352 seconds (5.9 minutes) spent per day.

With an average login wait time of 11 seconds per patient, time spent logging in at this rate for a 100 patient clinic day would result in 18.3 minutes per day of login waiting time. To control for variations in clinic schedules and patients seen per day by a physician, the calculated time spent logging in for 100 patient visits would be 1100 seconds (18.3 minutes).

## Discussion

Finding ways to improve clinic efficiency is an ongoing struggle. Several attempts at improving efficiency have been successfully implemented in the past; however, few have addressed the time a physician spends for login to a computer. Our study has investigated a novel strategy for reducing time spent in clinic caused by logging into computers. Use of the vibrating mousepad resulted in an 81.3% success rate at preventing re-entry of password into computers at physician work areas.

In the current study, other avenues for keeping the physician work computer open were explored, such as rubber banding an electric toothbrush to the mouse. However, this was quickly abandoned once we realized the time spent securing the toothbrush to the rubber band overshadowed the time spent logging in. We also considered addressing the "lock out" time set by the University Information Technology services. However, we spent several minutes investigating this endeavor, for which many institutions pre-set lock out times on physician work computers for patient privacy.

Our results indicated a conservative average time of 18.3 minutes spent logging in per 100 patient visits, which would result in savings of 14.9 minutes per 100 visits. (Calculated by 18.3 minutes divided by 100 visits, multiplied by the noted success rate of 0.813.) Estimating that the average orthopaedic surgeon at our institution sees between 60 and 140 patients per week in clinic, the vibrating mouse pad has the potential to save between 7.3 to 17 hours in annual time savings per physician (at 49 weeks of work per year). With the reported median income of an orthopaedic surgeon at \$216 per hour,<sup>4</sup> the vibrating mousepad could save an orthopaedic-surgery clinic up to \$3672 per year per physician, which would more than offset the cost of four AA batteries. Keeping in mind that these upper estimates are for an orthopaedic surgeon seeing 140 patients per week, the potential benefits could be much higher for a busier orthopaedist.

The limitations of this study include a small sample size. Only one orthopaedic resident was measured to assess login time. In addition, the average 11 second log in time may vary substantially with differing quantities of patients seen in clinic, time spent per patient, and use of a computer in a patient room. More commercially accessible and cheaper vibrating mousepads may also be available that did not meet our search criteria. This study also did not take into account the longevity of four AA batteries, which may be cost prohibitive in some institutions. Finally, this study did not account for the noise pollution produced by vibration of the mousepad in a physician work area, which may be offensive to some providers. Results of further

long-term studies, with larger sample sizes of patients and providers may help illuminate the potential benefits in time saving when using this technique.

## References

1. Medscape. Orthopedist and Orthopedic Surgeon Compensation Report 2011. New York, NY: Web MD LLC; 2011. <http://www.medscape.com/features/slideshow/compensation/2011/orthopaedics>. Accessed January 10, 2017.
2. Peckham C. Medscape Orthopedist Compensation Report 2016. New York, NY: Web MC LLC; April 1, 2016. <http://www.medscape.com/features/slideshow/compensation/2016/orthopedics#page=1>. Accessed January 10, 2017.
3. Amazon. Munchkin Lulla-Vibe Vibrating Mattress Pad Baby Soother. Amazon.com website. [https://www.amazon.com/s/ref=nb\\_sb\\_noss?url=search-alias%3Daps&field-keywords=Munchkin+Lulla-Vibe+Vibrating+Mattress+Pad+Baby+Soother](https://www.amazon.com/s/ref=nb_sb_noss?url=search-alias%3Daps&field-keywords=Munchkin+Lulla-Vibe+Vibrating+Mattress+Pad+Baby+Soother). Accessed January 10, 2017.
4. Surgeon-orthopedic hourly wages. Salary.com website. <http://www1.salary.com/orthopedic-surgeon-hourly-wages.html>. Updated January 2017. Accessed January 10, 2017.

# Taking an Orthopaedic Sabbatical: *Mon Année en Lyon*

Daniel C. Wascher, MD

Department of Orthopaedics & Rehabilitation, The University of New Mexico Health Sciences Center, Albuquerque, New Mexico

From June 2015 until May 2016, I undertook an orthopaedic sabbatical in Lyon, France. It was one of the most fulfilling experiences of my professional career. Although sabbatical leave is frequently used by faculty on main campus, sabbaticals are not commonly undertaken by medical-school faculty and are even rarer amongst orthopaedic surgeons. In my 26 years at The University of New Mexico (UNM), I know of only two orthopaedic faculty members who undertook sabbaticals: Moheb Moneim and Thomas DeCoster.

The concept of a sabbatical originated in biblical times.<sup>1,2</sup> The early Israelites recognized that trying to get their fields to yield year after year would deplete the land of resources, and their production would decrease. In the late 1800s, leaders at American universities understood the value of having faculty take periodic leave. The first definite system of sabbatical leave was established in 1880 at Harvard University. By 1920, a total of 50 universities had sabbatical leave plans in place; today, most American universities have some form of sabbatical available for faculty.<sup>3</sup> Carter Good's *Dictionary of Education*<sup>4</sup> defines a sabbatical as "a plan for providing teachers with an opportunity for self-improvement through a leave of absence with full or partial compensation following a designated number of years of consecutive service." The critical elements of a sabbatical are as follows: a defined purpose or goal, compensation during the leave, and a definite period of prior service in the institution (typically 6 years). At UNM, sabbatical leave is available to all tenured faculty members with approval from the department chairperson and dean.<sup>5</sup>

For my sabbatical, I spent 1 year in Lyon, France, working with Professor Philippe Neyret at L'Hôpital de la Croix Rousse (Figure 1). Professor Neyret was schooled in the Lyon School of Knee Surgery and is recognized worldwide as an expert in knee surgery (Figure 2). He is the chief of the Centre Albert Trillat where his faculty includes Professors Elvire Servien and Sébastien Lustig. I desired to learn novel advanced knee surgical techniques and participate in research projects related to knee pathology and treatment.



Figure 1. L'Hôpital de la Croix Rousse, Lyon, France, where the Centre Albert Trillat is located.



Figure 2. Professor Philippe Neyret and I attending the meeting of the European Society of Sports Traumatology, Knee Surgery and Arthroscopy in Barcelona, Spain.

There are many advantages to the faculty member undertaking a sabbatical. These benefits have been reviewed by Sima.<sup>6</sup> For me, the sabbatical was intellectually and personally stimulating. The French surgeons I worked with had different ideas on the diagnosis and treatment of knee conditions. These physicians challenged my long-standing opinions and showed me new techniques that I have adopted in my current practice. I am performing more osteotomies for treating arthritis and extra-articular reconstructions for revision procedures in treating anterior

cruciate ligament injuries; I recently performed my first trochleoplasty.

During my sabbatical, I also participated in many research projects. To date, this collaboration has resulted in seven publications. The personal connections I made were even more important. I became great friends with Professor Neyret during our frequent discussions over morning *café* or afternoon *déjeuner*. I also developed relationships with the rest of the Croix-Rousse faculty. I visited Nicolas Gravelau and Philippe Colombet in Bordeaux and chatted with Professor Pedro Guillen in Madrid (Figure 3). During a visit to Budapest, a former UNM sports-medicine fellow, Tamas Bardos, provided us with a wonderful tour.



Figure 3. Nicolas Gravelau and I in the operating theater in Mérignac, near Bordeaux.

Personally, the sabbatical year allowed time for relaxation and reflection that is often lacking in our busy life as an academic orthopaedic surgeon. We spent the weekends exploring the many regions of France and enjoyed amazing sights, food, and wine (Figure 4). I had time to think about what the priorities should be in my work and family life. The French physicians worked hard but truly knew how to enjoy many things that we ignore, including a leisurely stroll along the Rhone or lingering over a *digestif* after a meal. Sabbaticals are great at preventing physician “burn-out.”



Figure 4. Professor Neyret, waiter, Carlotta Emslie, Isabelle Neyret, and I enjoying dinner at Brasserie Georges in Lyon, France.

As rewarding as the sabbatical year was, it is important to remember that sabbaticals were “established not in the interests of the professors themselves, but for the good of university education”<sup>3</sup> Zahorski outlined the advantages of having a sabbatical program to the institution.<sup>6</sup> Certainly, I believe that my sabbatical will have great benefits to UNM Orthopaedics. The quality of UNM Orthopaedics is now known in Europe. Professor Neyret committed to visiting Albuquerque to give a series of lectures in the next year. Several residents have already expressed interest in spending their fourth-year elective in Lyon, and they will be warmly welcomed. I also hope to expand the research collaboration between Lyon and Albuquerque. Most important, the knowledge and skills I learned in Lyon are now being taught to the residents and fellows in Albuquerque.

When I discuss the fantastic experience of my sabbatical with other orthopaedic surgeons, they often counter with reasons why they would not undertake a sabbatical. The four main reasons given are: 1) the financial cost; 2) the loss of surgical skills; 3) the negative impact on their practice; and 4) the disruption to family life. I would argue that the benefits of a sabbatical far outweigh any negatives. Sabbaticals should not be limited just to academic orthopaedic surgeons. With proper planning, even a private-practice orthopaedist can afford to take a sabbatical. One study reported that, of 70 medical-school faculty members who undertook a sabbatical, a total of 80% rated the experience as equal to or greater than eight points (of 10 points).<sup>7</sup> A total of 75% reported that the sabbatical resulted in substantial academic achievement. Personally, I would rate my sabbatical a “perfect 10.”

For those contemplating taking a sabbatical, I have several suggestions for making it a resounding success. First, planning a sabbatical is key. It is critically important to find a person or an institution that will be intellectually challenging, allow for professional collaboration, and most importantly, that will be welcoming. Professor Neyret and the faculty at the Centre Albert Trillat were gracious hosts who freely shared their knowledge and welcomed my input on clinical situations and research projects. It is also never too early to start arrangements for licensure, housing, and transportation. My second piece of advice to step out of your “comfort zone.” Do not be intimidated by a foreign country, language difficulties, or different ways of approaching orthopaedic problems. Embrace the challenges, and you will grow both professionally and personally. Finally, I would suggest that a 6-month sabbatical is too short a time, particularly if one is going to spend it in another country. It took 4 months to get used to living in France and about that long for the surgeons in Lyon to trust my opinions and surgical skills. The second

6 months were much more enjoyable and productive than the first 6 months. All in all, the year passed much too quickly.

In summary, a sabbatical is one of the great benefits of an academic orthopaedic career, but one that too many surgeons fail to pursue. Time away from one's home institution reduces "burn out," challenges established beliefs, and results in numerous opportunities for professional growth. I would highly recommend that all orthopaedic surgeons—in both academics and private practice—explore taking a sabbatical during their career. If your sabbatical is half as good as mine, it will be an amazing experience (Figure 5).



Figure 5. Carlotta and I visiting Paris, France.

## Acknowledgments

Many thanks to Bob Schenck who strongly encouraged and supported my sabbatical. Also thanks to Andy Veitch, Gehron Treme, Eric Benson, Chris Hanosh, and Dustin Briggs who provided great care to my patients in my absence and absorbed my teaching and administrative loads. Finally, *merci beaucoup* to Philippe Neyret, Elvire Servien, and Sebastien Lustig who welcomed me with open arms and freely shared their knowledge and skills with me. I couldn't imagine more gracious hosts.

## References

1. Kimball BA. The origin of the Sabbath and its legacy to the modern sabbatical. *J Higher Educ* 1978;49(44):303-15. doi: 10.2307/1979188.
2. Leviticus 25: 1-4 RSV.
3. Eells W. The origin and early history of sabbatical leave. *AAUP Bull* 1962;48(3):253-6. doi:10.2307/40222893.
4. Good C, ed. *Dictionary of Education*. 3rd ed. New York, NY: McGraw-Hill, 1959.
5. The University of New Mexico. *UNM Faculty Handbook*. <http://handbook.unm.edu/pdf/unm-faculty-handbook.pdf>. Updated February 16, 2017. Accessed March 10, 2017.
6. Sima CM. The role and benefits of the sabbatical leave in faculty development and satisfaction. *New Dir Inst Res* 2000;(105):67-75. doi: 10.1002/ir.10506.
7. Jarecky RK, Sandifer MG. Faculty members' evaluation of sabbaticals. *J Med Educ* 1986;61(10):803-7.









UNM

SCHOOL OF MEDICINE

*Department of Orthopaedics & Rehabilitation*